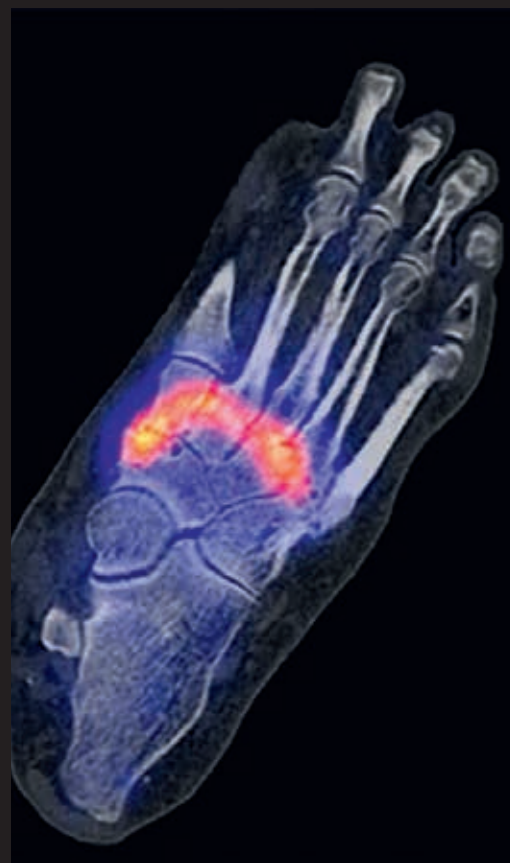
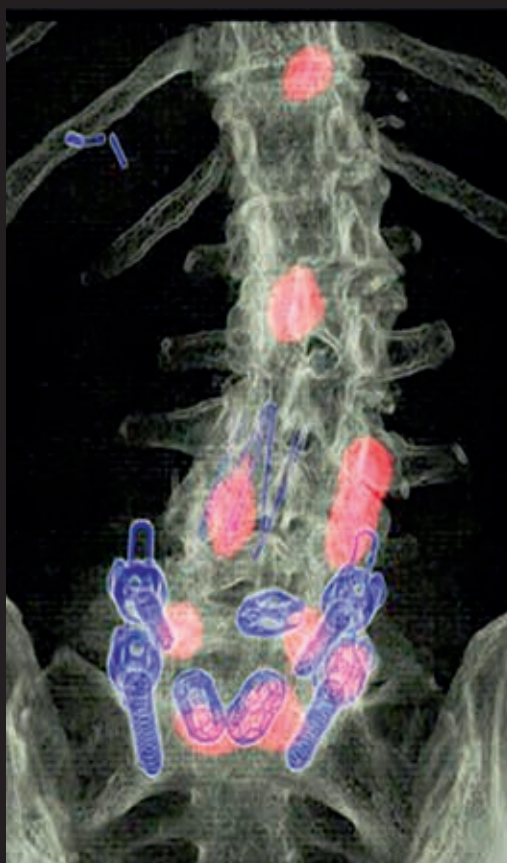
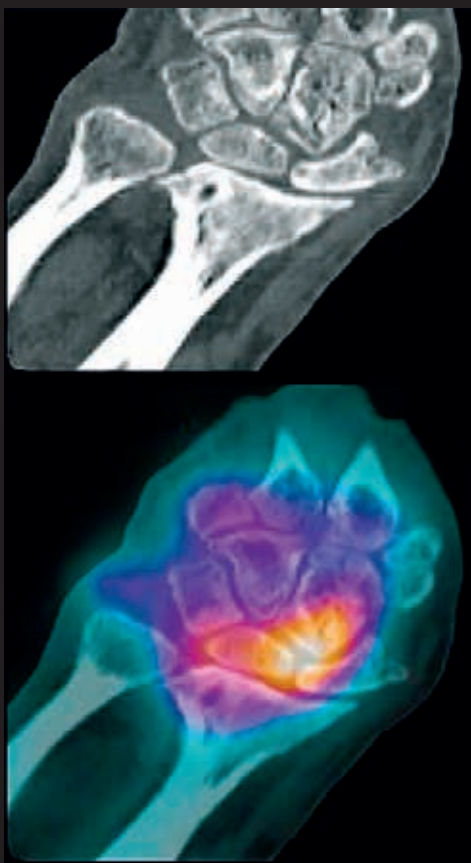IAEA HUMAN HEALTH SERIES

No. 34

Atlas of Skeletal SPECT/CT Clinical Images



IAEA

International Atomic Energy Agency

IAEA HUMAN HEALTH SERIES PUBLICATIONS

The mandate of the IAEA human health programme originates from Article II of its Statute, which states that the “Agency shall seek to accelerate and enlarge the contribution of atomic energy to peace, health and prosperity throughout the world”. The main objective of the human health programme is to enhance the capabilities of IAEA Member States in addressing issues related to the prevention, diagnosis and treatment of health problems through the development and application of nuclear techniques, within a framework of quality assurance.

Publications in the IAEA Human Health Series provide information in the areas of: radiation medicine, including diagnostic radiology, diagnostic and therapeutic nuclear medicine, and radiation therapy; dosimetry and medical radiation physics; and stable isotope techniques and other nuclear applications in nutrition. The publications have a broad readership and are aimed at medical practitioners, researchers and other professionals. International experts assist the IAEA Secretariat in drafting and reviewing these publications. Some of the publications in this series may also be endorsed or co-sponsored by international organizations and professional societies active in the relevant fields.

There are two categories of publications in this series:

IAEA HUMAN HEALTH SERIES

Publications in this category present analyses or provide information of an advisory nature, for example guidelines, codes and standards of practice, and quality assurance manuals. Monographs and high level educational material, such as graduate texts, are also published in this series.

IAEA HUMAN HEALTH REPORTS

Human Health Reports complement information published in the IAEA Human Health Series in areas of radiation medicine, dosimetry and medical radiation physics, and nutrition. These publications include reports of technical meetings, the results of IAEA coordinated research projects, interim reports on IAEA projects, and educational material compiled for IAEA training courses dealing with human health related subjects. In some cases, these reports may provide supporting material relating to publications issued in the IAEA Human Health Series.

All of these publications can be downloaded cost free from the IAEA web site:

<http://www.iaea.org/Publications/index.html>

Further information is available from:

Marketing and Sales Unit
International Atomic Energy Agency
Vienna International Centre
PO Box 100
1400 Vienna, Austria

Readers are invited to provide their impressions on these publications. Information may be provided via the IAEA web site, by mail at the address given above, or by email to:

Official.Mail@iaea.org.

ATLAS OF SKELETAL SPECT/CT
CLINICAL IMAGES

The following States are Members of the International Atomic Energy Agency:

AFGHANISTAN	GEORGIA	OMAN
ALBANIA	GERMANY	PAKISTAN
ALGERIA	GHANA	PALAU
ANGOLA	GREECE	PANAMA
ANTIGUA AND BARBUDA	GUATEMALA	PAPUA NEW GUINEA
ARGENTINA	GUYANA	PARAGUAY
ARMENIA	HAITI	PERU
AUSTRALIA	HOLY SEE	PHILIPPINES
AUSTRIA	HONDURAS	POLAND
AZERBAIJAN	HUNGARY	PORTUGAL
BAHAMAS	ICELAND	QATAR
BAHRAIN	INDIA	REPUBLIC OF MOLDOVA
BANGLADESH	INDONESIA	ROMANIA
BARBADOS	IRAN, ISLAMIC REPUBLIC OF	RUSSIAN FEDERATION
BELARUS	IRAQ	RWANDA
BELGIUM	IRELAND	SAN MARINO
BELIZE	ISRAEL	SAUDI ARABIA
BENIN	ITALY	SENEGAL
BOLIVIA, PLURINATIONAL STATE OF	JAMAICA	SERBIA
BOSNIA AND HERZEGOVINA	JAPAN	SEYCHELLES
BOTSWANA	JORDAN	SIERRA LEONE
BRAZIL	KAZAKHSTAN	SINGAPORE
BRUNEI DARUSSALAM	KENYA	SLOVAKIA
BULGARIA	KOREA, REPUBLIC OF	SLOVENIA
BURKINA FASO	KUWAIT	SOUTH AFRICA
BURUNDI	KYRGYZSTAN	SPAIN
CAMBODIA	LAO PEOPLE'S DEMOCRATIC REPUBLIC	SRI LANKA
CAMEROON	LATVIA	SUDAN
CANADA	LEBANON	SWAZILAND
CENTRAL AFRICAN REPUBLIC	LESOTHO	SWEDEN
CHAD	LIBERIA	SWITZERLAND
CHILE	LIBYA	SYRIAN ARAB REPUBLIC
CHINA	LIECHTENSTEIN	TAJIKISTAN
COLOMBIA	LITHUANIA	THAILAND
CONGO	LUXEMBOURG	THE FORMER YUGOSLAV REPUBLIC OF MACEDONIA
COSTA RICA	MADAGASCAR	TOGO
CÔTE D'IVOIRE	MALAWI	TRINIDAD AND TOBAGO
CROATIA	MALAYSIA	TUNISIA
CUBA	MALI	TURKEY
CYPRUS	MALTA	TURKMENISTAN
CZECH REPUBLIC	MARSHALL ISLANDS	UGANDA
DEMOCRATIC REPUBLIC OF THE CONGO	MAURITANIA	UKRAINE
DENMARK	MAURITIUS	UNITED ARAB EMIRATES
DJIBOUTI	MEXICO	UNITED KINGDOM OF GREAT BRITAIN AND NORTHERN IRELAND
DOMINICA	MONACO	UNITED REPUBLIC OF TANZANIA
DOMINICAN REPUBLIC	MONGOLIA	UNITED STATES OF AMERICA
ECUADOR	MONTENEGRO	URUGUAY
EGYPT	MOROCCO	UZBEKISTAN
EL SALVADOR	MOZAMBIQUE	VANUATU
ERITREA	MYANMAR	VENEZUELA, BOLIVARIAN REPUBLIC OF
ESTONIA	NAMIBIA	VIET NAM
ETHIOPIA	NEPAL	YEMEN
FIJI	NETHERLANDS	ZAMBIA
FINLAND	NEW ZEALAND	ZIMBABWE
FRANCE	NICARAGUA	
GABON	NIGER	
	NIGERIA	
	NORWAY	

The Agency's Statute was approved on 23 October 1956 by the Conference on the Statute of the IAEA held at United Nations Headquarters, New York; it entered into force on 29 July 1957. The Headquarters of the Agency are situated in Vienna. Its principal objective is "to accelerate and enlarge the contribution of atomic energy to peace, health and prosperity throughout the world".

IAEA HUMAN HEALTH SERIES No. 34

ATLAS OF SKELETAL SPECT/CT CLINICAL IMAGES

INTERNATIONAL ATOMIC ENERGY AGENCY
VIENNA, 2016

COPYRIGHT NOTICE

All IAEA scientific and technical publications are protected by the terms of the Universal Copyright Convention as adopted in 1952 (Berne) and as revised in 1972 (Paris). The copyright has since been extended by the World Intellectual Property Organization (Geneva) to include electronic and virtual intellectual property. Permission to use whole or parts of texts contained in IAEA publications in printed or electronic form must be obtained and is usually subject to royalty agreements. Proposals for non-commercial reproductions and translations are welcomed and considered on a case-by-case basis. Enquiries should be addressed to the IAEA Publishing Section at:

Marketing and Sales Unit, Publishing Section
International Atomic Energy Agency
Vienna International Centre
PO Box 100
1400 Vienna, Austria
fax: +43 1 2600 29302
tel.: +43 1 2600 22417
email: sales.publications@iaea.org
<http://www.iaea.org/books>

© IAEA, 2016

Printed by the IAEA in Austria

August 2016

STI/PUB/1748

IAEA Library Cataloguing in Publication Data

Names: International Atomic Energy Agency.

Title: Atlas of skeletal SPECT/CT clinical images / International Atomic Energy Agency.

Description: Vienna : International Atomic Energy Agency, 2016. | Series: IAEA human health series, ISSN 2075-3772 ; no. 34 | Includes bibliographical references.

Identifiers: IAEAL 16-01055 | ISBN 978-92-0-103416-8 (paperback : alk. paper)

Subjects: LCSH: Nuclear medicine. | Diagnostic imaging — Atlases. | Tomography — Atlases. | Single-photon emission computed tomography.

Classification: UDC 616-073 | STI/PUB/1748

FOREWORD

Integrated single photon emission computed tomography (SPECT)/computed tomography (CT) has evolved into one of the most utilized instruments in hybrid imaging since its introduction in the late 1990s — first into academic and later into commercial medical environments. It has not only facilitated true hybrid imaging with anatomical localization of areas of increased uptake, but it has also led ultimately to the introduction of quantitative SPECT and much wider acceptance in a variety of clinical indications.

SPECT/CT has demonstrated a significant impact and improvement for patient management, therapy decisions and patient outcomes, for example for oncologic diseases, cardiac and musculoskeletal conditions, among others. Although there is academic proof of these benefits, there was initial clinical scepticism from both the radiological and nuclear medicine fields concerning the combination of two complementary imaging modalities. However, it is now widely accepted that combining the advantages of both radiology and nuclear medicine leads to an improved diagnosis and better outcome. Currently, there are several different types and concepts of SPECT/CT systems available commercially for human use. The variety of configuration ranges from SPECT systems combined with CT, which varies from lower end to multi-slice CT systems, including iterative image reconstruction and advanced data processing. Musculoskeletal conditions are one of the leading causes for early retirement in western industrialized countries and lead to a large percentage of imaging conducted in these countries, especially magnetic resonance imaging (MRI). Nevertheless, the role of these imaging techniques (e.g. MRI) on outcomes is currently unclear, since several studies have shown no direct correlation with the clinical symptoms.

There is great interest in imaging that can provide support regarding the decision making process for referring physicians in order to improve patient management and care. To that extent, hybrid imaging, especially SPECT/CT in musculoskeletal imaging, has experienced tremendous developments, improvements and a positive impact in recent years.

Although procedural guidelines for clinical and research studies employing SPECT/CT have been proposed, an international survey among clinical SPECT/CT users revealed that the examination of the skeleton (bone scintigraphy) was the most frequent organ specific primary indication for SPECT/CT. In many institutions, however, it is not yet a routine component of nuclear medicine procedures. Moreover, it appears that a significant number of centres do not utilize the full diagnostic potential of the CT component. Close collaboration between nuclear medicine physicians and radiologists would be very beneficial.

This atlas is intended to serve as a training tool to further integrate the SPECT and CT experience in clinical practice by presenting a series of typical cases with many different patterns of SPECT/CT seen in bone scintigraphy. Undoubtedly, it will facilitate increased knowledge and better understanding of the correct interpretation of SPECT/CT studies for a challenging and yet rewarding organ, the skeleton.

The IAEA wishes to thank the contributors to the drafting and review of this book for contributing their knowledge, time and effort. The technical officers responsible for this publication were R. Nuñez Miller and D. Paez of the Division of Human Health.

EDITORIAL NOTE

This publication has been edited by the editorial staff of the IAEA to the extent considered necessary for the reader's assistance. It does not address questions of responsibility, legal or otherwise, for acts or omissions on the part of any person.

Although great care has been taken to maintain the accuracy of information contained in this publication, neither the IAEA nor its Member States assume any responsibility for consequences which may arise from its use.

The use of particular designations of countries or territories does not imply any judgement by the publisher, the IAEA, as to the legal status of such countries or territories, of their authorities and institutions or of the delimitation of their boundaries.

The mention of names of specific companies or products (whether or not indicated as registered) does not imply any intention to infringe proprietary rights, nor should it be construed as an endorsement or recommendation on the part of the IAEA.

The IAEA has no responsibility for the persistence or accuracy of URLs for external or third party Internet web sites referred to in this publication and does not guarantee that any content on such web sites is, or will remain, accurate or appropriate.

CONTENTS

1.	INTRODUCTION	1
1.1.	Background	1
1.2.	Scope	1
1.3.	Objective	2
1.4.	Structure	2
2.	CERVICAL SPINE	4
2.1.	Case No. CS 1	4
2.2.	Case No. CS 2	6
2.3.	Case No. CS 3	8
2.4.	Case No. CS 4	10
2.5.	Case No. CS 5	12
2.6.	Case No. CS 6	14
2.7.	Case No. CS 7	16
2.8.	Case No. CS 8	18
2.9.	Case No. CS 9	20
3.	THORACIC SPINE	22
3.1.	Case No. TS 1	22
3.2.	Case No. TS 2	24
3.3.	Case No. TS 3	26
3.4.	Case No. TS 4	28
3.5.	Case No. TS 5	30
3.6.	Case No. TS 6	32
3.7.	Case No. TS 7	34
3.8.	Case No. TS 8	36
3.9.	Case No. TS 9	38
4.	LUMBAR SPINE	40
4.1.	Case No. LS 1	40
4.2.	Case No. LS 2	42
4.3.	Case No. LS 3	44
4.4.	Case No. LS 4	46
4.5.	Case No. LS 5	48
4.6.	Case No. LS 6	50
4.7.	Case No. LS 7	52
4.8.	Case No. LS 8	54
4.9.	Case No. LS 9	56
4.10.	Case No. LS 10	58
5.	PELVIS AND HIP	60
5.1.	Case No. PH 1	60
5.2.	Case No. PH 2	62
5.3.	Case No. PH 3	64
5.4.	Case No. PH 4	66

5.5.	Case No. PH 5	68
5.6.	Case No. PH 6	70
5.7.	Case No. PH 7	72
5.8.	Case No. PH 8	74
5.9.	Case No. PH 9	76
5.10.	Case No. PH 10	78
5.11.	Case No. PH 11	80
5.12.	Case No. PH 12	82
5.13.	Case No. PH 13	84
5.14.	Case No. PH 14	86
5.15.	Case No. PH 15	88
6.	SHOULDER AND ELBOW	90
6.1.	Case No. SE 1	90
6.2.	Case No. SE 2	92
6.3.	Case No. SE 3	94
6.4.	Case No. SE 4	96
6.5.	Case No. SE 5	98
6.6.	Case No. SE 6	100
6.7.	Case No. SE 7	102
7.	HAND AND WRIST	104
7.1.	Case No. HW 1	104
7.2.	Case No. HW 2	106
7.3.	Case No. HW 3	108
7.4.	Case No. HW 4	110
7.5.	Case No. HW 5	112
7.6.	Case No. HW 6	114
7.7.	Case No. HW 7	116
7.8.	Case No. HW 8	118
7.9.	Case No. HW 9	120
7.10.	Case No. HW 10	122
7.11.	Case No. HW 11	124
7.12.	Case No. HW 12	126
8.	KNEE	128
8.1.	Case No. K 1	128
8.2.	Case No. K 2	130
8.3.	Case No. K 3	132
8.4.	Case No. K 4	134
8.5.	Case No. K 5	136
8.6.	Case No. K 6	138
8.7.	Case No. K 7	140
8.8.	Case No. K 8	142
8.9.	Case No. K 9	144
8.10.	Case No. K 10	146
8.11.	Case No. K 11	148
8.12.	Case No. K 12	150
8.13.	Case No. K 13	152
8.14.	Case No. K 14	154

8.15.	Case No. K 15	156
8.16.	Case No. K 16	158
9.	FEET	160
9.1.	Case No. F 1	160
9.2.	Case No. F 2	162
9.3.	Case No. F 3	164
9.4.	Case No. F 4	166
9.5.	Case No. F 5	168
9.6.	Case No. F 6	170
9.7.	Case No. F 7	172
9.8.	Case No. F 8	174
9.9.	Case No. F 9	176
9.10.	Case No. F 10	178
9.11.	Case No. F 11	180
9.12.	Case No. F 12	182
9.13.	Case No. F 13	184
9.14.	Case No. F 14	186
9.15.	Case No. F 15	188
9.16.	Case No. F 16	190
9.17.	Case No. F 17	192
10.	METASTATIC DISEASE	194
10.1.	Case No. MD 1	194
10.2.	Case No. MD 2	196
10.3.	Case No. MD 3	198
10.4.	Case No. MD 4	200
10.5.	Case No. MD 5	202
10.6.	Case No. MD 6	204
10.7.	Case No. MD 7	206
10.8.	Case No. MD 8	208
10.9.	Case No. MD 9	210
10.10.	Case No. MD 10	212
11.	PAEDIATRICS	214
11.1.	Case No. PAED 1	214
11.2.	Case No. PAED 2	216
11.3.	Case No. PAED 3	218
11.4.	Case No. PAED 4	220
11.5.	Case No. PAED 5	222
11.6.	Case No. PAED 6	224
11.7.	Case No. PAED 7	226
11.8.	Case No. PAED 8	228
11.9.	Case No. PAED 9	230
11.10.	Case No. PAED 10	232
ABBREVIATIONS		235
CONTRIBUTORS TO DRAFTING AND REVIEW		237

1. INTRODUCTION

1.1. BACKGROUND

Nuclear medicine techniques create images of functional processes by using radioactive tracers and photon detectors. Tomographic imaging with radionuclides began in the early 1960s and predates computed tomography (CT). Single photon emission computed tomography (SPECT) is a mainstay in nuclear medicine and has been used in routine diagnostic applications and research since the 1980s. In 1996, Blankespoor et al. [1.1] presented a combined SPECT/CT design, which comprised of a clinical SPECT gamma camera in tandem with a clinical single slice CT. Since then, SPECT/CT has advanced rapidly, and several commercial systems are available today employing various designs of CT systems and dual head SPECT configurations.

There are numerous advantages of an integrated, functional and morphological imaging device:

- (a) A single examination can provide comprehensive functional and anatomical information on the state of a disease.
- (b) Patients can be scheduled for only one instead of two or multiple examinations.
- (c) Experts in radiology and nuclear medicine can review the complementary image sets together and integrate their interpretation into a single report.

As a result, an increasing number of SPECT/CT systems are being installed by Member States, thus making capacity building in SPECT/CT a learning priority for many nuclear medicine and imaging departments, particularly States which are embarking on this imaging modality.

Similarly to positron emission tomography (PET)/computed tomography (CT), the ability of SPECT/CT to provide, in a single image session, detailed anatomical, functional and metabolic information — a result of the synergistic effect greater than the sum of information from the two individual techniques — has established SPECT/CT as an indispensable imaging procedure for an increasing number of pathologies. In addition, it has a significant advantage over PET/CT, namely the use of a ubiquitous radiotracer widely available in all nuclear medicine departments: technetium (^{99m}Tc).

1.2. SCOPE

There is a wide range of clinical indications for SPECT/CT imaging, of which the main one is musculoskeletal imaging using biphosphonates as the primary tracer. However, there is still a significant amount of oncology work which can be done with many different tracers, too. In addition, lung imaging — especially for pulmonary embolism, infection imaging as well as neurological indications — represents another significant share of the overall accepted indications for SPECT/CT. However, while the application of SPECT/CT (especially through the addition of the CT component) for pulmonary embolism and evaluation of lung function seems to be increasing again, there has been a decrease in other indications such as oncology. This is mainly due to the use of PET/CT which has an increasing amount of more specific tracers and has a higher resolution from the PET component. Nevertheless, there is a growing body of literature which supports the role of SPECT/CT for musculoskeletal imaging. One of the reasons is that the perception of SPECT/CT from being just plain bone scintigraphy into a truly hybrid imaging modality has changed. The technology has matured, and more data are available to appraise its clinical role. This publication not only emphasizes several different aspects of musculoskeletal imaging in different body compartments, but also shows the new fields in which SPECT/CT is being adopted, partly even in indications where usually MRI would have been preferred.

Examples are given not only for classical indications on pathology of the spine, but also for showing the value of SPECT/CT in providing therapeutically relevant information for the rest of the skeleton. Furthermore, there are also examples where SPECT/CT imaging delivers information for the correct management of chronic diseases as well as newer indications such as the subacute setting in trauma management.

1.3. OBJECTIVE

The IAEA Human Health Series aims to provide information for the Member States on a wide range of topics in general, as well as in medicine and diagnostic imaging specifically. Previous topics in musculoskeletal imaging have already covered the appropriate use of bone scintigraphy in adults and in paediatric patients. Since these issues are especially important in relation to how to use and read standard and planar imaging, this atlas focuses specifically on SPECT/CT in musculoskeletal imaging and thus illustrates the inherent advantages of the combination of the metabolic and anatomical component in a single procedure. In addition, this atlas provides information on the usefulness of several sets of specific indications.

This publication should serve more as a teaching atlas of SPECT/CT in musculoskeletal imaging rather than a textbook. A wide range of over 100 comprehensive cases covering not only the major indications and classical examples of SPECT/CT are presented, as well as more challenging cases where a radiologic and metabolic approach is needed, and relevant, for the correct diagnosis. Furthermore, different tracers used in routine musculoskeletal SPECT/CT imaging are also addressed.

1.4. STRUCTURE

The cases provide an overview of how specific diseases in musculoskeletal imaging appear in SPECT/CT. The cases present the typical pattern of the spread of disease, the possible pitfalls and various teaching points. The structure of this publication is adapted to the anatomical areas of the skeleton: cervical spine, thoracic spine, lumbar spine, pelvis and extremities. Furthermore, there are two extra-anatomical categories: musculoskeletal metastatic disease and paediatric cases.

An additional structure within these categories is given as types of studies and can be found in the **Study type** of each case (Orthopaedics, Traumatology, Oncology, Infection, Rheumatology, Degenerative and Paediatric). In this way, the cases can be found by anatomy and also by different indication, key words and results. The readers will find a short clinical history, imaging descriptions as well as the immediate impact on the clinical course based on the imaging findings.

The IAEA hopes that this SPECT/CT teaching atlas will be of help for the medical professionals and staff working with, as well as people interested in, SPECT/CT imaging in order to embrace the variety of hybrid musculoskeletal imaging. For further information on imaging procedures, see Refs [1.2–1.6].

REFERENCES TO SECTION 1

- [1.1] BLANKESPOOR, S.C., et al., Attenuation correction of SPECT using X-ray CT on an emission-transmission CT system: Myocardial perfusion assessment, IEEE Trans. Nucl. Sci. **43** (1996) 2263–2274.
- [1.2] INTERNATIONAL ATOMIC ENERGY AGENCY, Quality Assurance for PET/CT Systems, IAEA Human Health Series No. 1, IAEA, Vienna (2009).
- [1.3] INTERNATIONAL ATOMIC ENERGY AGENCY, Planning a Clinical PET Centre, IAEA Human Health Series No. 11, IAEA, Vienna (2010).
- [1.4] INTERNATIONAL ATOMIC ENERGY AGENCY, Standard Operating Procedures for PET/CT: A Practical Approach for Use in Adult Oncology, IAEA Human Health Series No. 26, IAEA, Vienna (2013).
- [1.5] INTERNATIONAL ATOMIC ENERGY AGENCY, Quantitative Nuclear Medicine Imaging: Concepts, Requirements and Methods, IAEA Human Health Series No. 9, IAEA, Vienna (2014).
- [1.6] INTERNATIONAL ATOMIC ENERGY AGENCY, Clinical PET/CT Atlas: A Casebook of Imaging Oncology, IAEA Human Health Series No. 32, IAEA, Vienna (2015).

2. CERVICAL SPINE

2.1. CASE No. CS 1

Study type:	Oncology		
Clinical indication:	Staging examination prior to chemotherapy and surgery		
Keywords:	Arthritis Bone metastases		
SPECT/CT system:	General Electric Discovery 670	Tracer:	^{99m}Tc -DPD
Uptake:	180 min	Dose:	683 MBq
Tube loading:	100 mAs	Tube voltage:	120 kVp

Short clinical history

A 58 year old female patient diagnosed with invasive ductal breast cancer. Staging was requested prior to chemotherapy and surgery.

Findings

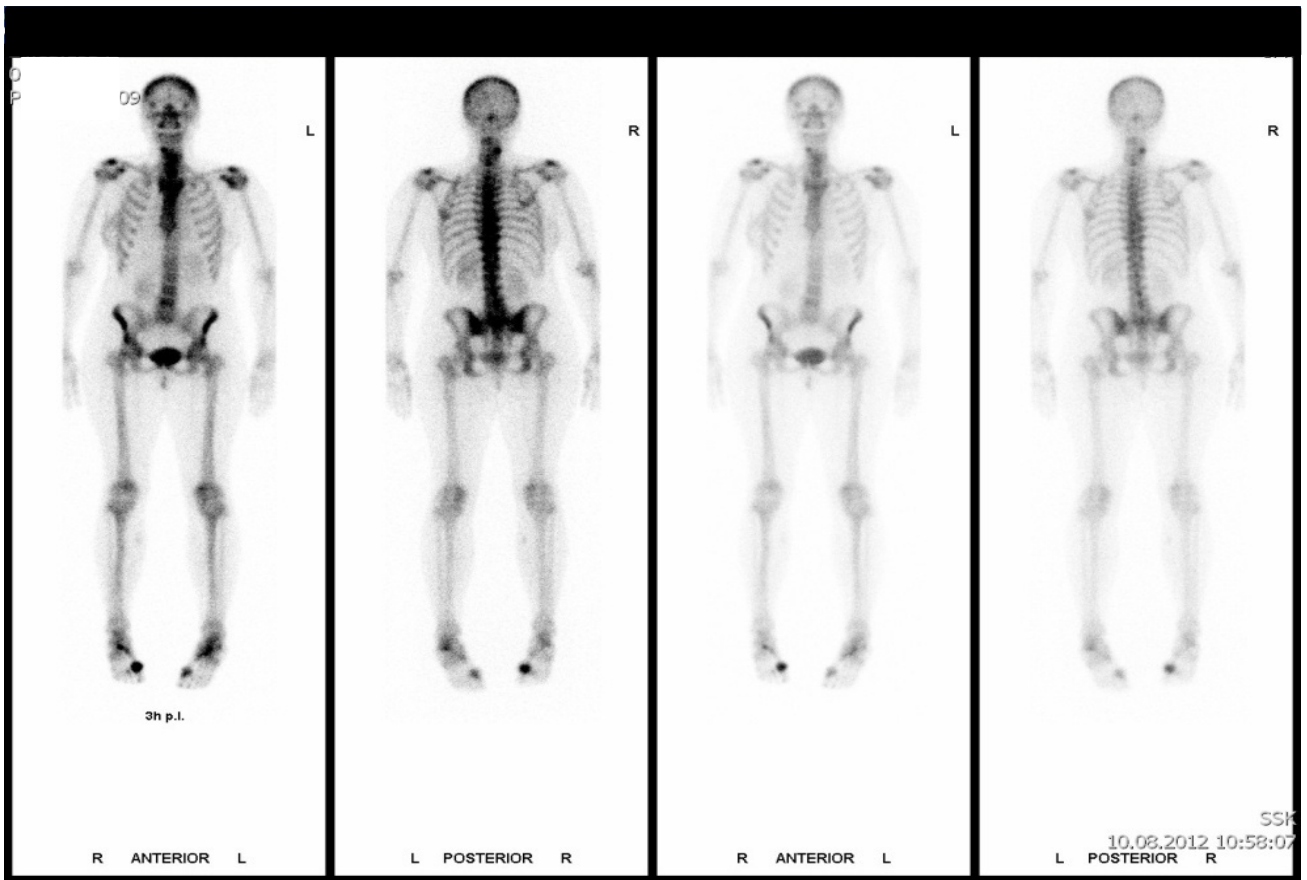
Planar bone scan (A): Shows focal uptake in the right lateral cervical spine. Differential diagnosis facet joint arthritis or bone metastases in the right pedicle.

SPECT/CT (B): Shows degenerative uptake in the right facet joint C4/5 with typical degenerative changes on the corresponding CT (B, arrows, joint space narrowing and irregular cortical bone). No metastatic disease detected within the vertebral body or the right pedicle of C4.

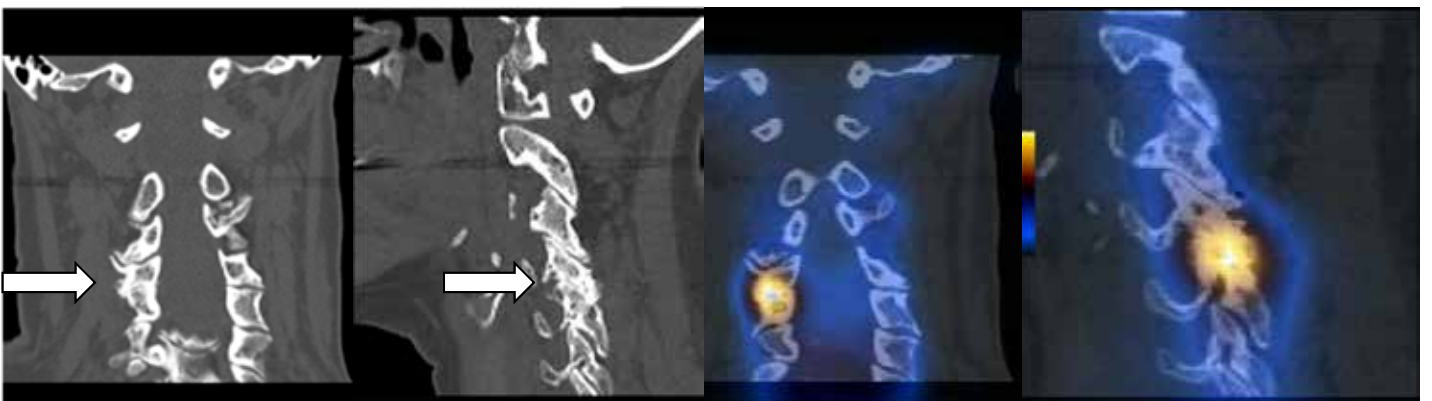
Outcome and teaching point

Metastatic disease was ruled out and treatment started as planned. No further follow-up.

Note the lateral uptake in the cervical spine has the typical appearance for facet joint arthritis.



(A)



(B)

2.2. CASE No. CS 2

Study type:	Degenerative		
Clinical indication:	Fibromyalgia		
Keywords:	Discarthropathy		
SPECT/CT system:	Siemens Symbia T6	Tracer:	^{99m} Tc-DPD
Uptake:	240 min	Dose:	708 MBq
Tube loading:	30 mAs	Tube voltage:	130 kVp

Short clinical history

A 44 year old female patient with a clinical diagnosis of fibromyalgia.

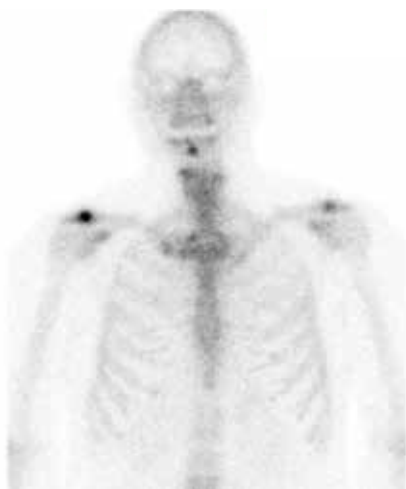Findings

Planar image (A, B): Heterogeneous uptake by the cervical spine, increased uptake in both acromioclavicular joints (R > L).

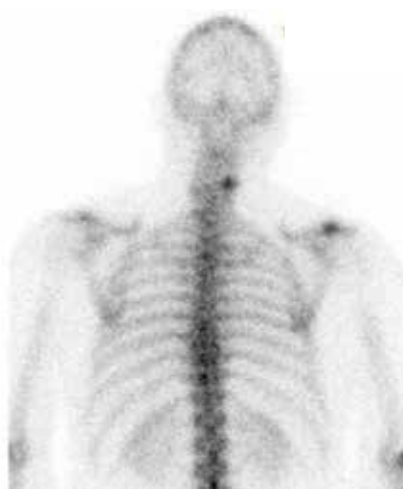SPECT/CT facet joint osteoarthritis C4/5 (C, D), mild degenerative changes in the right acromioclavicular joint (E).

Outcome

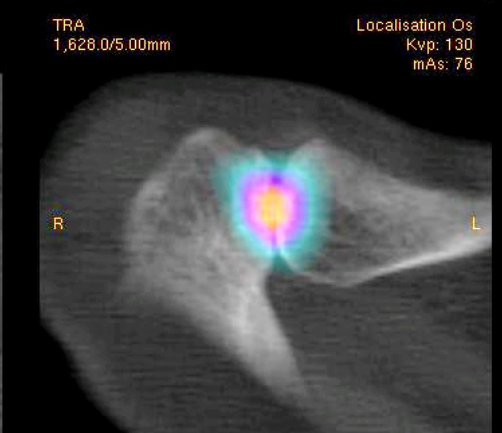
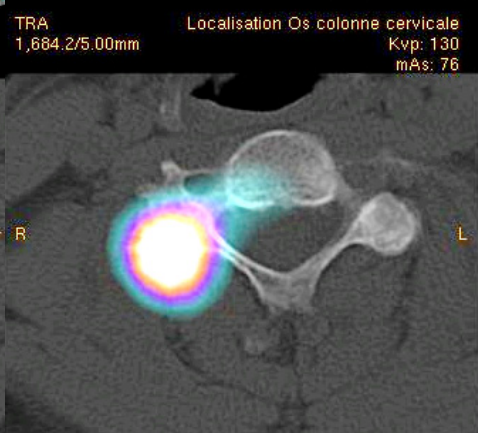
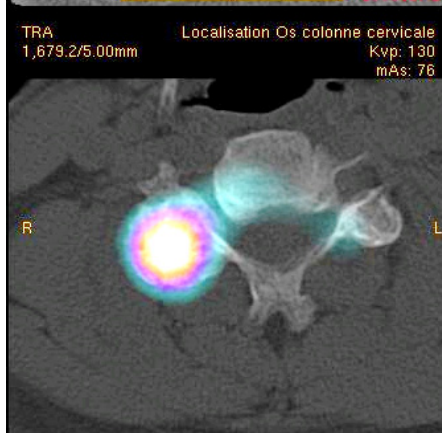
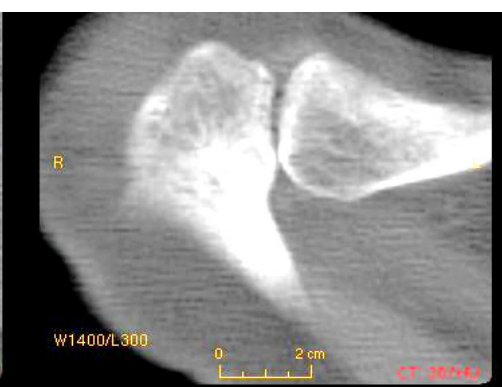
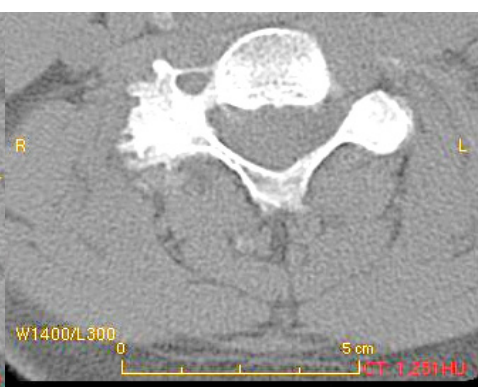
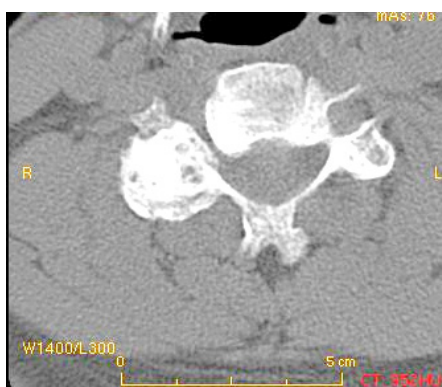
Conservative treatment of the osteoarthritis, which led to improved clinical condition.



(A)



(B)



(C)

(D)

(E)

2.3. CASE No. CS 3

Study type:	Degenerative		
Clinical indication:	Chronic neck pain		
Keywords:	Discarthropathy		
SPECT/CT system:	Siemens Symbia T6	Tracer:	^{99m}Tc -DPD
Uptake:	240 min	Dose:	735 MBq
Tube loading:	104 mAs	Tube voltage:	130 kVp

Short clinical history

A 39 year old female patient with chronic neck pain and irradiation to the left upper extremity. The patient had no history of trauma.

Findings

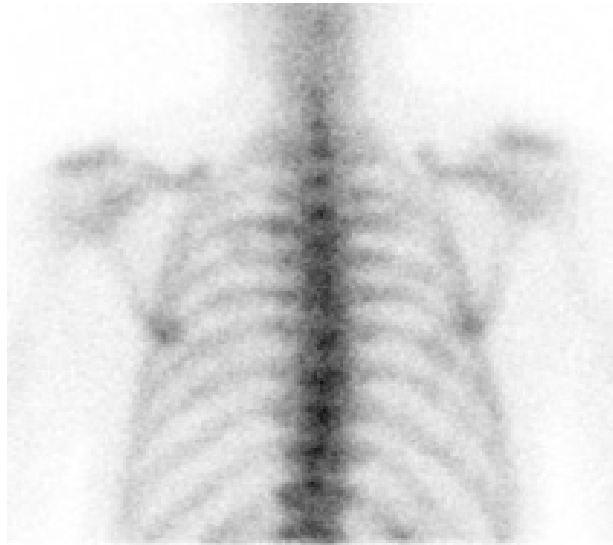Planar images (A): Shows normal uptake.

SPECT/CT (B–D): Shows focus of increased uptake located on the intervertebral disc C5/6 corresponding to slight degenerative changes with anterior spondylophytes on CT.


Outcome and teaching point

Planar images were normal.

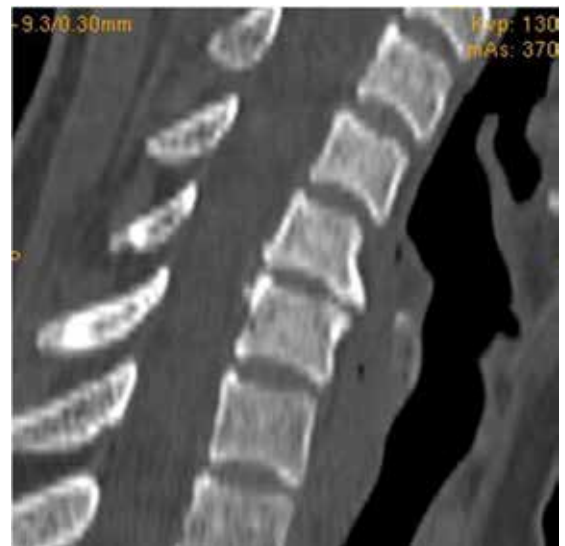Note this case emphasizes the added diagnostic value of SPECT/CT.



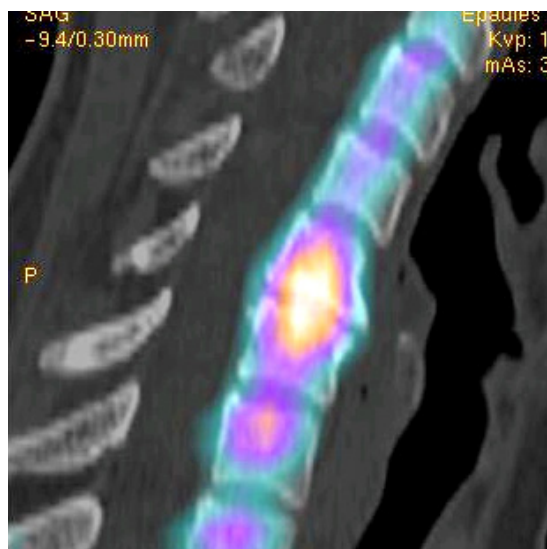
(A)



(B)



(C)



(D)

2.4. CASE No. CS 4

Study type:	Orthopaedics Infection		
Clinical indication:	Osteitis		
Keywords:	Osteitis Bisphosphonates		
SPECT/CT system:	Philips Precedence 16 slice	Tracer:	^{99m}Tc -HDP
Uptake:	120 min	Dose:	670 MBq
Tube loading:	120 mAs	Tube voltage:	130 kVp

Short clinical history

A 75 year old female patient suspected for experiencing bilateral osteitis in the temporal bones, primarily on the right side, due to treatment with bisphosphonates.

Findings

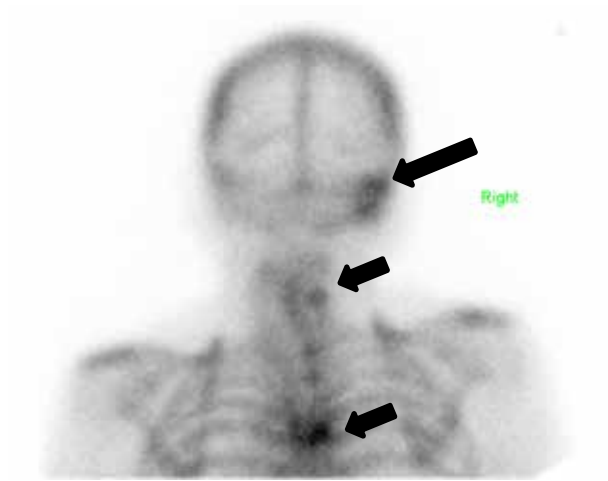
Planar bone scan (A): Shows foci with increased bone metabolism in right temporal bone (large arrow).

Additional findings (small arrows): Increased bone metabolism due to degenerative disease in the C5 facet joint and in the body of T5 likely due to osteoporotic fracture.

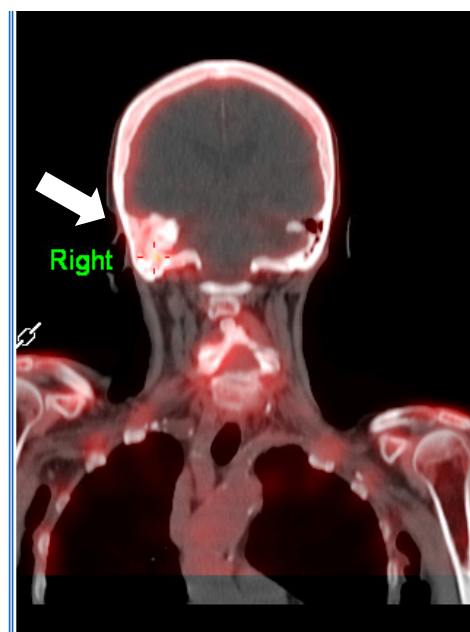
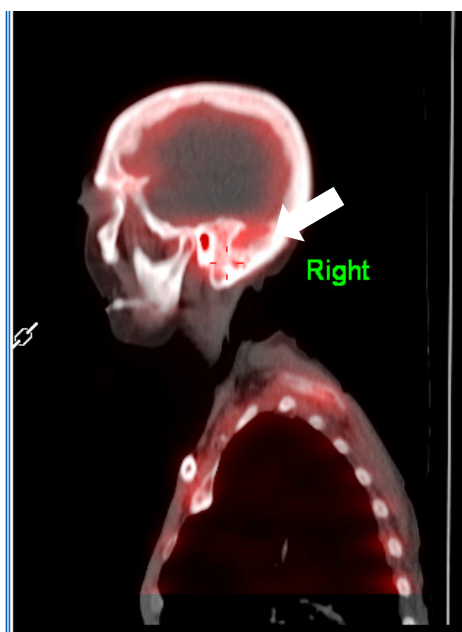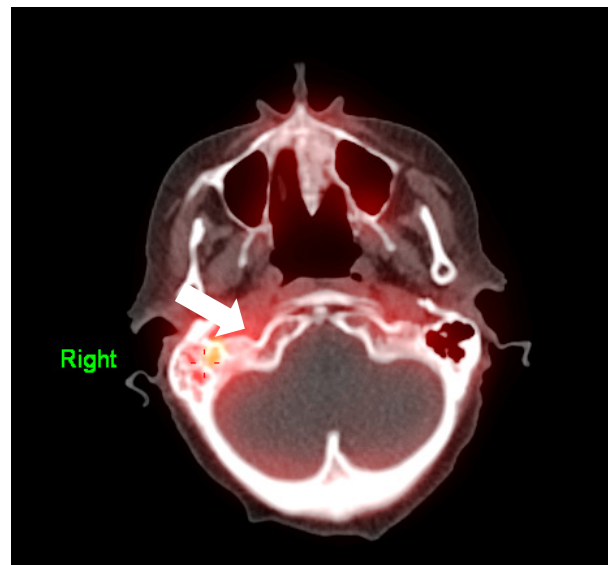
SPECT/CT (B): Shows uptake in the right temporal bone continuing in the mastoid process. CT shows lack of air in right mastoid bone, indicating osteitis.

Outcome

Verification of diagnosis of osteitis in the right temporal bone.



(A)



(B)

2.5. CASE No. CS 5

Study type:	Orthopaedics		
Clinical indication:	Polyarthritis, verification of medical indication to perform radiosynoviorthesis		
Keywords:	Incidental finding Paget's disease		
SPECT/CT system:	Siemens Symbia T2	Tracer:	^{99m}Tc -DPD
Uptake:	150 min	Dose:	522 MBq
Tube loading:	120 mAs	Tube voltage:	80 kVp

Short clinical history

A 71 year old female patient with polyarthritis of multiple finger joints. Bone scintigraphy was performed to verify medical indication for radiosynoviorthesis.

Findings

Whole body scintigraphy (A): Shows osteoarthritis of the TMC joints (short black arrows) and polyarthrosis (spine, left hip).

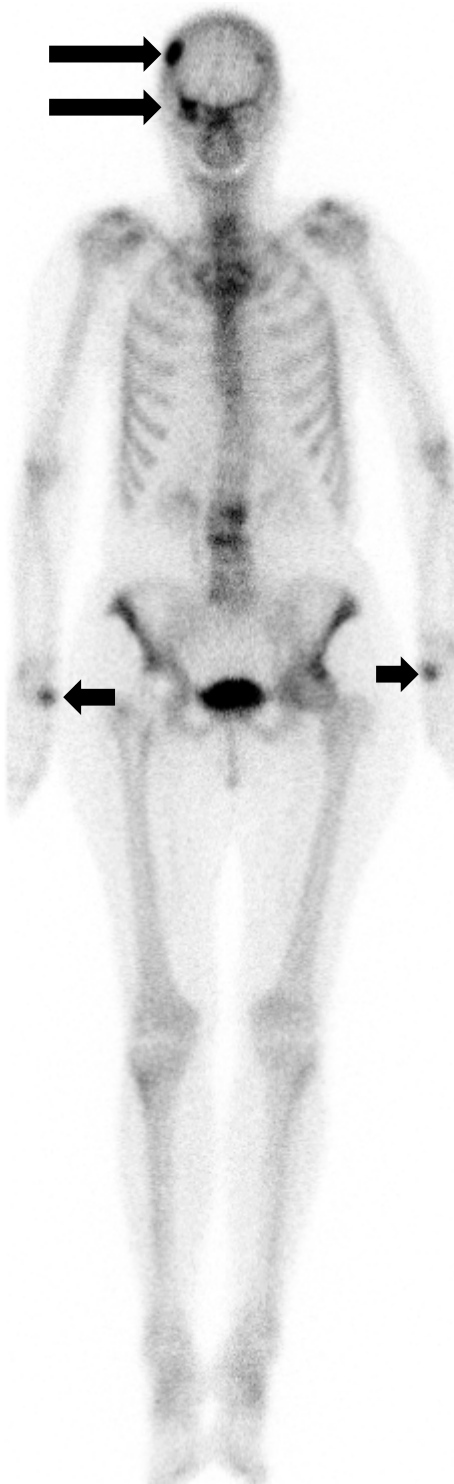As an incidental finding, a focal uptake at the top of the skull was seen (long black arrows).

SPECT/CT (B): Shows increased metabolism that is located in a focal area of decreased trabecular density of the calvarium (white arrow). The finding represents early Paget's disease of the bone.

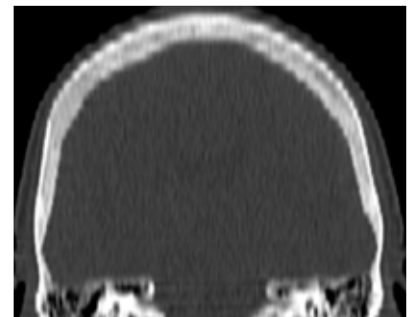
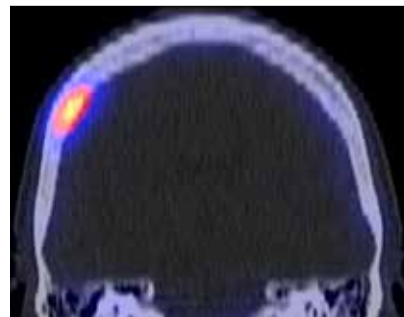
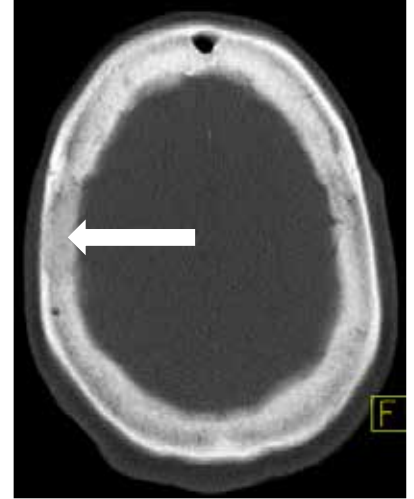
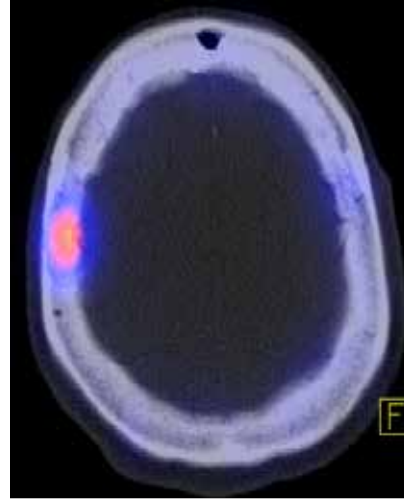
Outcome and teaching point

No treatment of Paget's disease was necessary. Follow-up was recommended.

Note the whole body scan was useful.



(A)



(B)

2.6. CASE No. CS 6

Study type:	Orthopaedics		
Clinical indication:	Back pain		
Keywords:	Incidental finding Apical periodontitis		
SPECT/CT system:	Siemens Symbia T2	Tracer:	^{99m}Tc -DPD
Uptake:	180 min	Dose:	522 MBq
Tube loading:	120 mAs	Tube voltage:	80 kVp

Short clinical history

A 68 year old female patient with a history of back pain for 1 year.

Findings

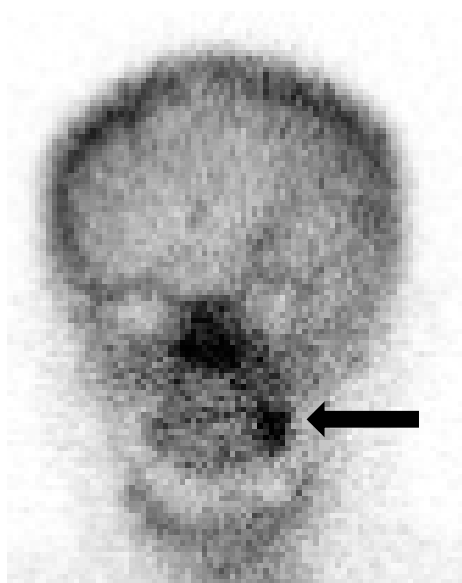
There is no pathologic tracer uptake in the spine or pelvis (not shown).

Incidental finding on the planar image (A): Shows a focal uptake in the maxilla (arrow). In further anamnestic inquiry, the patient reported toothache.

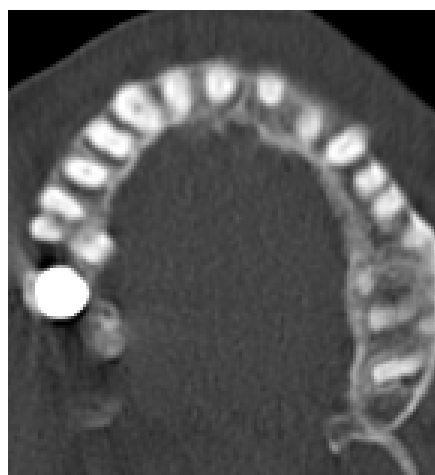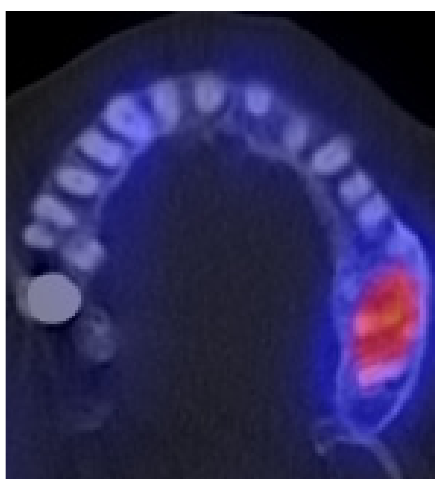
SPECT/CT (B): Shows increased tracer uptake at the root of a molar tooth representing apical periodontitis without breakthrough to the sinus (arrow).

Outcome

The patient was treated with a resection of the root apex.



(A)



(B)

2.7. CASE No. CS 7

Study type:	Orthopaedics		
Clinical indication:	Polyarthritis Lumbar pain		
Keywords:	Incidental finding Sinusitis		
SPECT/CT system:	Siemens Symbia T2	Tracer:	^{99m}Tc -DPD
Uptake:	150 min	Dose:	502 MBq
Tube loading:	120 mAs	Tube voltage:	80 kVp

Short clinical history

A 58 year old female patient with lumbar pain. Bone scintigraphy was performed to rule out or verify osseous genesis.

Furthermore, the patient complained of headaches and facial pain for 1 month with particular increase in pain in the last 2 weeks.

Findings

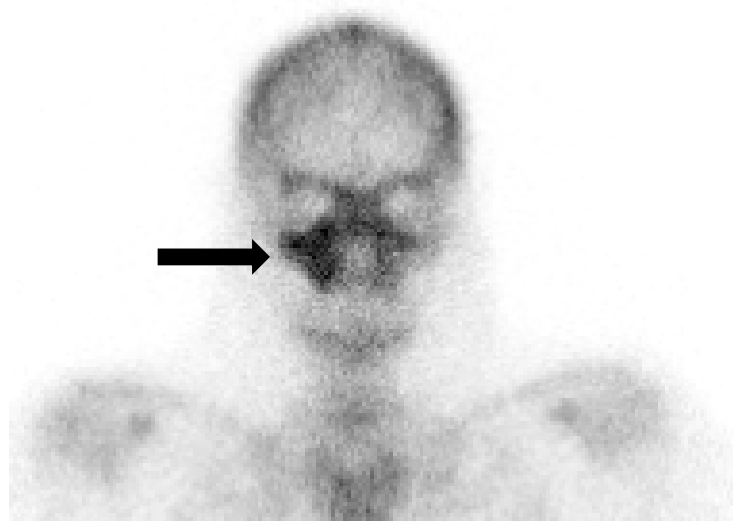
Whole body scintigraphy shows degenerative lumbar changes (not shown).

Incidental finding on the planar image (A): Shows a focal uptake in the right sinuses (arrow).

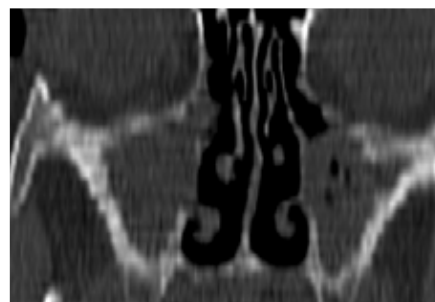
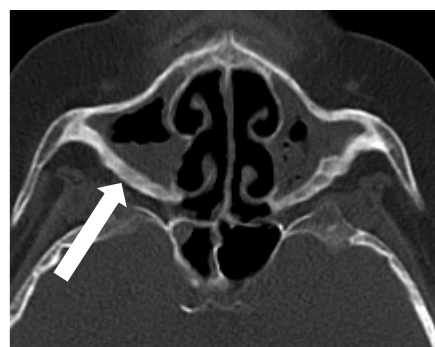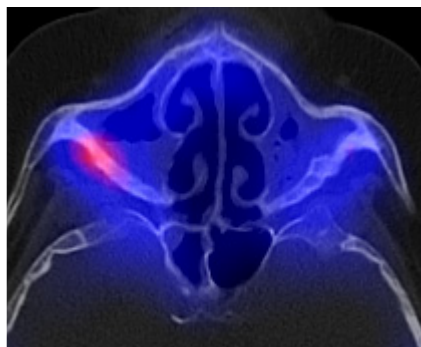
SPECT/CT (B): Shows maxillary sinusitis on both sides with periosteal response (more intense on the right side). The CT shows widening of the posterior wall of the maxillary sinus (arrow) and loosened trabecular structure.

Outcome

The patient was free from complaints after undergoing antibiotic therapy.



(A)



(B)

2.8. CASE No. CS 8

Study type:	Infection		
Clinical indication:	Pain and swelling of the right mandible		
Keywords:	Infection Osteonecrosis		
SPECT/CT system:	Philips Brilliance XCT	Tracer:	^{99m}Tc -DPD
Uptake:	180 min	Dose:	589 MBq
Tube loading:	150 mAs	Tube voltage:	80 kVp

Short clinical history

A 15 year old female patient with swelling of the right mandible and pain for several weeks. The patient also complained of difficulties while chewing. Blood test shows infection with increased CRP and white blood cell count.

Findings

Elevated uptake in the right mandible in SPECT (A) and planar bone scan image (B) with osteolytic and sclerotic changes on the corresponding CT and SPECT/CT images (C, D). Jaw osteomyelitis was confirmed with surgical biopsy.

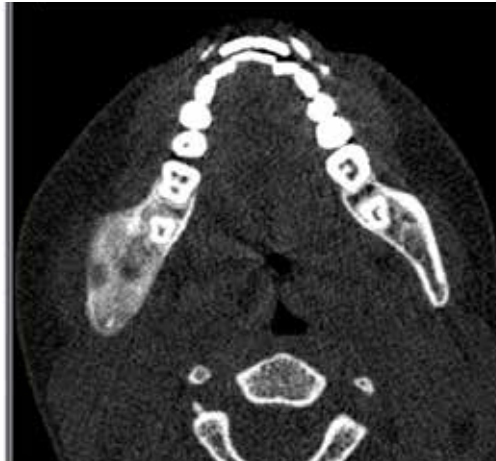Outcome and teaching point

The patient underwent surgical decortication and received local and systemic antibiotic therapy.

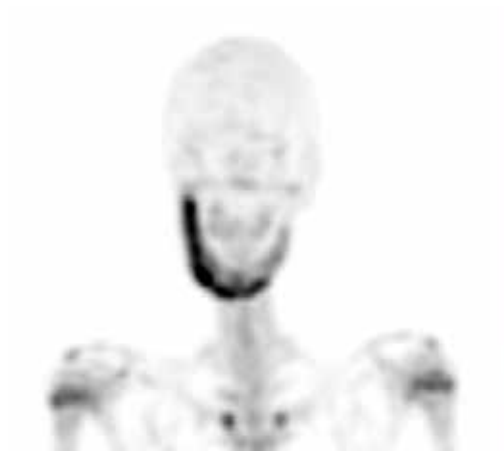Note the typical CT appearance with diffuse widening of the bone and increased uptake on SPECT/CT.



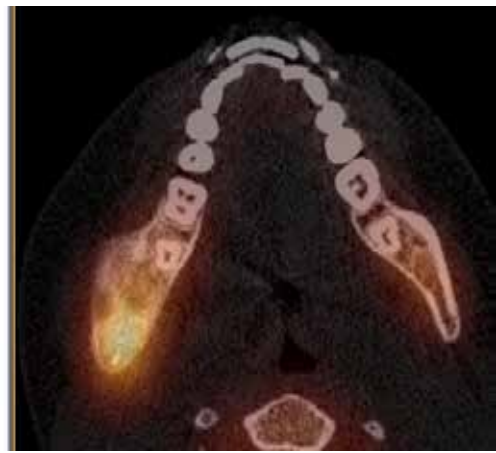
(A)



(C)



(B)



(D)

2.9. CASE No. CS 9

Study type:	Oncology		
Clinical indication:	Suspicion of Langerhans cell histiocytosis		
Keywords:	Hyperostosis		
SPECT/CT system:	Siemens Symbia T6	Tracer:	^{99m}Tc -DPD
Uptake:	240 min	Dose:	690 MBq
Tube loading:	60 mAs	Tube voltage:	130 kVp

Short clinical history

A 29 year old female patient with a history of pulmonary and possibly osseous Langerhans cell histiocytosis.

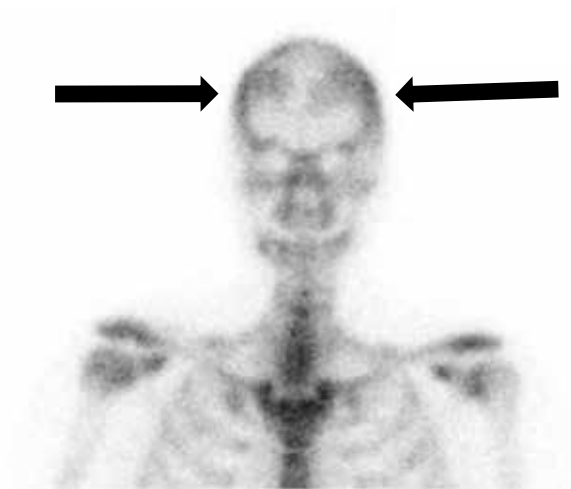
Findings

Planar image (A): Shows moderately increased uptake in the bilateral frontal bones (arrows).

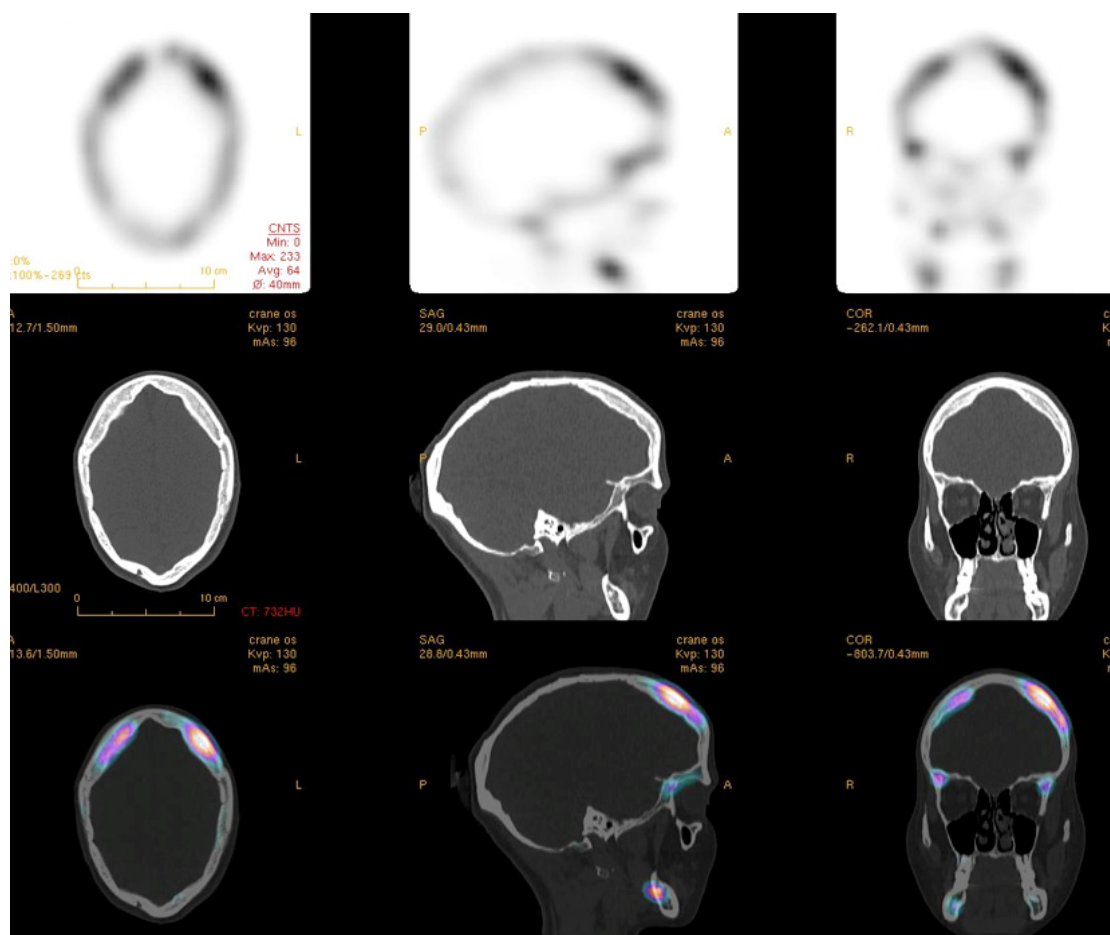
SPECT/CT (B): Shows bilateral symmetric cortical thickening, consistent with frontal hyperostosis.

Outcome

Hyperostosis frontalis is a normal variant. Langerhans cell histiocytosis was ruled out, and no treatment was given.



(A)



(B)

3. THORACIC SPINE

3.1. CASE No. TS 1

Study type:	Traumatology Oncology		
Clinical indication:	Restaging		
Keywords:	Restaging Rib fracture		
SPECT/CT system:	Siemens Symbia T6	Tracer:	^{99m}Tc -DPD
Uptake:	150 min	Dose:	651 MBq
Tube loading:	120 mAs	Tube voltage:	80 kVp

Short clinical history

A 64 year old female patient with a history of breast cancer. The patient had undergone a mastectomy with a combined radiation and chemotherapy 5 years earlier. SPECT/CT was requested for restaging purposes.

Findings

Planar images of previous examination 5 years earlier (A): Shows no pathologic uptake.

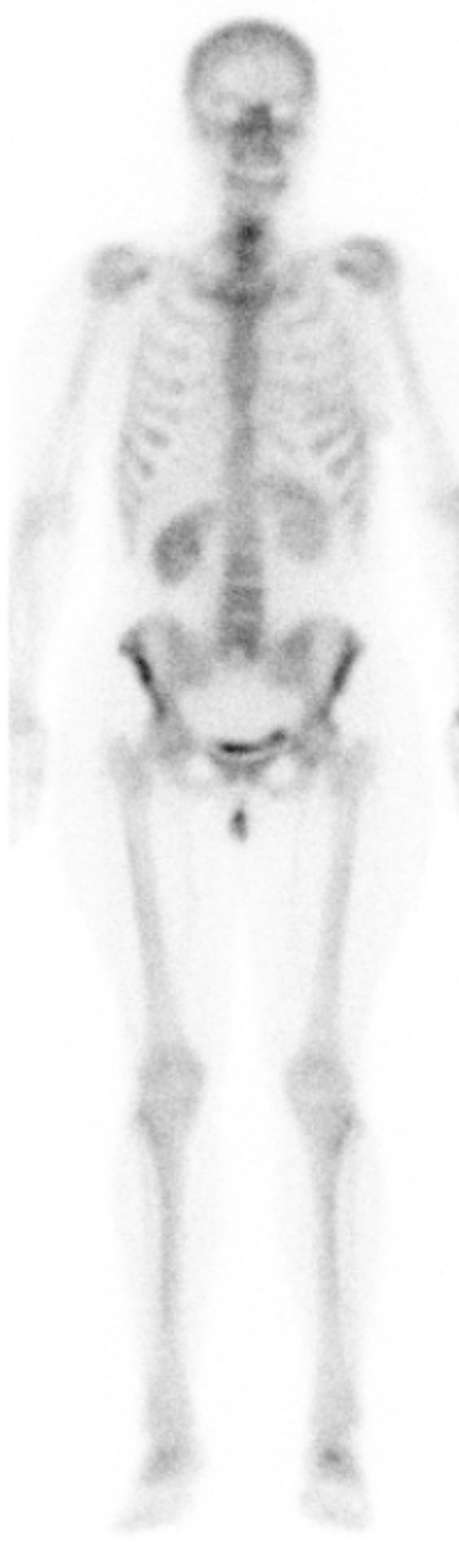
Planar images of recent examination (B): Shows a new focal uptake in the right 7th rib (arrow).

SPECT/CT (C): Shows slightly thickened cortical bone (white arrow). The lesion was classified as an old fracture. No signs of osseous metastases.

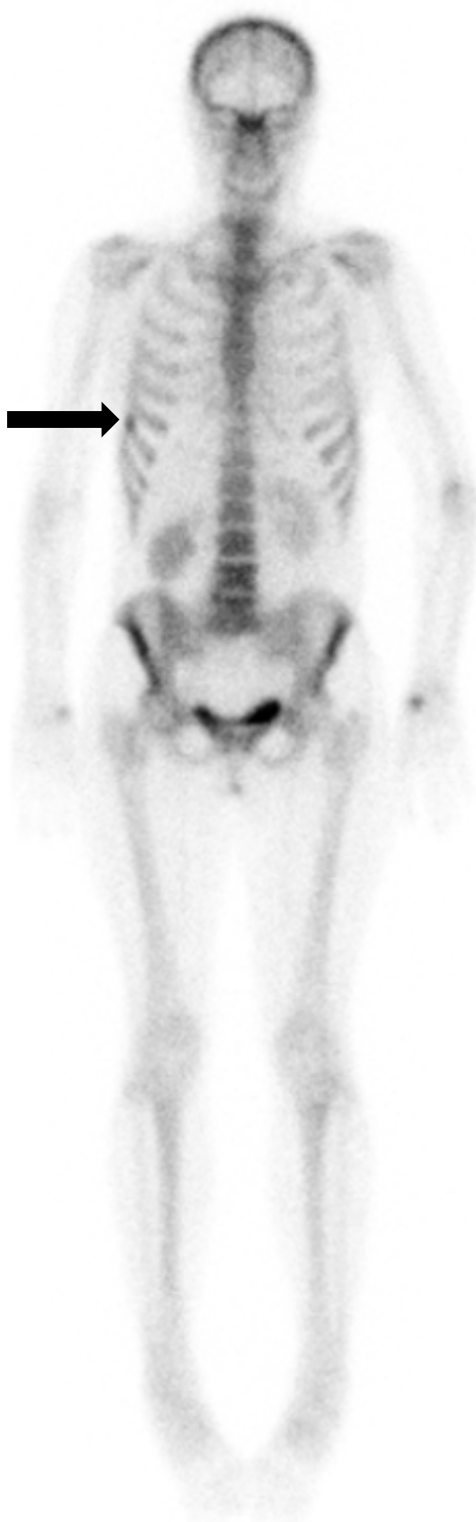
Outcome and teaching point

No therapy was needed.

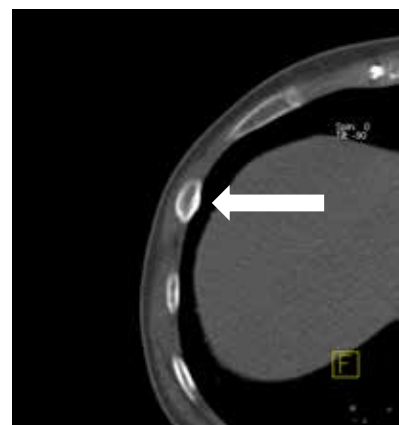
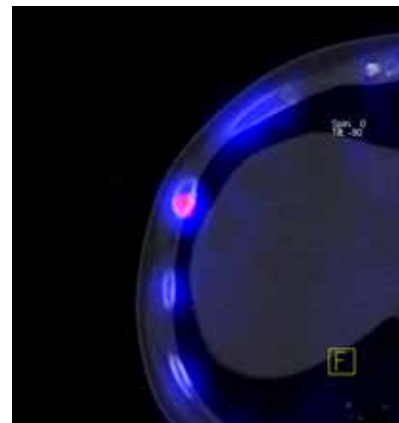
Note the typical appearance of an isolated, older rib fracture.



(A)



(B)



(C)

3.2. CASE No. TS 2

Study type:	Traumatology		
Clinical indication:	Restaging		
Keywords:	Restaging Rib fracture		
SPECT/CT system:	Siemens Symbia T6	Tracer:	^{99m}Tc -DPD
Uptake:	180 min	Dose:	511 MBq
Tube loading:	120 mAs	Tube voltage:	80 kVp

Short clinical history

A 56 year old female patient presenting with polyarthritis of multiple finger joints. Bone scintigraphy was performed to verify medical indication for radiosynoviorthesis.

Findings

Planar images (A): Show new focal uptake in the right 2nd rib (black arrow).

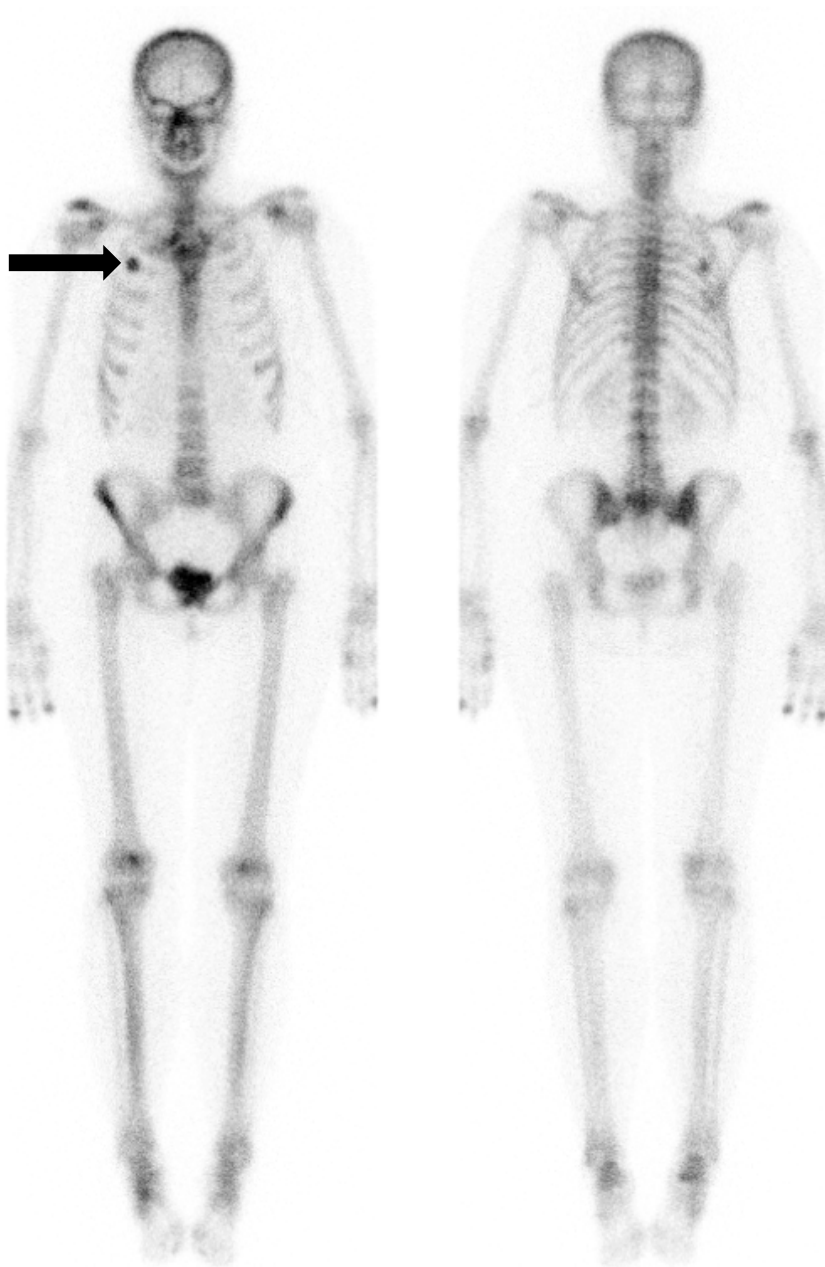
SPECT/CT (B): Shows callus with thickened cortical bone due to callus (white arrow). The lesion was classified as an old fracture.

Whole body scintigraphy shows polyarthrosis (thoracic spine, right acromioclavicular joint, right ISJ and patellae).

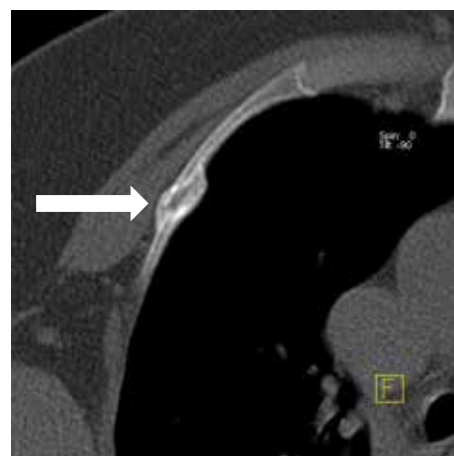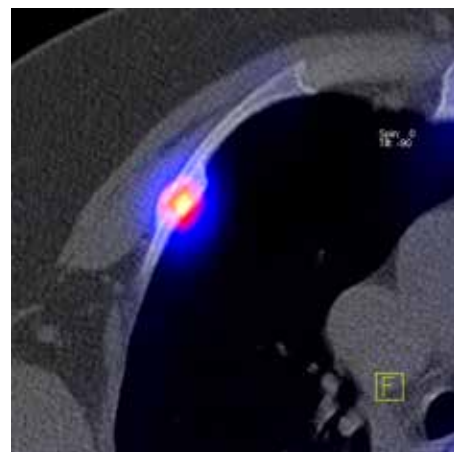
Outcome and teaching point

No therapy.

Note the typical appearance of an isolated, older rib fracture.



(A)



(B)

3.3. CASE No. TS 3

Study type:	Oncology		
Clinical indication:	Follow-up Breast cancer		
Keywords:	Breast cancer Bone metastasis		
SPECT/CT system:	Siemens Symbia T6	Tracer:	^{99m}Tc -DPD
Uptake:	180 min	Dose:	750 MBq
Tube loading:	53 mAs	Tube voltage:	130 kVp

Short clinical history

A 55 year old female patient with a history of breast cancer was treated with surgery and radiation chemotherapy. A bone scan was performed as part of the routine follow-up.

Findings

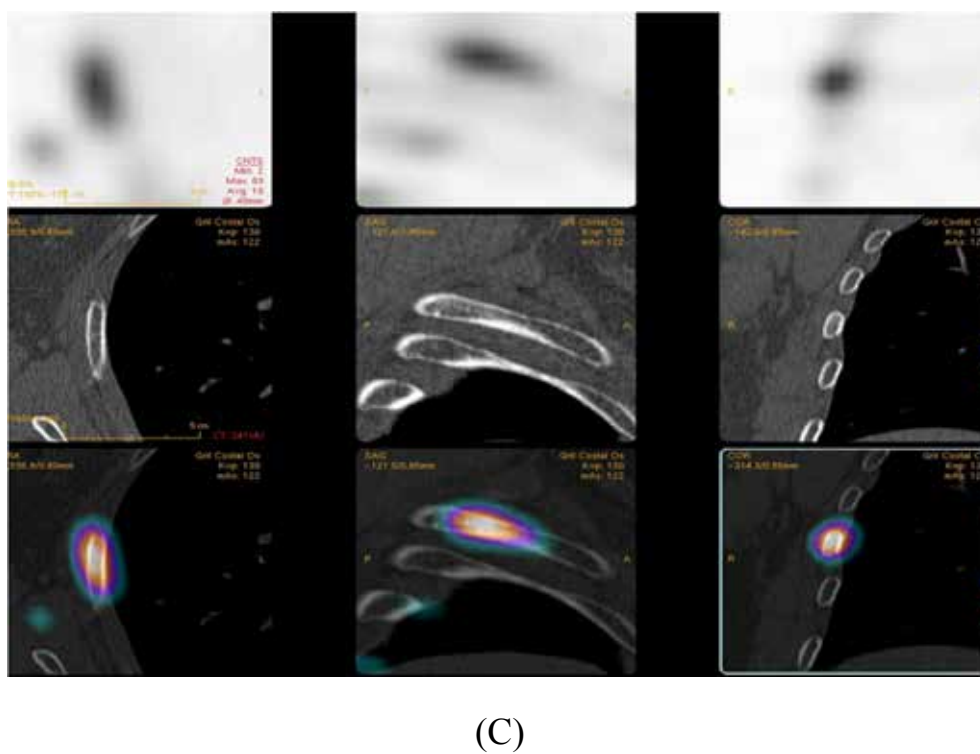
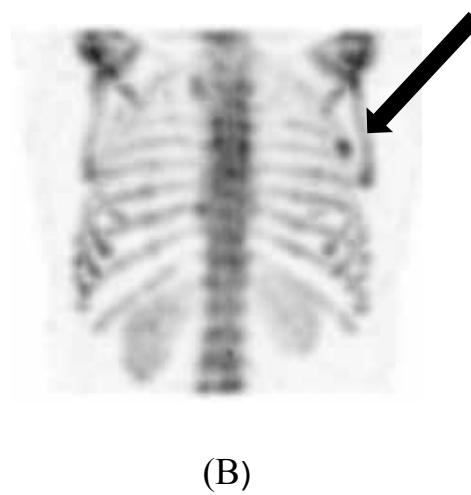
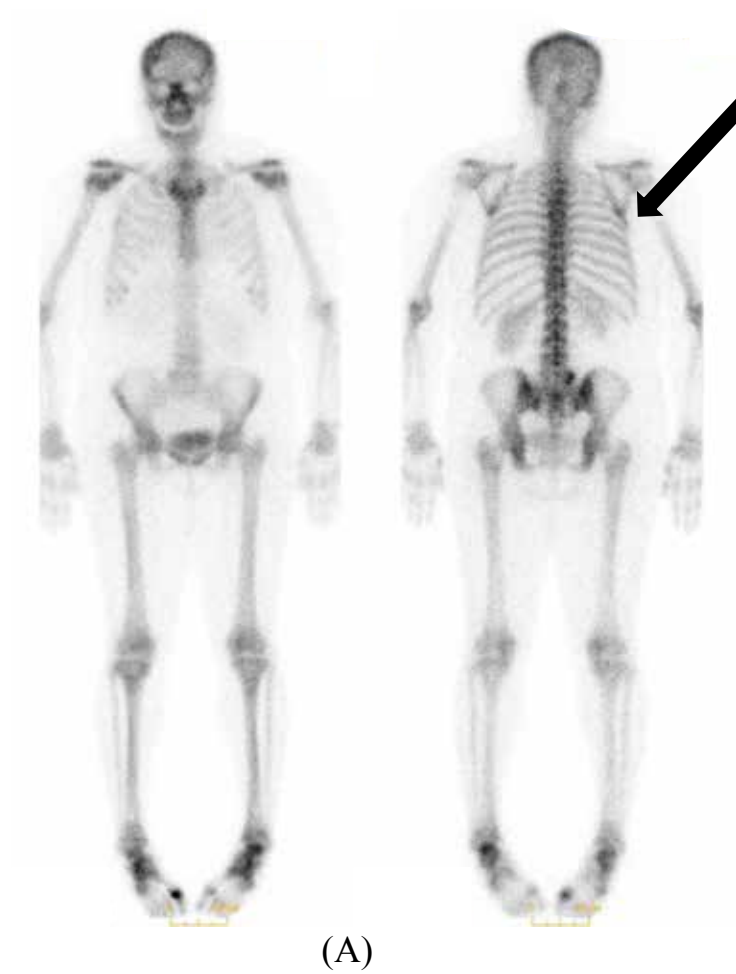
Planar bone scan and SPECT alone show an isolated focus located in the 5th rib (A, arrow).

SPECT/CT allows the localization of focal increase tracer uptake to the right 5th rib (B, MIP image, arrow) corresponding to what appears to be an area of medullary hyperdensity, suspicious for bone metastasis (C).

Outcome and teaching point

No treatment was given. A repeat bone scan 6 months later was negative.

Note SPECT/CT or not, a solitary rib focus remains highly unlikely to represent a bone metastasis.



3.4. CASE No. TS 4

Study type:	Traumatology		
Clinical indication:	Post-traumatic chest pain		
Keywords:	Rib fractures		
SPECT/CT system:	Siemens Symbia T6	Tracer:	^{99m}Tc -DPD
Uptake:	240 min	Dose:	790 MBq
Tube loading:	151 mAs	Tube voltage:	130 kVp

Short clinical history

A 65 year old female patient fell while standing on a chair 5 weeks earlier and complained of persistent thoracic pain.

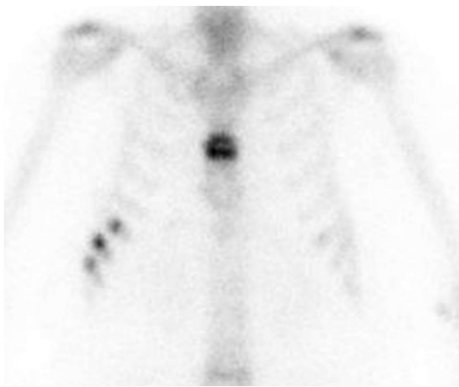
Findings

Planar (A): Shows increased uptake in the sternal body and the anterior arc of the right 6th, 7th and 8th ribs.

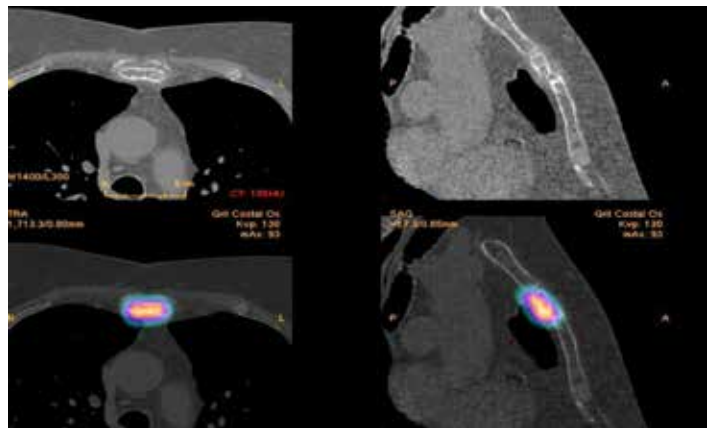
SPECT/CT: Shows sternal fracture (B), recent fractures of the right 6th, 7th and 8th ribs (C) and older fractures of the 4th and 6th left ribs (D: no uptake).

Teaching point

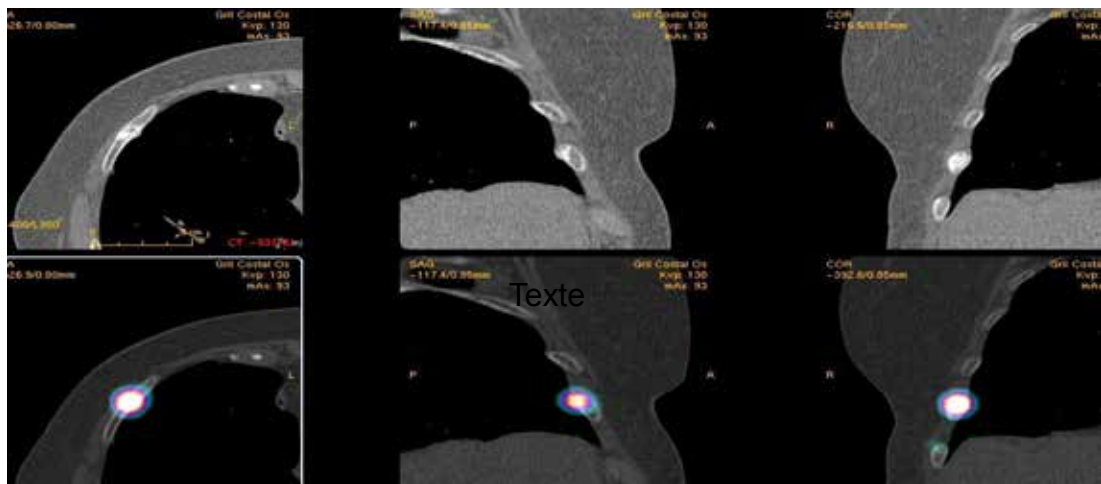
Note SPECT/CT allows for a comprehensive assessment of traumatic lesions.



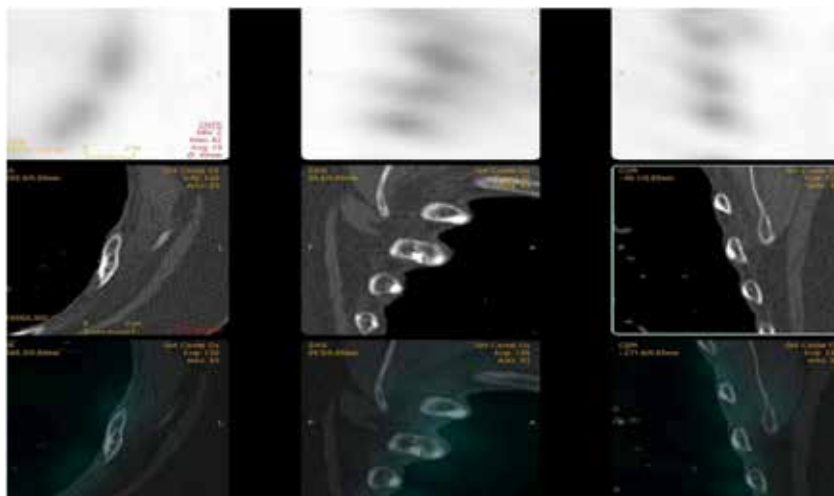
(A)



(B)



(C)



(D)

3.5. CASE No. TS 5

Study type:	Rheumatology		
Clinical indication:	Diffuse back pain		
Keywords:	Compression fractures		
SPECT/CT system:	Siemens Symbia T6	Tracer:	^{99m}Tc -DPD
Uptake:	240 min	Dose:	720 MBq
Tube loading:	229 mAs	Tube voltage:	130 kVp

Short clinical history

A 79 year old female patient with diffuse back pain. The patient has no history of trauma but has been previously diagnosed with osteoporosis.

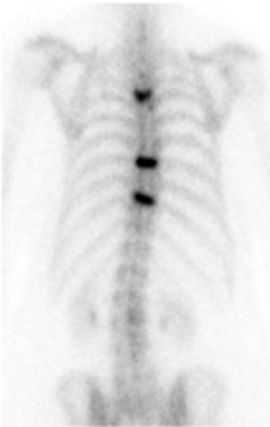Findings

Planar (A): Shows highly increased uptake in the vertebral bodies of T4, T8 and T10.

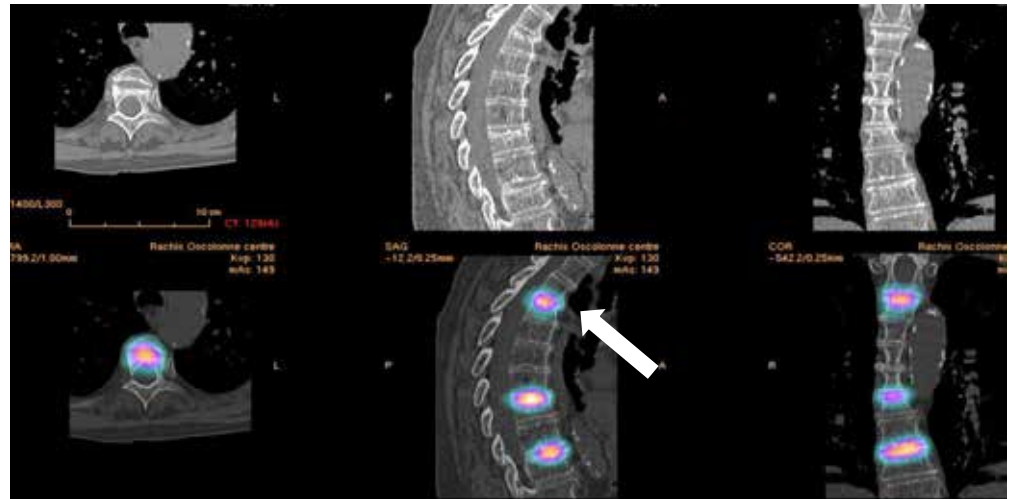
SPECT/CT (B, C, D): Show that the areas of increased uptake correspond to vertebral compression fractures (upper plate of the vertebral bodies of T4: B, T8: D and T10: D, arrows).

Teaching point

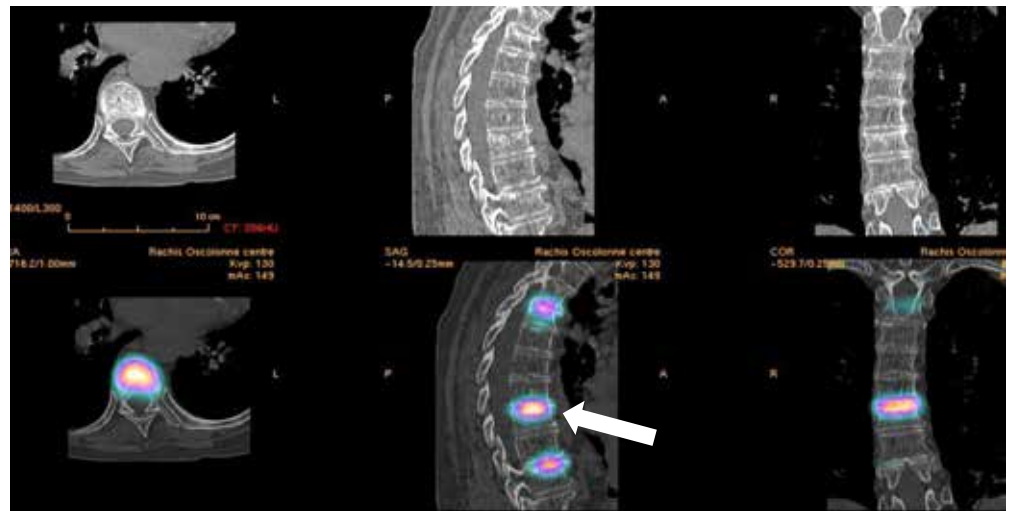
Note the uptake confined to the upper plate of the vertebrae.



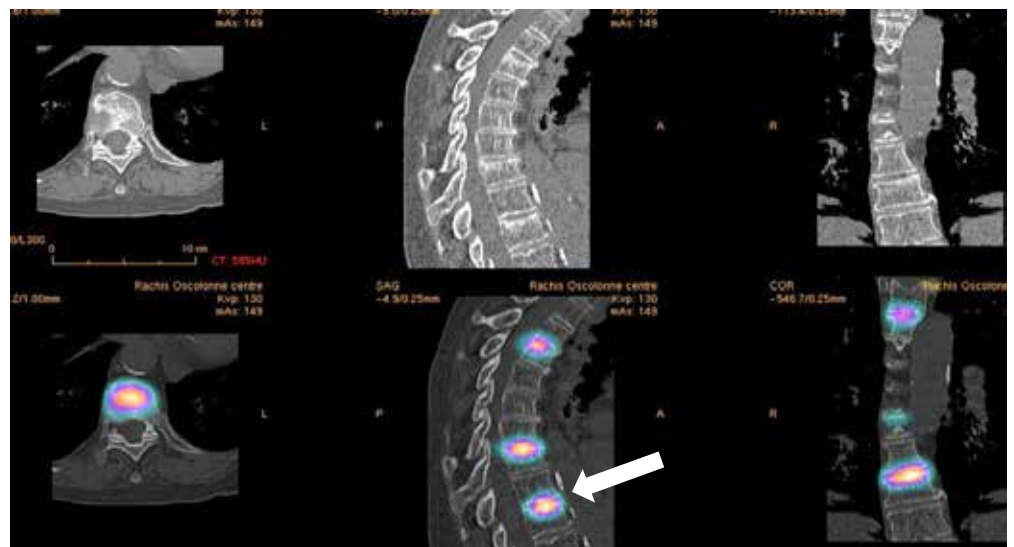
(A)



(B)



(C)



(D)

3.6. CASE No. TS 6

Study type:	Orthopaedic		
Clinical indication:	Back pain		
Keywords:	Back pain Fracture		
SPECT/CT system:	Siemens Symbia T2	Tracer:	^{99m}Tc -DPD
Uptake:	150 min	Dose:	502 MBq
Tube loading:	120 mAs	Tube voltage:	80 kVp

Short clinical history

An 80 year old female patient diagnosed with osteoporosis and complaining of increasing back pain for 10 days.

Findings

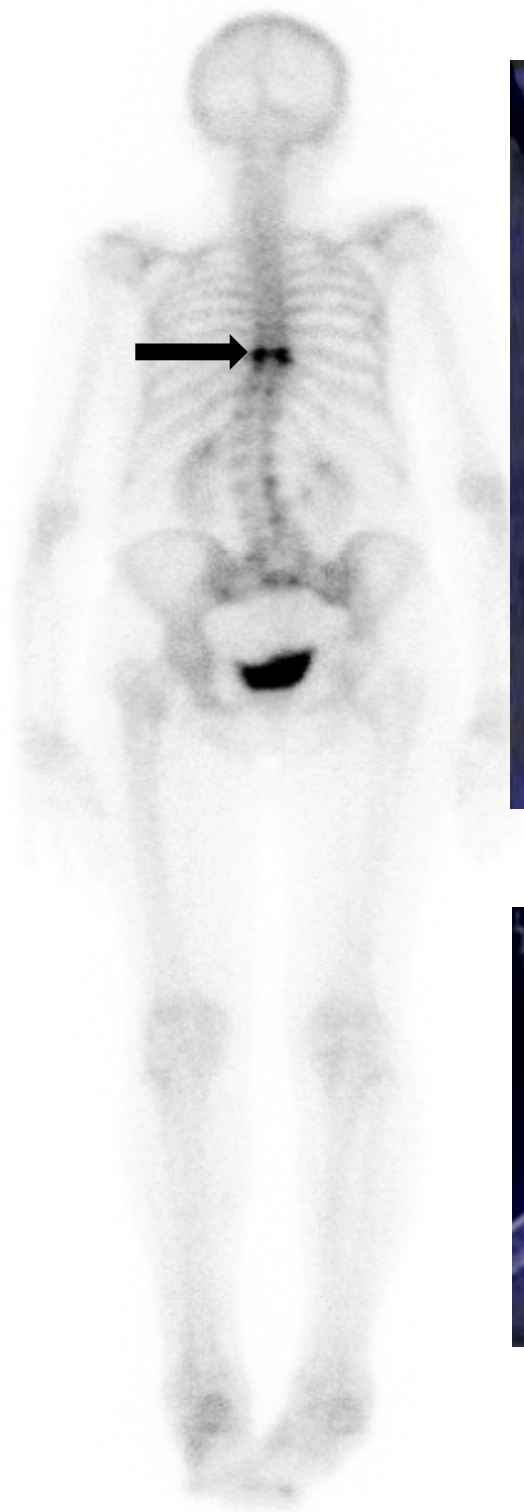
Planar bone scan (A): Shows an isolated focus located in the 7th thoracic vertebral body (arrow) suspicious of a fracture. Furthermore, a whole body scan shows kyphosis and scoliosis.

SPECT/CT (B): Allows locating the uptake in the wedge-shaped, 7th thoracic vertebrae. Posterior elements of the segment are intact.

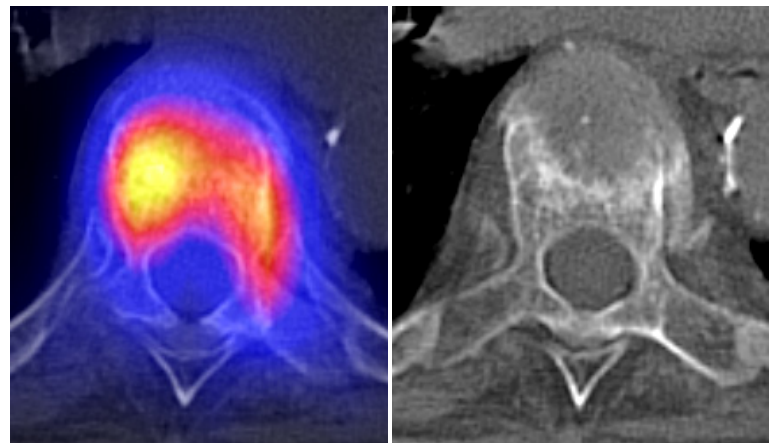
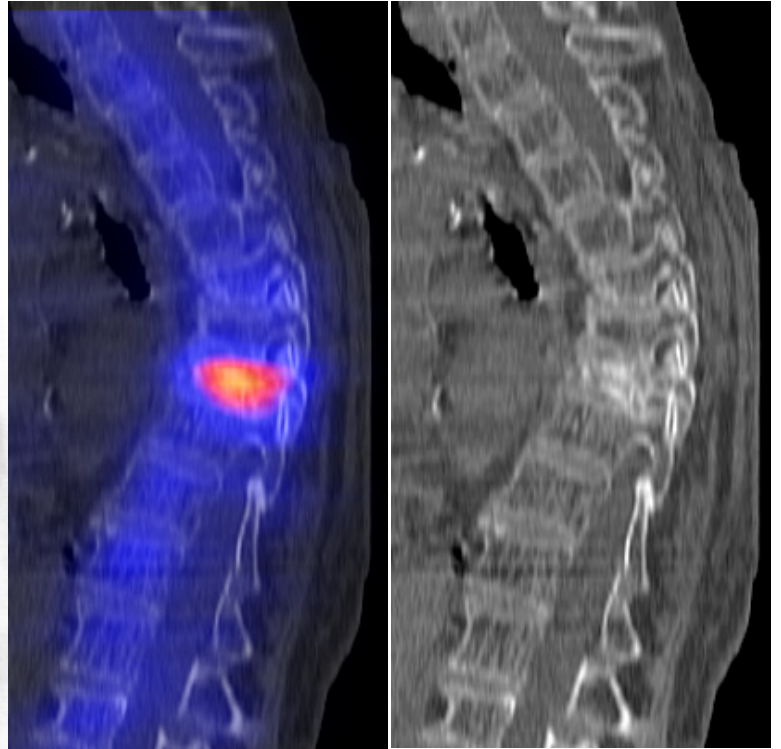
Outcome and teaching point

Conservative therapy with pain management.

Note the typical bone scan of a patient with an osteoporotic compression fracture.



(A)



(B)

3.7. CASE No. TS 7

Study type:	Oncology Traumatology		
Clinical indication:	Staging of breast cancer		
Keywords:	Rib fracture		
SPECT/CT system:	Siemens Symbia T6	Tracer:	^{99m} Tc-DPD
Uptake:	240 min	Dose:	740 MBq
Tube loading:	75 mAs	Tube voltage:	130 kVp

Short clinical history

A 64 year old female patient diagnosed with breast cancer undergoing initial staging. The patient had no complaints.

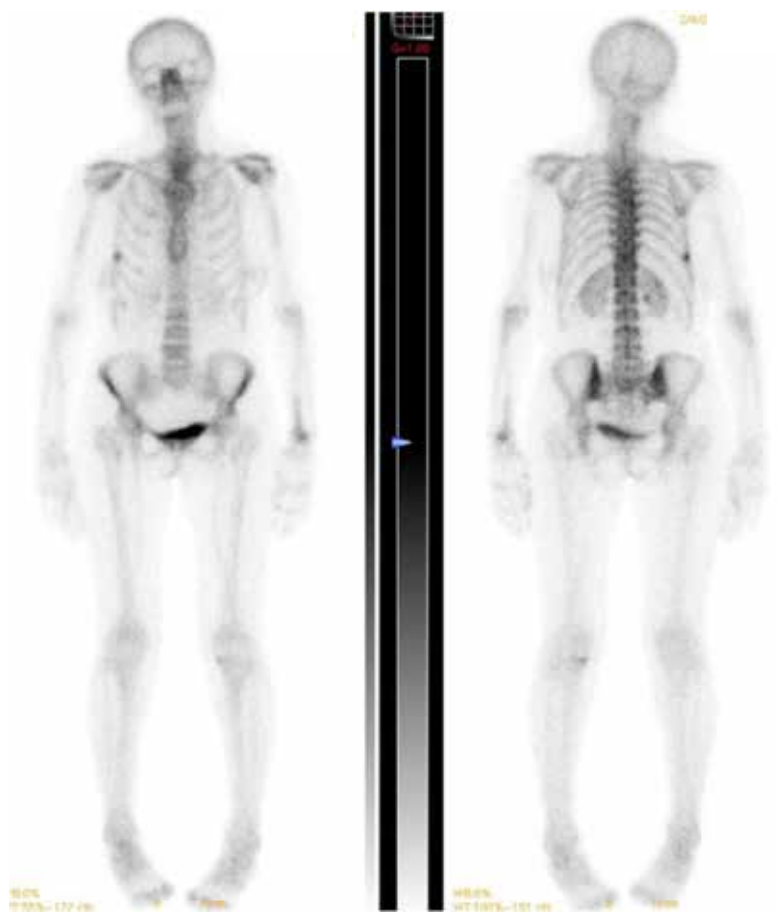
Findings

Planar image (A): Shows focus of increased uptake on the lateral arc of the right 6th rib.

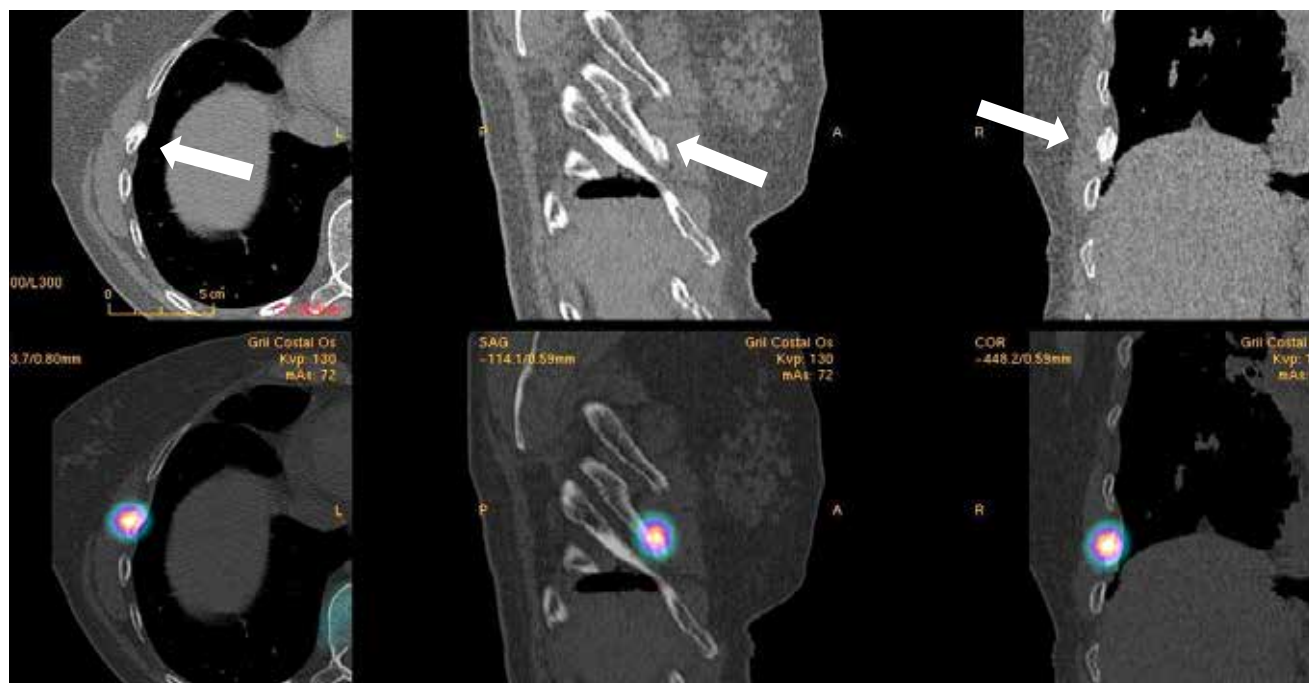
SPECT/CT (B): Confirms fracture (arrows).

Outcome

No specific treatment needed. Follow-up confirms absence of metastasis.



(A)



(B)

3.8. CASE No. TS 8

Study type:	Orthopaedics		
Clinical indication:	Back pain		
Keywords:	Back pain Fracture		
SPECT/CT system:	Siemens Symbia T2	Tracer:	^{99m}Tc -DPD
Uptake:	150 min	Dose:	502 MBq
Tube loading:	120 mAs	Tube voltage:	80 kVp

Short clinical history

A 30 year old male patient with back pain undergoing chiropractic therapy. The plain film X ray was inconclusive; therefore, a bone scan was requested for further diagnosis.

Findings

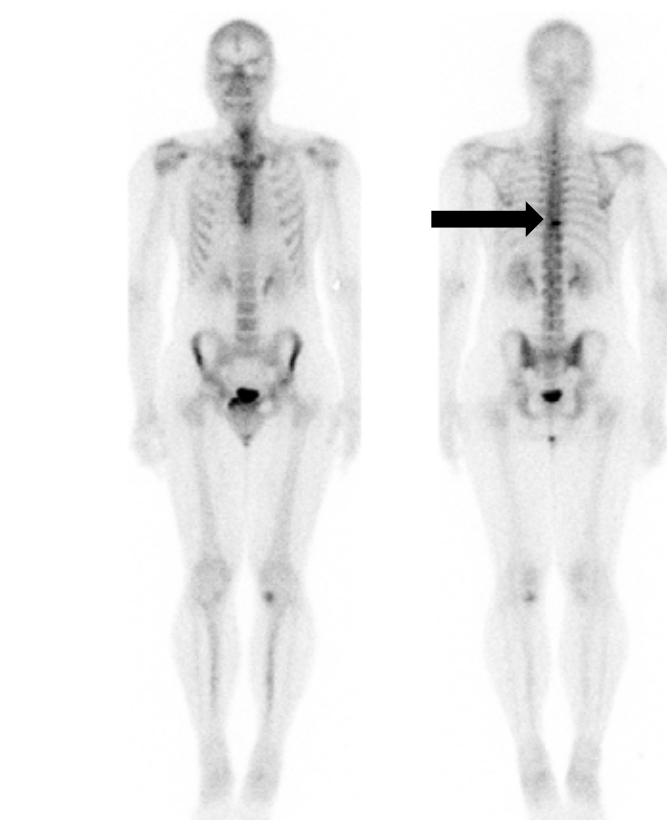Planar bone scan (A) and SPECT alone show an isolated focus located in 9th vertebral body suspicious of a fracture versus non-fracture (black arrow). Differential diagnosis (bone metastasis).

SPECT/CT (B) allows locating the uptake in an isolated upper end plate infarction (white arrow) s/p chiropractic therapy.

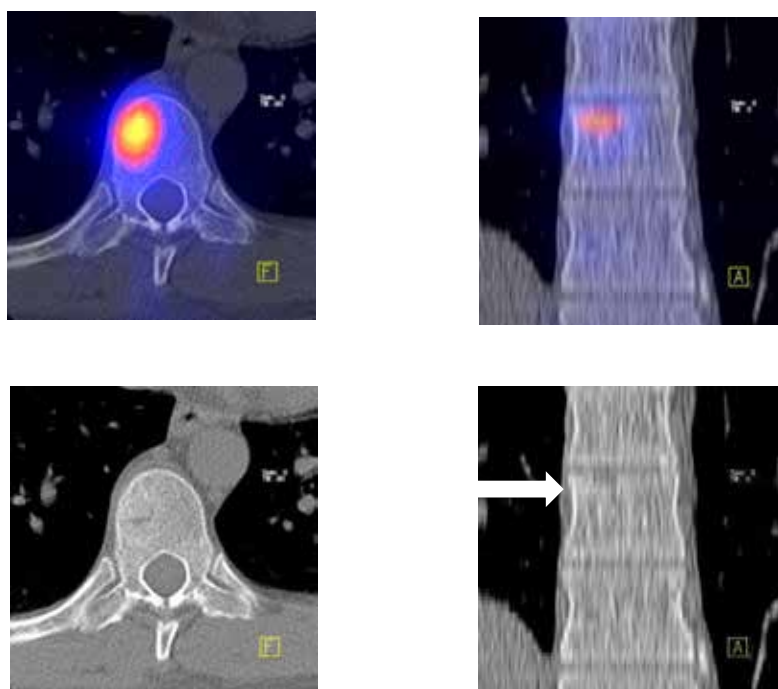
There is no evidence of bone metastasis.

Outcome

Conservative therapy with pain management.



(A)



(B)

3.9. CASE No. TS 9

Study type:	Degenerative		
Clinical indication:	Lower back pain		
Keywords:	Ankylosing hyperostosis		
SPECT/CT system:	Siemens Symbia T6	Tracer:	^{99m}Tc -DPD
Uptake:	240 min	Dose:	738 MBq
Tube loading:	183 mAs	Tube voltage:	130 kVp

Short clinical history

A 60 year old male patient suffering from lower back pain and morning stiffness.

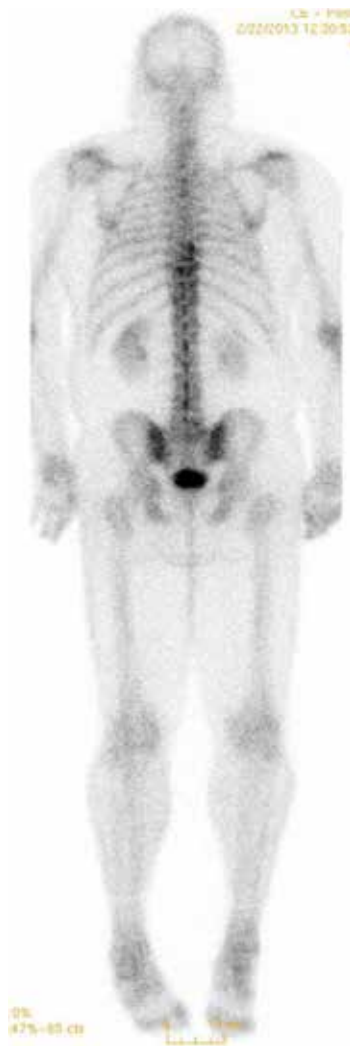Findings

Whole body scan (A): Shows heterogeneous uptake of the thoracic spine.

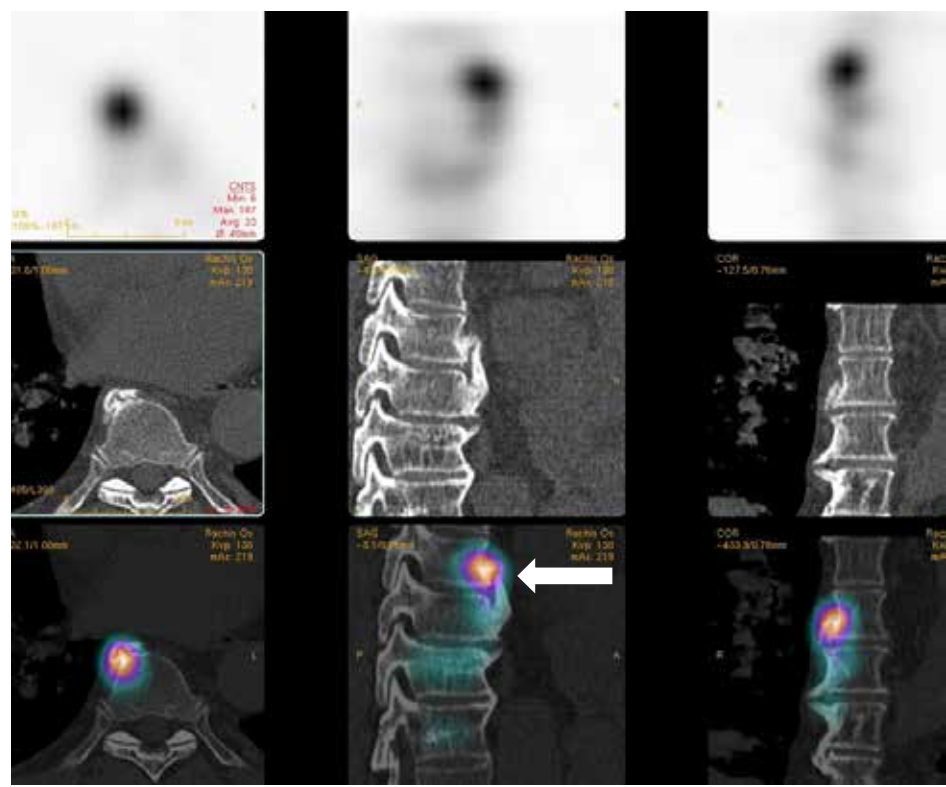
SPECT/CT (B, C): Shows severe osteophytosis, mostly active at the level of T7 (B, arrow), consistent with ankylosing hyperostosis. The bridging osteophyte observed at the level of T9 (C, arrow) does not show any corresponding anomaly on the SPECT study.

Teaching point

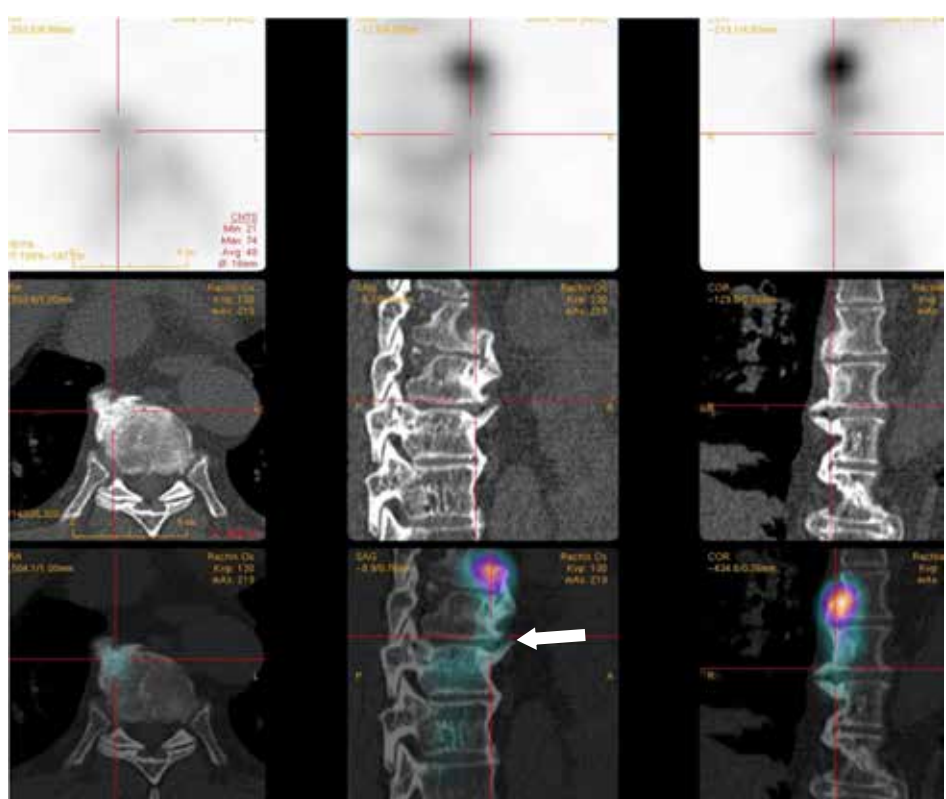
Note the discrepancy between some of the radiological changes and the scintigraphic anomalies (small arrow).



(A)



(B)



(C)

4. LUMBAR SPINE

4.1. CASE No. LS 1

Study type:	Orthopaedic Traumatology		
Clinical indication:	Polyarthritis		
Keywords:	Osteoarthritis		
SPECT/CT system:	Siemens Symbia T2	Tracer:	^{99m}Tc -DPD
Uptake:	160 min	Dose:	533 MBq
Tube loading:	120 mAs	Tube voltage:	80 kVp

Short clinical history

A 64 year old female patient with arthralgia of multiple joints. Bone scintigraphy was performed to rule out rheumatic disease.

Findings

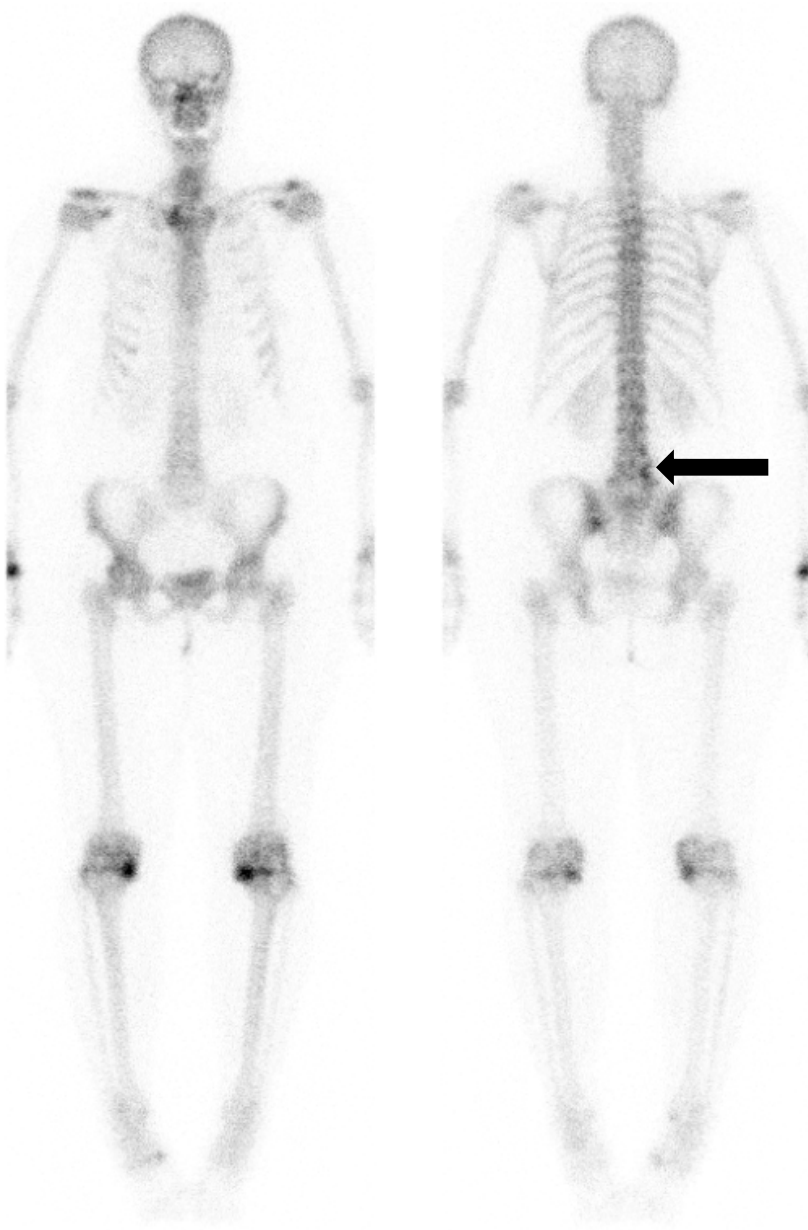Planar images (A): Shows new focal uptake in the lumbar spine (arrow). Whole body scintigraphy shows polyarthrosis with maximum uptake in both knees.

SPECT/CT (B): Shows typical signs of osteoarthritis with hyperostosis of the right 4th facet joint (arrow).

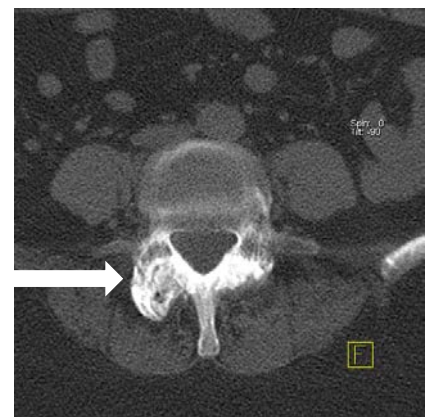
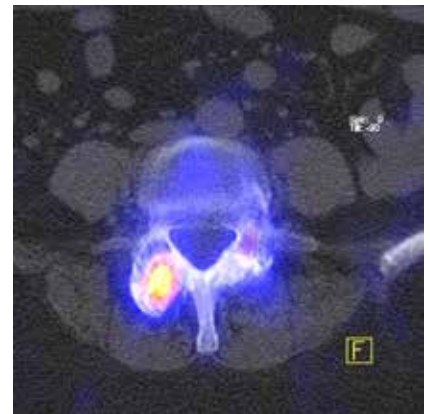
Outcome and teaching point

No therapy was needed.

Note the typical appearance of osteoarthritis of a vertebral facet joint.



(A)



(B)

4.2. CASE No. LS 2

Study type:	Orthopaedics Degenerative		
Clinical indication:	Evaluation of low back pain		
Keywords:	Facet joint Spondylolysis		
SPECT/CT system:	Siemens Symbia T6	Tracer:	^{99m}Tc -DPD
Uptake:	240 min	Dose:	712 MBq
Tube loading:	158 mAs	Tube voltage:	130 kVp

Short clinical history

A 41 year old male patient with lower back pain. The patient received irradiation towards the left buttock for 6 months.

A CT shows herniated lumbar disks in L4/5 and L5/S1, but lateralized to the right. Various treatments were ineffective.

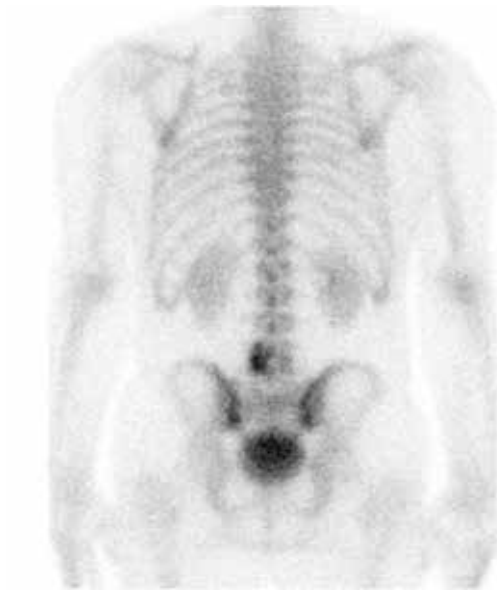Findings

Planar (A): Shows increased uptake in the left side of L4/5.

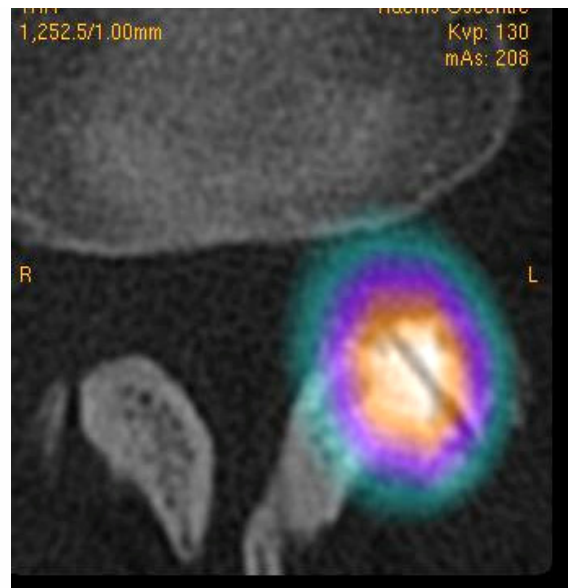
SPECT/CT (B, C, D): Shows focus of increased uptake at the level of the right facet joint L4/5, extending to the isthmus. CT confirms degenerative changes in the facet joint and also shows a small fissuration of the pars interarticularis of L4 (arrow).

Outcome

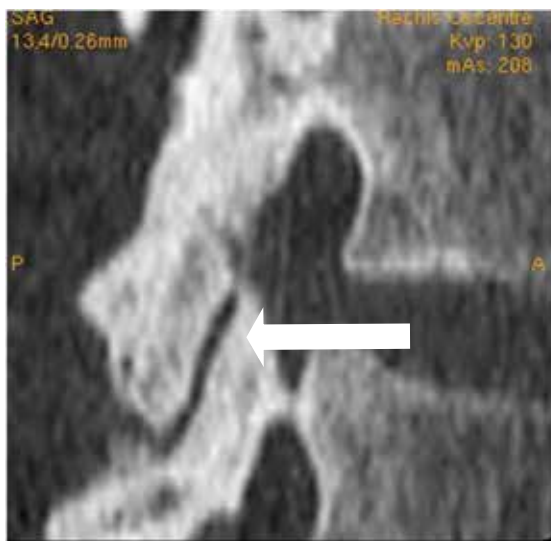Conservative treatment.



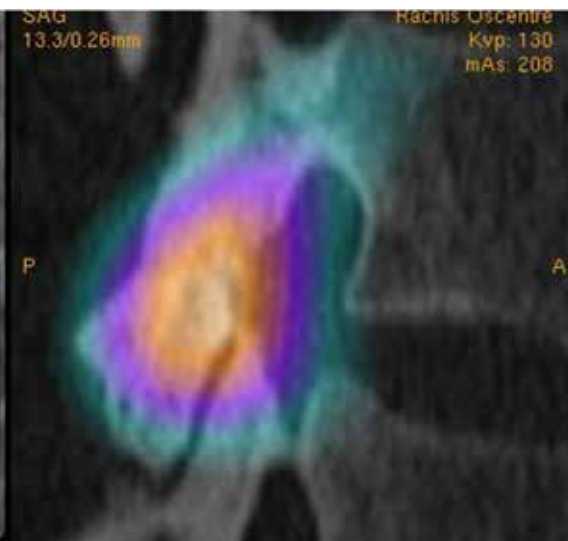
(A)



(B)



(C)



(D)

4.3. CASE No. LS 3

Study type:	Degenerative		
Clinical indication:	Lower back pain		
Keywords:	Facet joint		
SPECT/CT system:	Siemens Symbia T6	Tracer:	^{99m}Tc -DPD
Uptake:	240 min	Dose:	670 MBq
Tube loading:	171 mAs	Tube voltage:	130 kVp

Short clinical history

A 49 year old female patient with chronic right lower back pain.

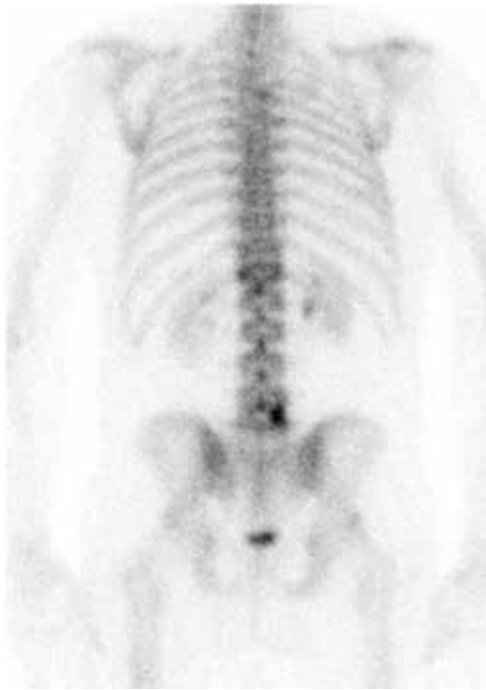Findings

Planar (A): Shows increased uptake on the right side of L4/5.

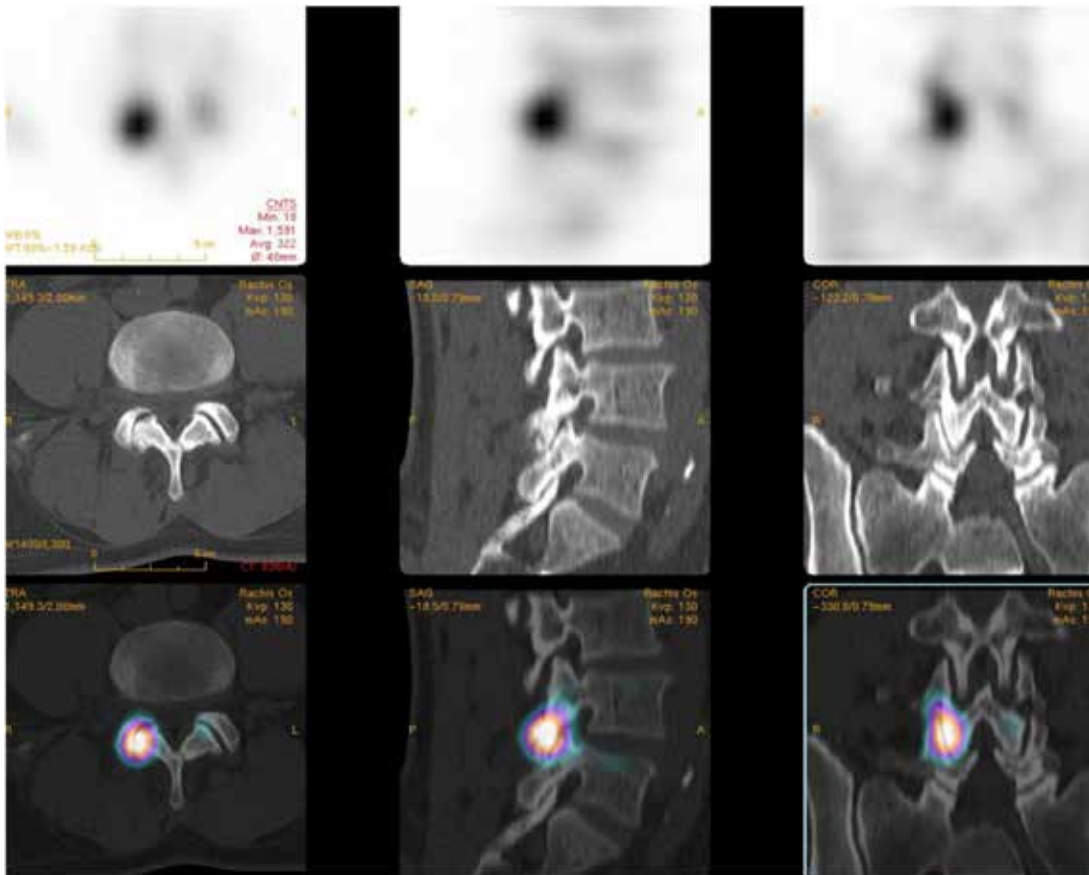
SPECT/CT (B): Shows focus of increased uptake at the level of the right facet joint L4/5. CT confirms slight degenerative changes in the facet joint (mainly space narrowing, very limited hyperostosis).

Outcome

The metabolic part highlights the active status of the disease in spite of limited morphologic changes.



(A)



(B)

4.4. CASE No. LS 4

Study type:	Degenerative		
Clinical indication:	Chronic lower back pain		
Keywords:	Disc arthropathy Facet joint arthropathy		
SPECT/CT system:	Siemens Symbia T6	Tracer:	^{99m}Tc -DPD
Uptake:	240 min	Dose:	700 MBq
Tube loading:	108 mAs	Tube voltage:	130 kVp

Short clinical history

A 59 year old female patient with chronic lower back pain. The patient had been diagnosed with breast cancer 2 years earlier and had been treated with anastrozole.

Findings

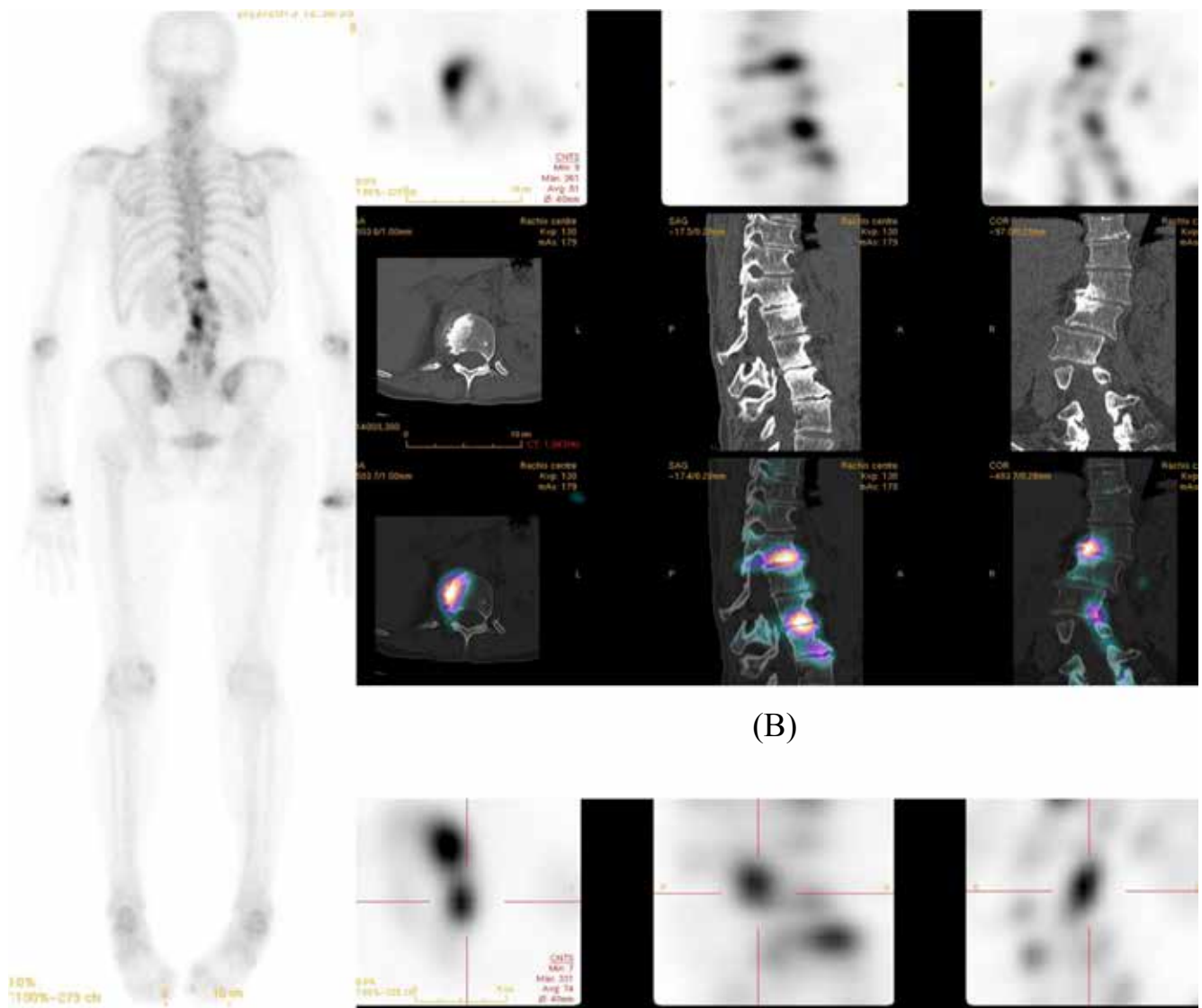
Whole body scan (A): Shows dorsolumbar scoliosis, with highly heterogeneous uptake.

SPECT/CT (B, C): Shows severe osteochondrosis based on degenerative disc arthropathy (B) and facet joint arthropathy (C).

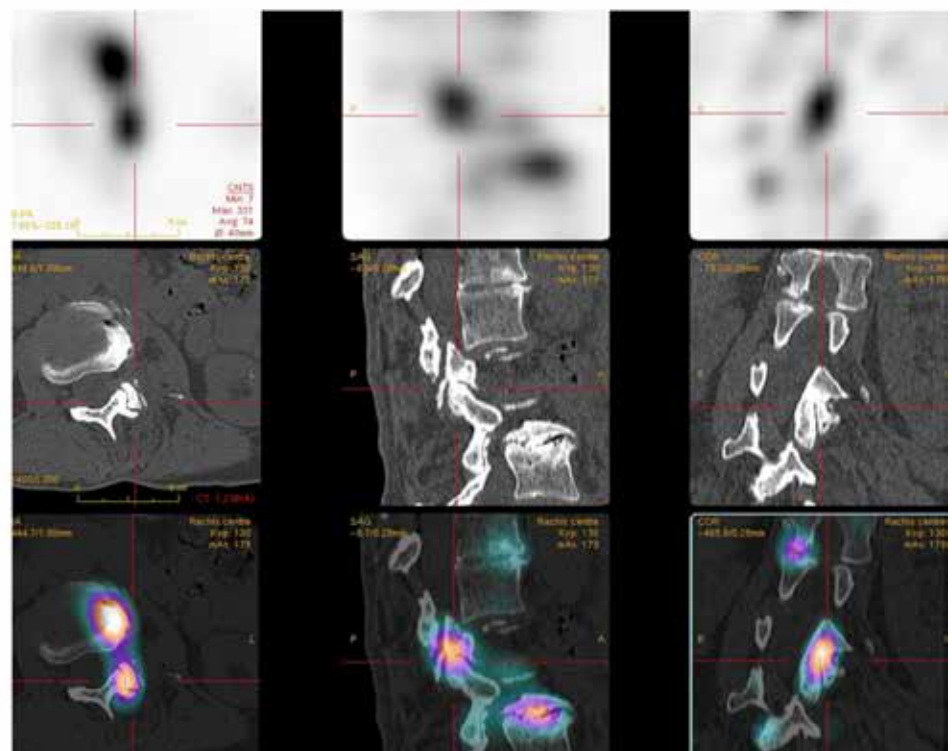
Outcome and teaching point

Conservative treatment.

Note SPECT/CT excludes metastases in a single diagnostic step (CT improves specificity).



(B)



(C)

4.5. CASE No. LS 5

Study type:	Degenerative		
Clinical indication:	Lower back pain		
Keywords:	Disc arthropathy		
SPECT/CT system:	Siemens Symbia T6	Tracer:	^{99m}Tc -DPD
Uptake:	240 min	Dose:	703 MBq
Tube loading:	125 mAs	Tube voltage:	130 kVp

Short clinical history

A 51 year old female patient with lower back pain accompanied by diffused joint tenderness. No sign suggesting inflammatory arthropathy. Suspected fibromyalgia.

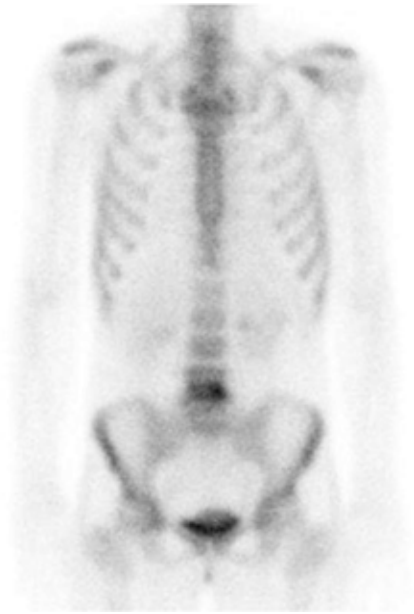Findings

Planar (A, B): Shows increased uptake at the level L4/5.

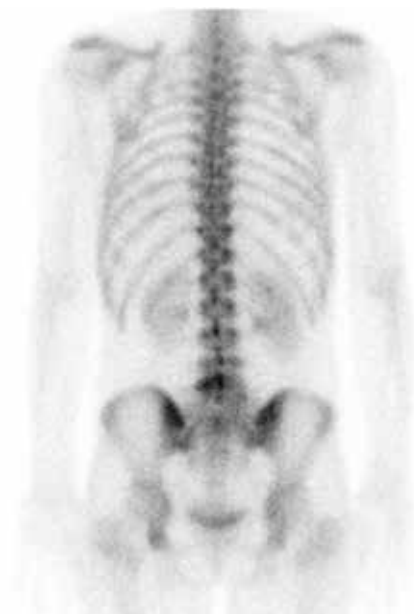SPECT/CT (C): Shows severe osteoarthritis L4/5 with additional endplate infarctions.

Outcome

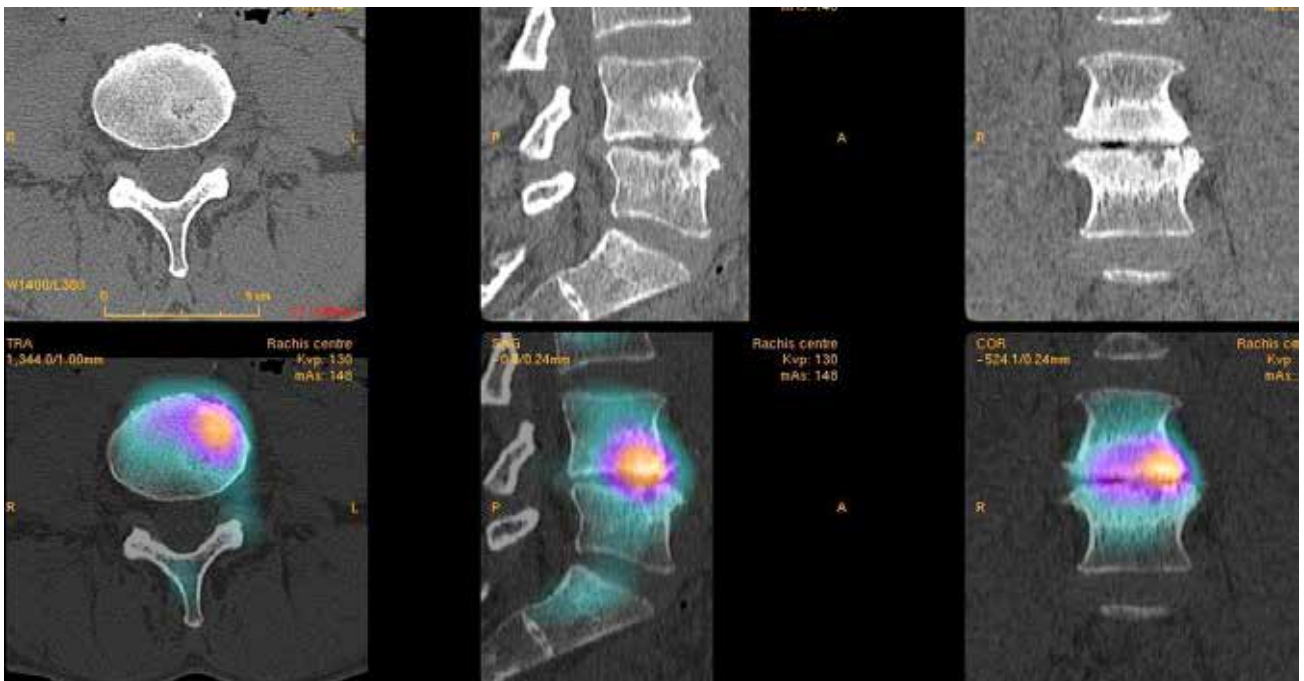
Fibromyalgia was ruled out and conservative treatment applied.



(A)



(B)



(C)

4.6. CASE No. LS 6

Study type:	Degenerative Rheumatology		
Clinical indication:	Lower back pain		
Keywords:	Disc arthropathy		
SPECT/CT system:	Siemens Symbia T6	Tracer:	^{99m}Tc -DPD
Uptake:	240 min	Dose:	788 MBq
Tube loading:	153 mAs	Tube voltage:	130 kVp

Short clinical history

A 74 year old female patient with lower back pain and a prior diagnosis of osteoporosis. The patient had a previous history of compression fracture of T12.

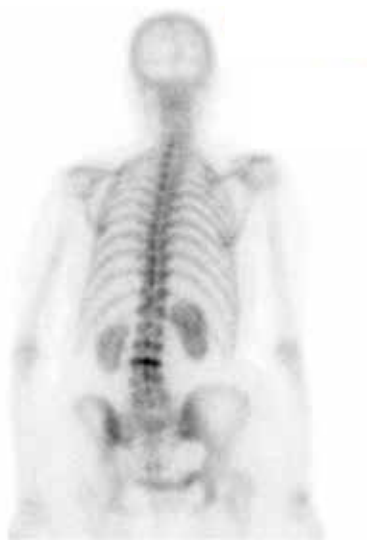Findings

Planar image (A): Shows a highly increased uptake in the vertebral body of L3.

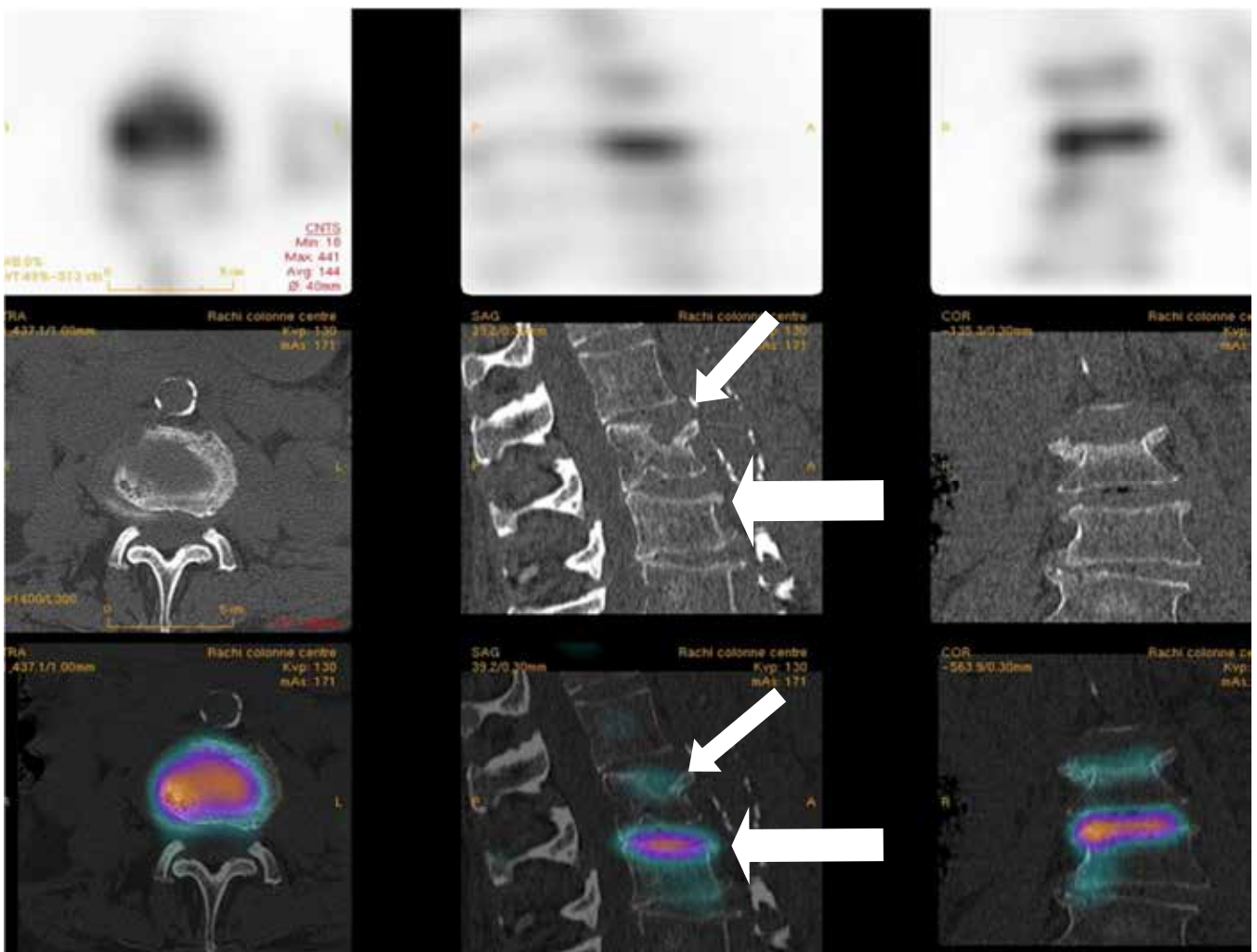
SPECT/CT (B): Shows a compression fracture of the upper plate of L3 (large arrow) and a slightly increased uptake of the upper plate of L2 consistent with a less recent fracture. CT also shows a Schmorl's node (small arrow).

Teaching point

Note the age of the fractures is characterized by the metabolic activity rather than by the morphological features.



(A)



(B)

4.7. CASE No. LS 7

Study type:	Orthopaedics Degenerative		
Clinical indication:	Pain Suspected loosening of screw		
Keywords:	Osteoarthritis Osteochondrosis Implant loosening		
SPECT/CT system:	General Electric Discovery 670	Tracer:	^{99m}Tc -DPD
Uptake:	180 min	Dose:	659 MBq
Tube loading:	120–400 mAs	Tube voltage:	120 kVp

Short clinical history

A 73 year old female patient with chronic lower back pain after multiple revision spondylodesis had been performed in the last 8 years. Suspicion of additional fractures, screw loosening and/or ISJ arthritis. The MRI was inconclusive due to inferior image quality because the patient had not been able to lie on her back within the scanner for an adequate imaging time.

Findings

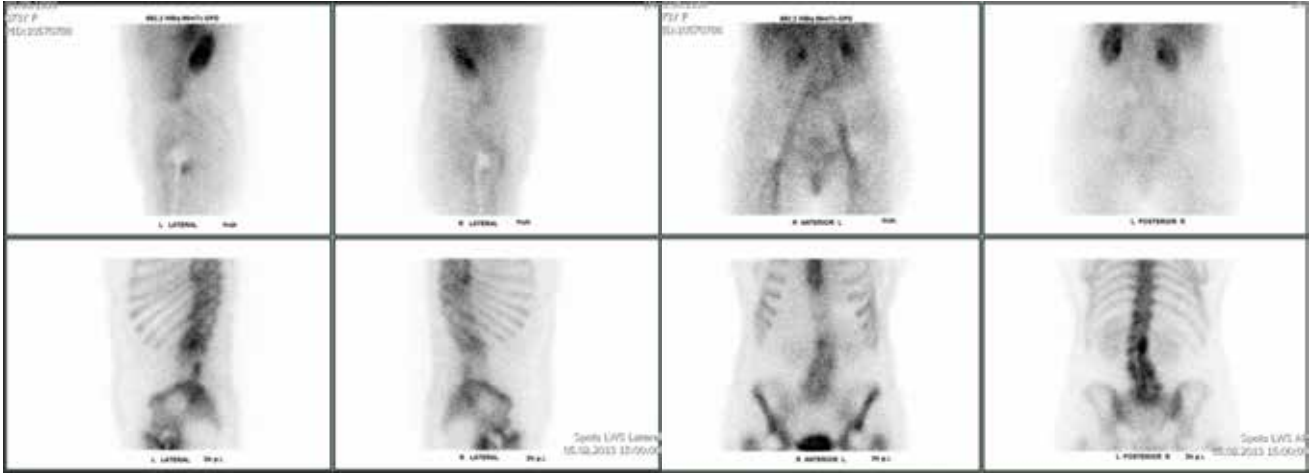
Planar bone scan (A): Shows diffuse metabolic uptake of the whole lateral lumbar spine.

SPECT/CT (B): Shows significant osteoarthritic changes on CT (1, 2, 3A, 4A) with uptake in multiple facet joints (3B, 4B) superior to the current spondylodesis (5, overview volume rendering technique). There is no implant loosening, nor metabolic uptake that can be seen in both ISJ. The rib cage is unremarkable. In addition, there was osteochondrosis and supportive bone formation of Th12/L1 on both sides.

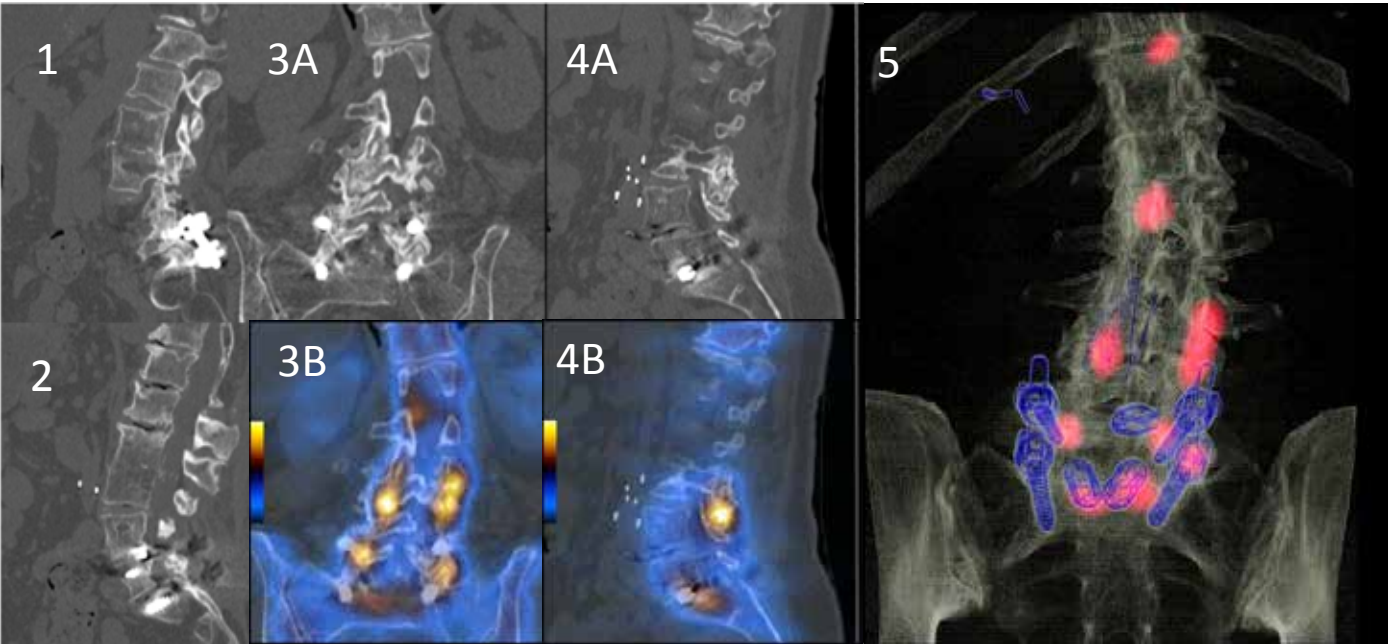Outcome and teaching point

No additional surgery. Instead local infiltration therapy. No further imaging follow-up so far.

Note the typical pattern of osteoarthritis adjacent to spondylodesis based on the altered mechanical movement.



(A)



(B)

4.8. CASE No. LS 8

Study type:	Orthopaedics Degenerative		
Clinical indication:	Pain after kyphoplasty Progressive kyphosis		
Keywords:	Kyphosis Kyphoplasty		
SPECT/CT system:	General Electric Discovery 670	Tracer:	^{99m}Tc -DPD
Uptake:	180 min	Dose:	659 MBq
Tube loading:	120–400 mAs	Tube voltage:	120 kVp

Short clinical history

A 75 year old female patient with s/p osteoporotic vertebral fractures and kyphoplasty. The patient had progressive kyphosis and also presented radicular symptoms. Investigated for additional fractures. MRI (A) was inconclusive due to inferior image quality.

Findings

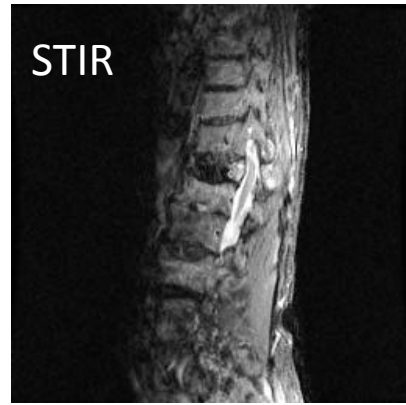
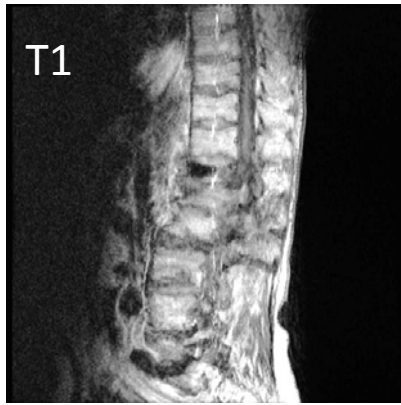Planar bone scan (B): Shows diffuse uptake of the lumbar spine and increased uptake in Th12.

SPECT/CT (C): Shows significant uptake indicative of a recent infraction in Th12.

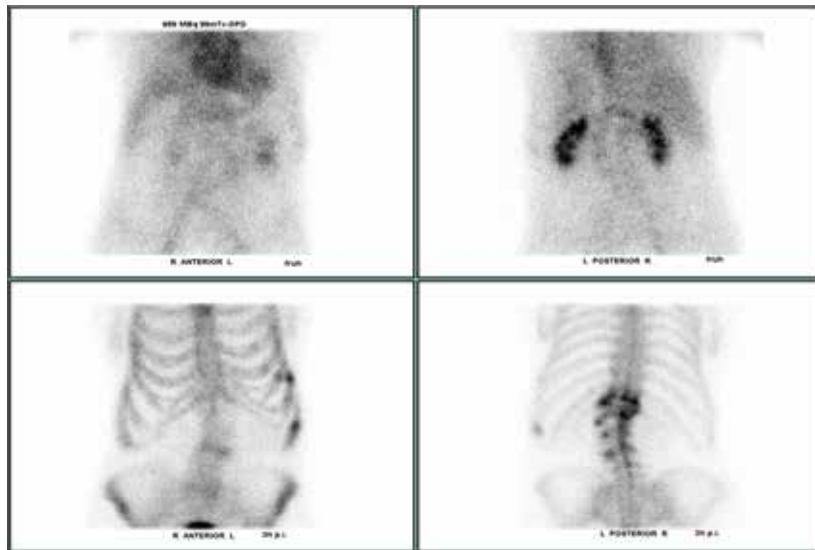
Outcome and teaching point

Additional kyphoplasty for the prevention of further compression fraction and spinal injuries was performed.

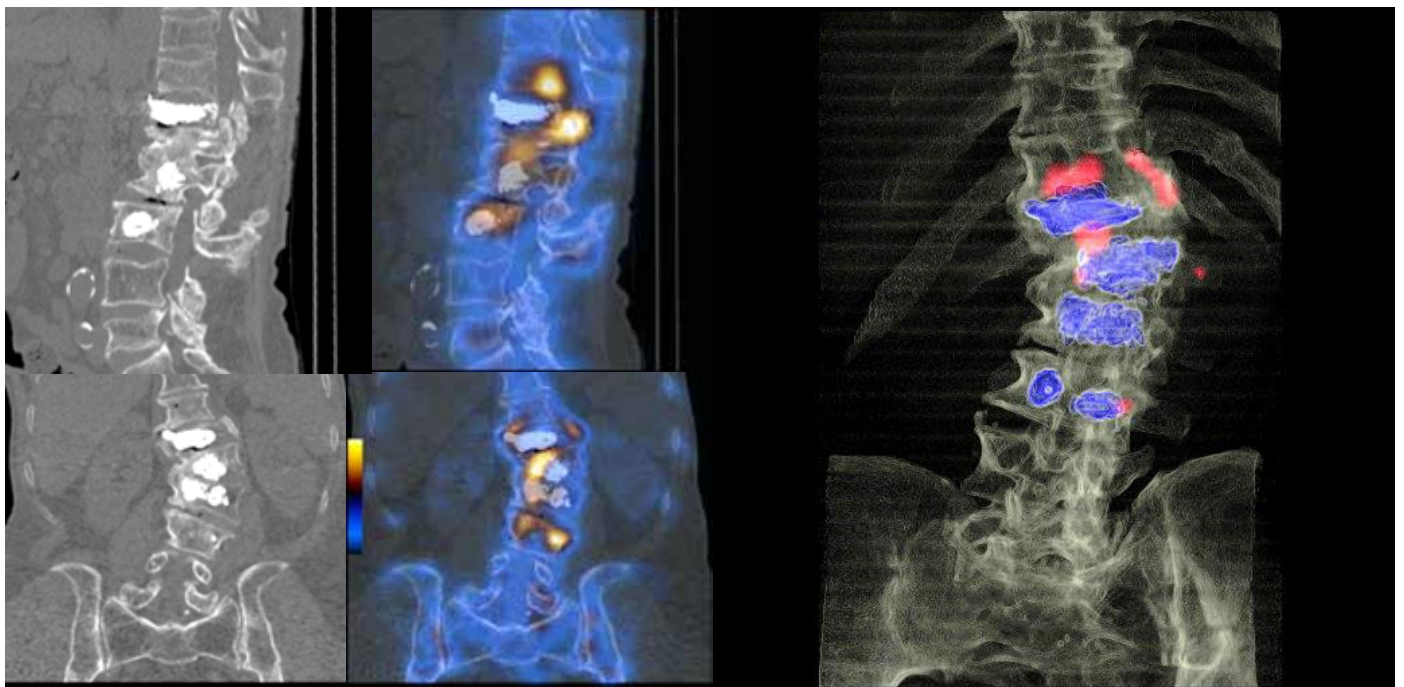
Note that the metabolic information of the SPECT/CT represents the active part with elevated bone metabolism compared to the anatomical changes which cannot show the areas with elevated metabolism.



(A)



(B)



(C)

4.9. CASE No. LS 9

Study type:	Infection Oncology		
Clinical indication:	Spondylodiscitis Pain in the whole spine Prostate cancer		
Keywords:	Spondylodiscitis Prostate cancer		
SPECT/CT system:	General Electric Discovery 670	Tracer:	^{99m}Tc -DPD
Uptake:	180 min	Dose:	679 MBq
Tube loading:	120–400 mAs	Tube voltage:	120 kVp

Short clinical history

A 61 year old male patient diagnosed with spondylodiscitis 2 months earlier, currently complaining of exacerbated pain in the whole spine. The patient had been diagnosed with prostate cancer 2 years earlier and underwent radical prostatectomy.

Findings

Planar bone scan (A, early and late phase): Shows increased uptake in T6/7 based on the known spondylodiscitis. No signs of distant bone metastases.

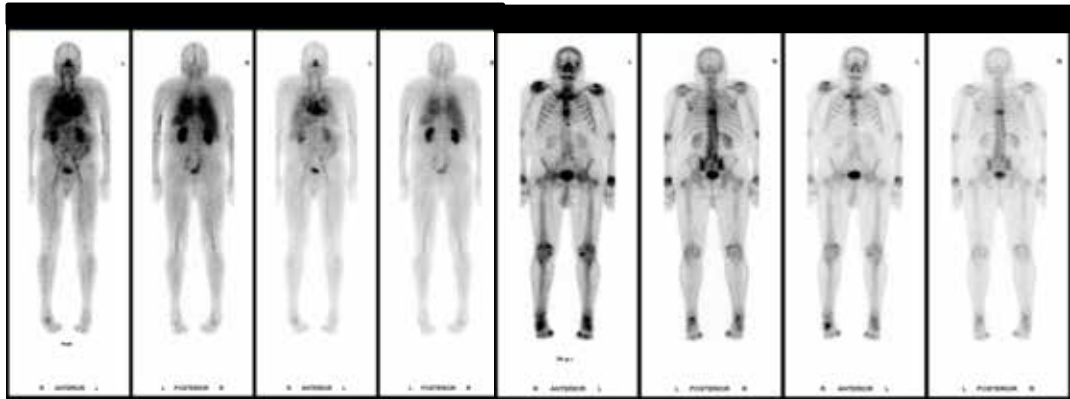The MRI (B): Shows the oedema and the small residual pre-vertebral abscess in the same segment.

The SPECT/CT (C): Shows uptake within the thoracic vertebra, (lower plate of T6 and upper plate of T7) with CT morphologic signs of an older infection. No evidence of osteolysis or fracture.

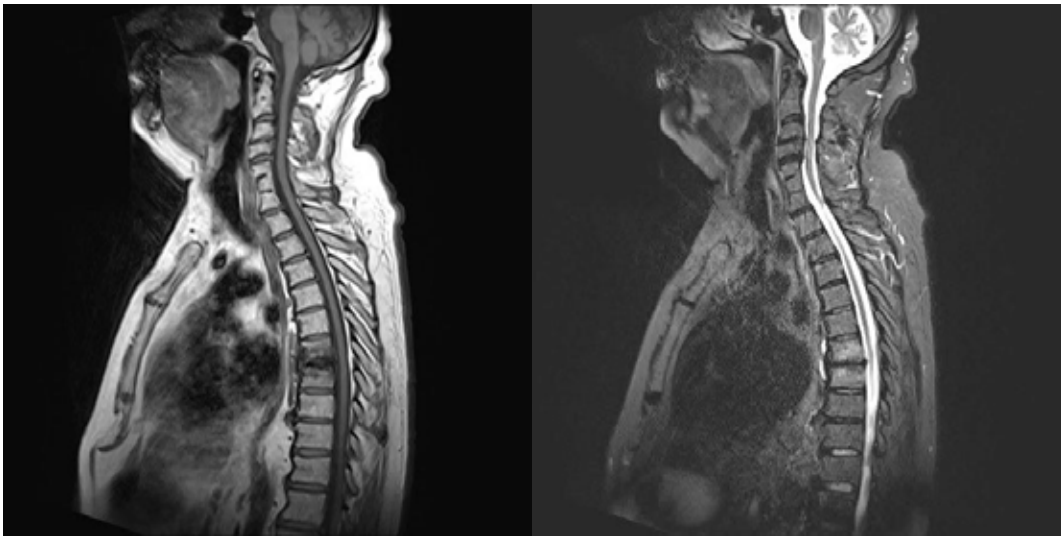
Outcome and teaching point

Exclusion of bone metastases. Supportive pain management was provided with continuation of anti-infective therapy.

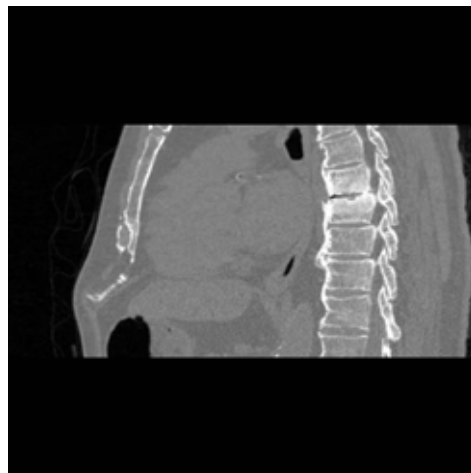
Note the elevated uptake in this segment of the thoracic spine already on the whole body early planar bone scan. Also note the sclerotic changes on the CT component indicative of an older infectious focus.



(A)



(B)



(C)

4.10. CASE No. LS 10

Study type:	Oncology		
Clinical indication:	New pulmonary metastases Ongoing pain in the right pelvis after extensive surgery 3 years earlier		
Keywords:	Screw loosening Metastases		
SPECT/CT system:	General Electric Discovery 670	Tracer:	^{99m}Tc -DPD
Uptake:	180 min	Dose:	669 MBq
Tube loading:	120–400 mAs	Tube voltage:	120 kVp

Short clinical history

A 28 year old male patient with s/p hemipelvectomy due to Ewing's Sarcoma 3 years earlier. The patient is currently presenting new pulmonary metastases. Checking for additional bone metastases. S/p neo-adjuvant as well as adjuvant chemotherapy, hemipelvectomy and radiotherapy.

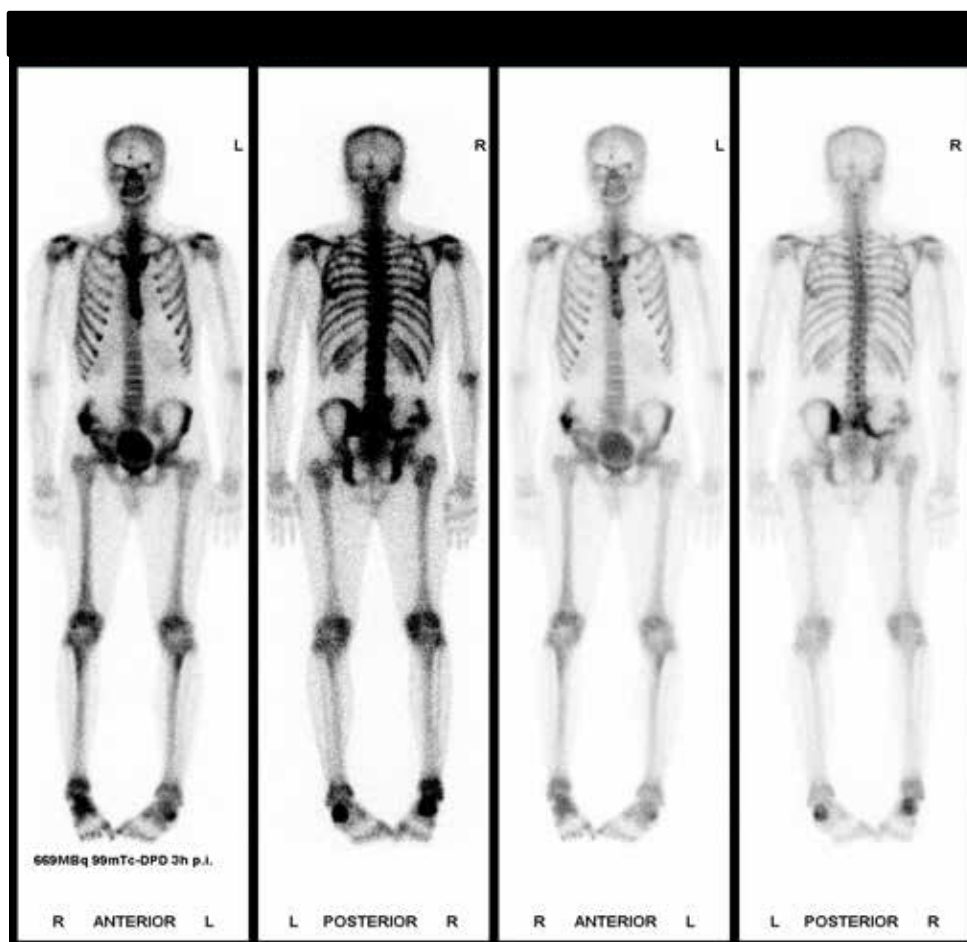
Findings

Planar bone scan (A): Shows elevated uptake in the right anterior and posterior pelvis as well as in the left ISJ. No sign of additional bone metastases.

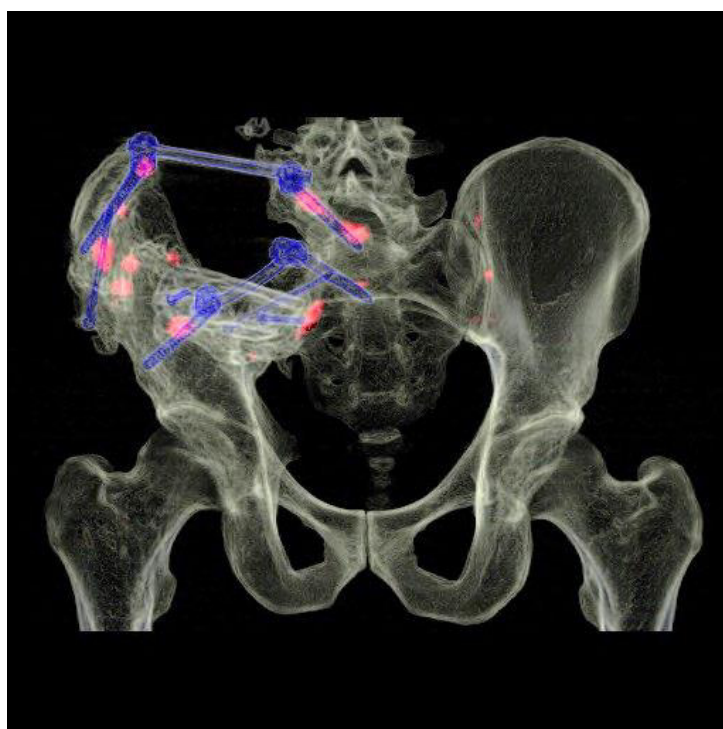
The SPECT/CT (B): Shows a loosened screw in the right L5. There is increased uptake directly around the screw. The corresponding elevated uptake indicates loosening as well.

Outcome

The patient was treated with chemotherapy and pulmonary wedge resection.



(A)



(B)

5. PELVIS AND HIP

5.1. CASE No. PH 1

Study type:	Rheumatology Degenerative		
Clinical indication:	Lower back pain		
Keywords:	Facet joint Sacroiliitis		
SPECT/CT system:	Siemens Symbia T6	Tracer:	^{99m}Tc -DPD
Uptake:	240 min	Dose:	712 MBq
Tube loading:	188 mAs	Tube voltage:	130 kVp

Short clinical history

A 61 year old male patient with lower back pain, psoriasis and a history of testicular cancer.

Findings

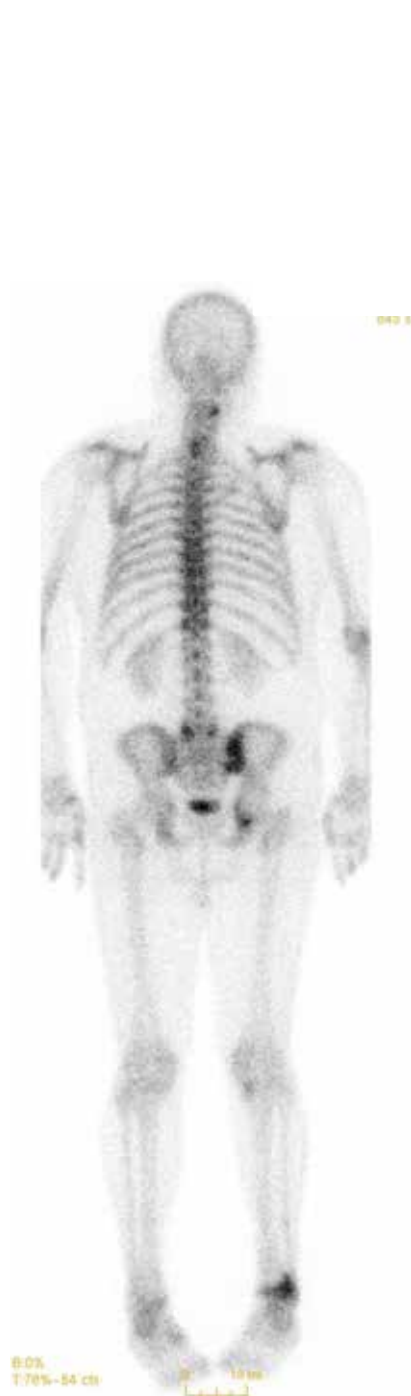Planar whole body images (A): Shows increased uptake in the right ISJ and in the facet joints L5/S1 (in addition to post-traumatic changes in the right ankle and degenerative changes in the cervical and thoracic spine).

SPECT/CT (B, C): Shows normal aspect of the ISJs on CT, consistent with early sacroiliitis (B) and facet joint osteoarthritis L5/S1 predominantly in the left joint (C).

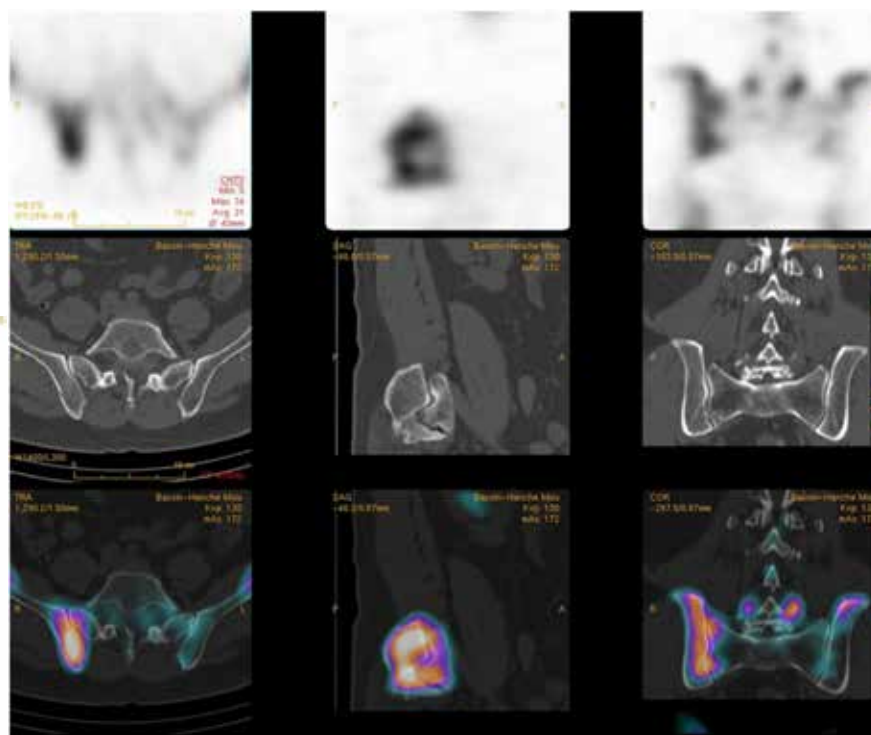
Outcome and teaching point

The patient was treated with ledertrexate, followed by left facet joint injection.

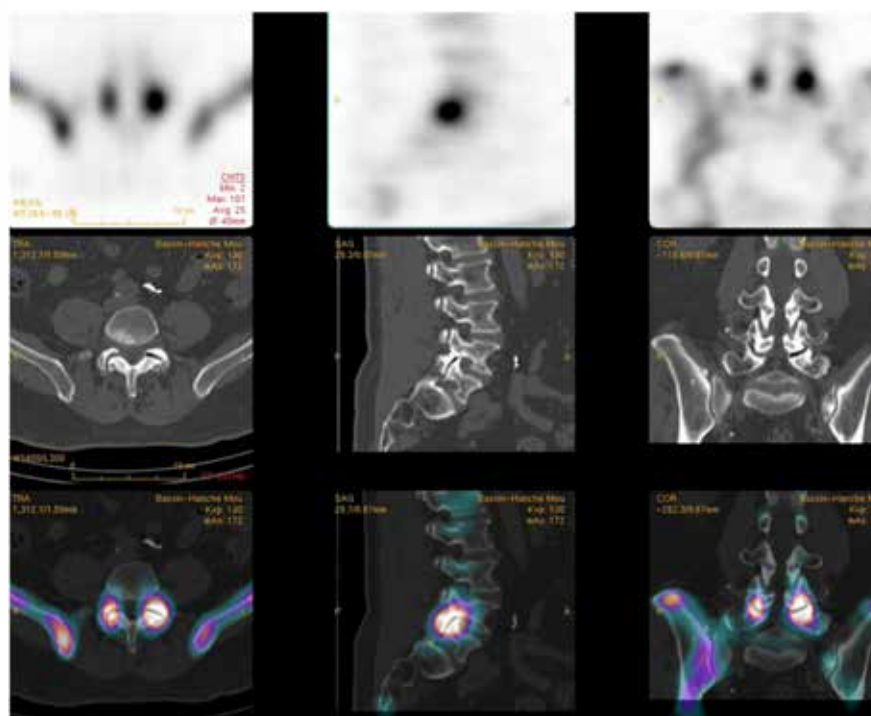
Metabolic changes precede morphologic changes associated with sacroiliitis.



(A)



(B)



(C)

5.2. CASE No. PH 2

Study type:	Orthopaedics		
Clinical indication:	Hip pain		
Keywords:	Hip prosthesis Loosening		
SPECT/CT system:	Siemens Symbia T6	Tracer:	^{99m}Tc -DPD
Uptake:	240 min	Dose:	760 MBq
Tube loading:	246 mAs	Tube voltage:	130 kVp

Short clinical history

A 64 year old female patient with bilateral hip prosthesis (left side in 2000, right side in 2004). The patient complained of chronic pain in the right hip, progressing over the past few months. There was no history of trauma.

Findings

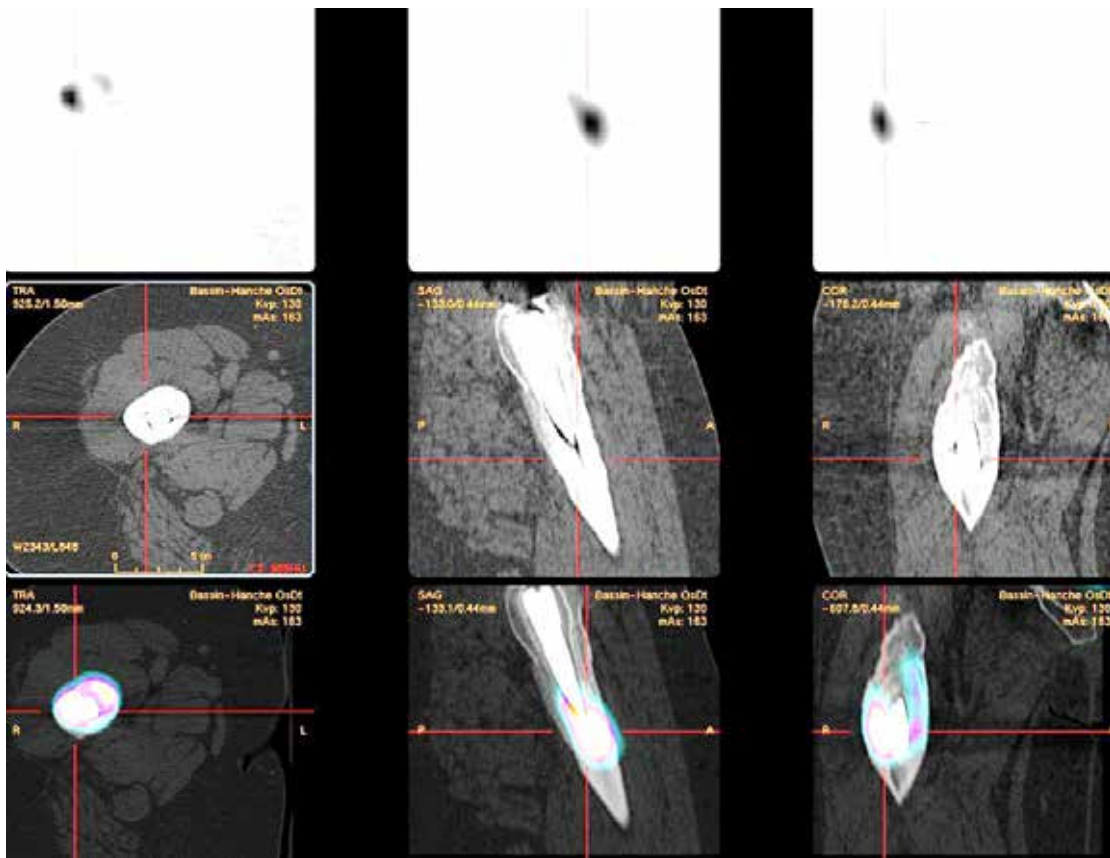
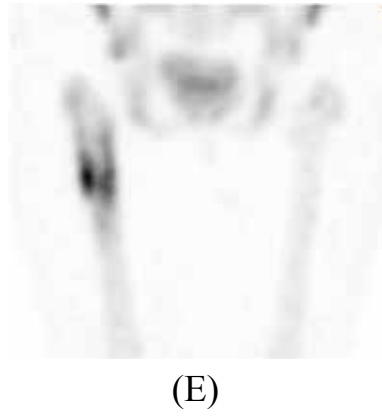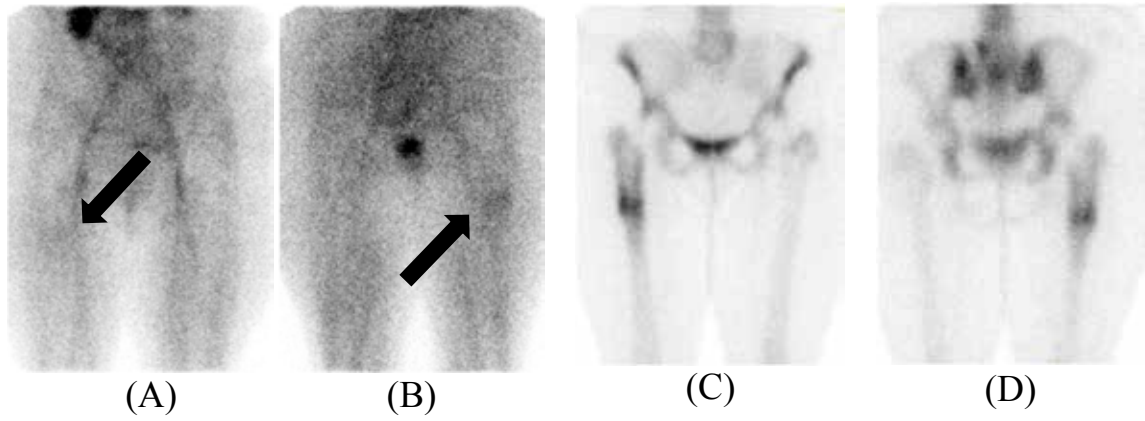
Planar blood pool (A, B: anterior and posterior views): Shows increased activity at the femoral tip of the prosthesis (arrows).

Late planar images and SPECT (C, D: anterior and posterior views, E: MIP): Shows focus of increased uptake in the same area. CT shows cortical thickening but there is no sign suggesting infection.

SPECT/CT (F): Shows that the results are consistent with aseptic loosening.

Outcome

Surgery was performed and confirmed aseptic loosening.



5.3. CASE No. PH 3

Study type:	Traumatology		
Clinical indication:	Pelvic pain		
Keywords:	Fracture		
SPECT/CT system:	Siemens Symbia T6	Tracer:	^{99m}Tc -DPD
Uptake:	240 min	Dose:	736 MBq
Tube loading:	157 mAs	Tube voltage:	130 kVp

Short clinical history

A 44 year old female patient with painful pelvic girdle, poorly localized, irradiated to the hips. The patient had slipped and fallen on ice 2 weeks earlier.

Findings

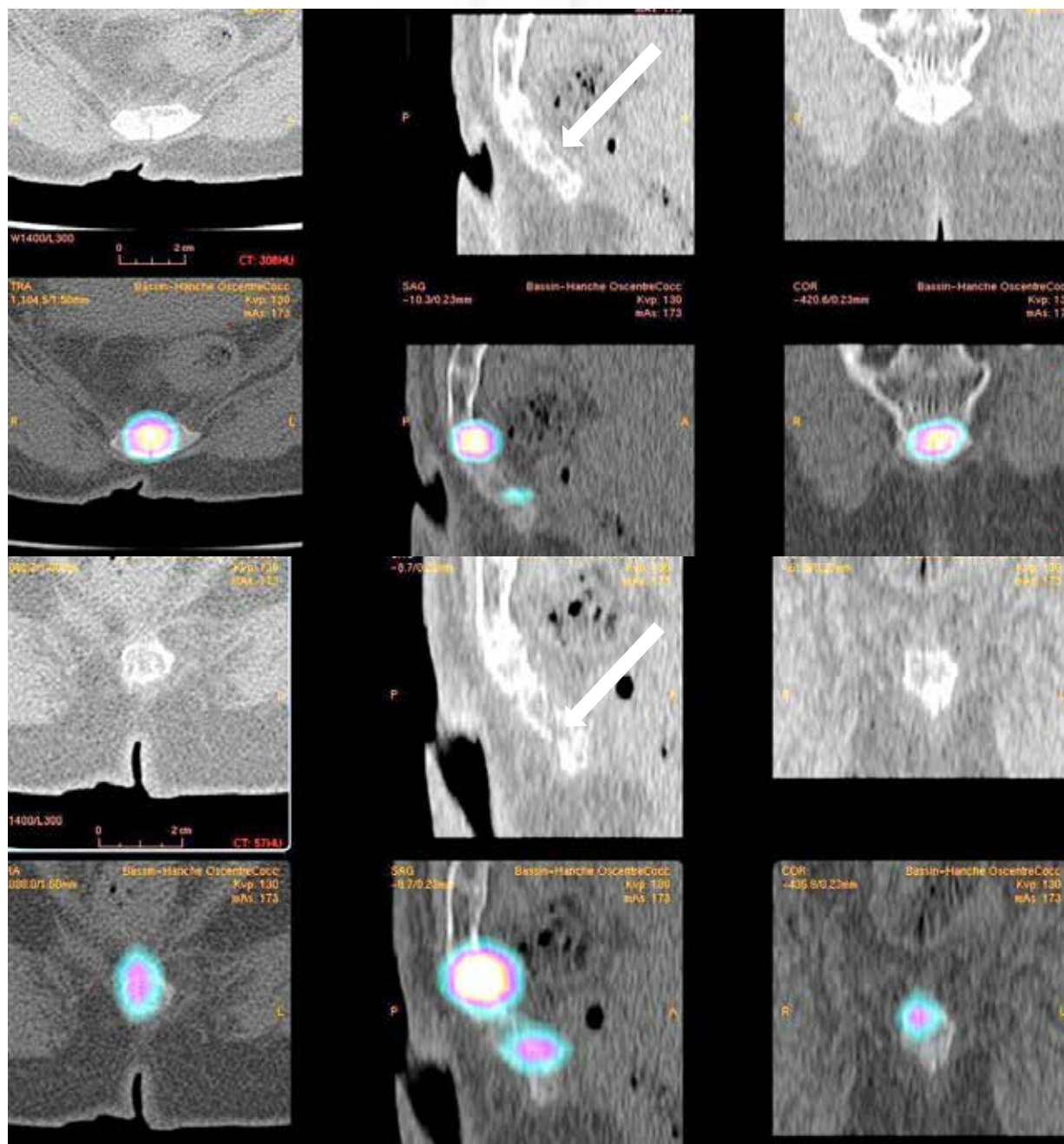
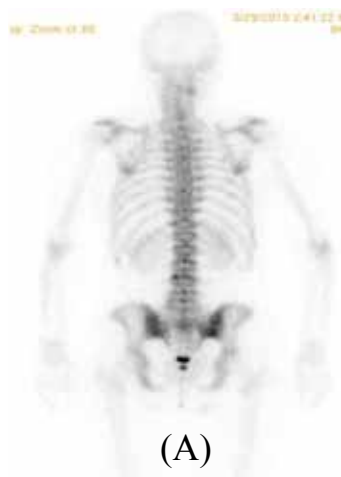Planar image (A: posterior view): Shows two foci of uptake over the coccyx.

SPECT/CT (B): Shows non-displaced fractures of the 1st and 2nd coccygeal vertebrae (arrows).

Outcome and teaching point

Conservative treatment.

Note since the CT anomalies are not very obvious, the scintigraphy and SPECT study provide an easier diagnosis.



5.4. CASE No. PH 4

Study type:	Degenerative		
Clinical indication:	Hip pain		
Keywords:	Coxarthrosis		
SPECT/CT system:	Siemens Symbia T6	Tracer:	^{99m}Tc -DPD
Uptake:	240 min	Dose:	704 MBq
Tube loading:	212 mAs	Tube voltage:	130 kVp

Short clinical history

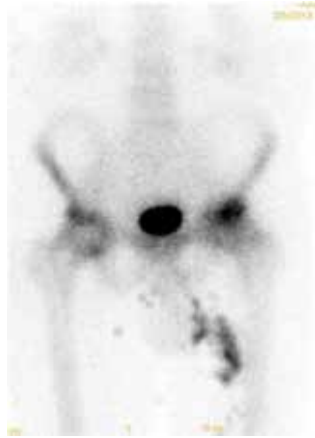A 65 year old male patient with a history of facet joint syndrome treated with radiofrequency thermocoagulation. The patient complained of bilateral hip pain.

Findings

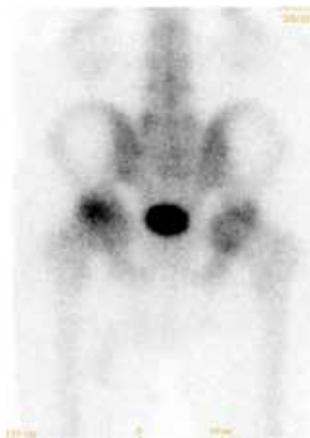Planer images (A, B) and SPECT/CT: Show severe bilateral coxarthrosis, more active on the left (C) than on the right hip (D).

Outcome

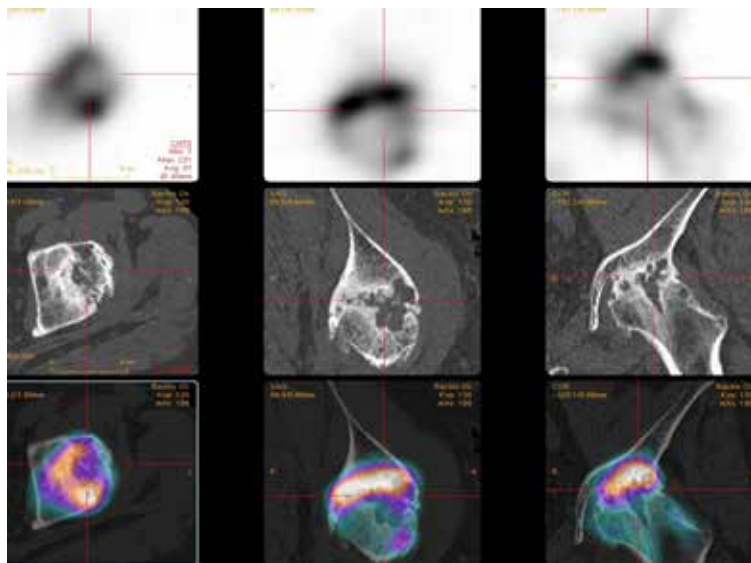
Conservative treatment. The patient refused surgery.



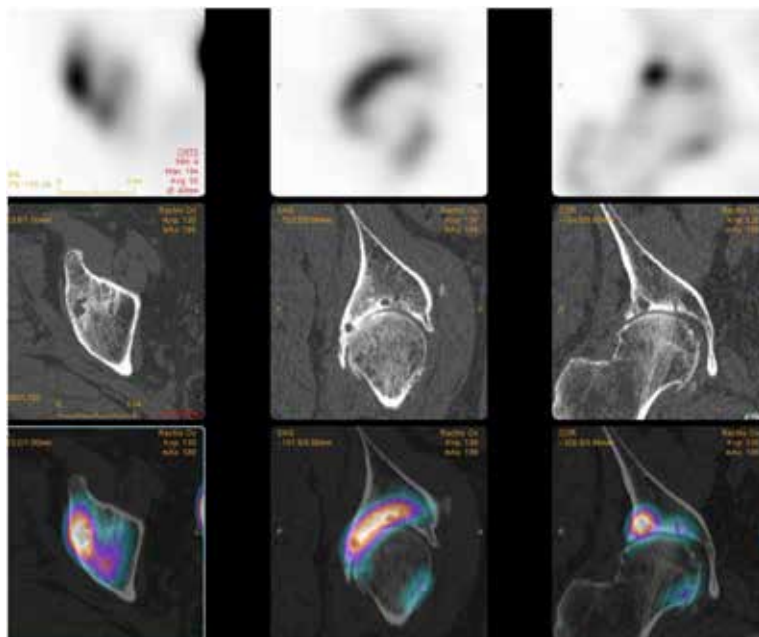
(A)



(B)



(C)



(D)

5.5. CASE No. PH 5

Study type:	Degenerative		
Clinical indication:	Hip pain		
Keywords:	Hip osteoarthritis		
SPECT/CT system:	Siemens Symbia T6	Tracer:	^{99m}Tc -DPD
Uptake:	240 min	Dose:	747 MBq
Tube loading:	238 mAs	Tube voltage:	130 kVp

Short clinical history

A 56 year old female patient with right coxalgia irradiated towards the anterior thigh. The patient had no history of trauma.

Findings

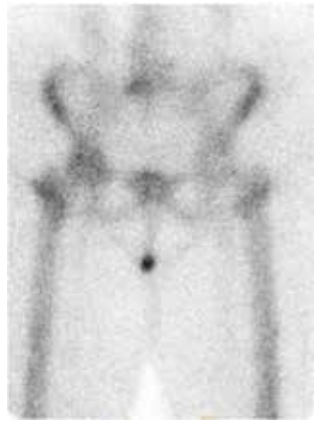
Planar images (A, B): Show degenerative changes L3/4, L5/S1 and slightly increased uptake by the right hip.

SPECT/CT (C): Shows absence of CT anomaly corresponding to the increased uptake in the right femoral head.

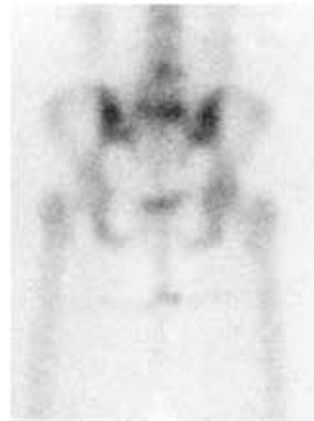The findings are consistent with osteoarthritis of the hip, initial stage.

Teaching point

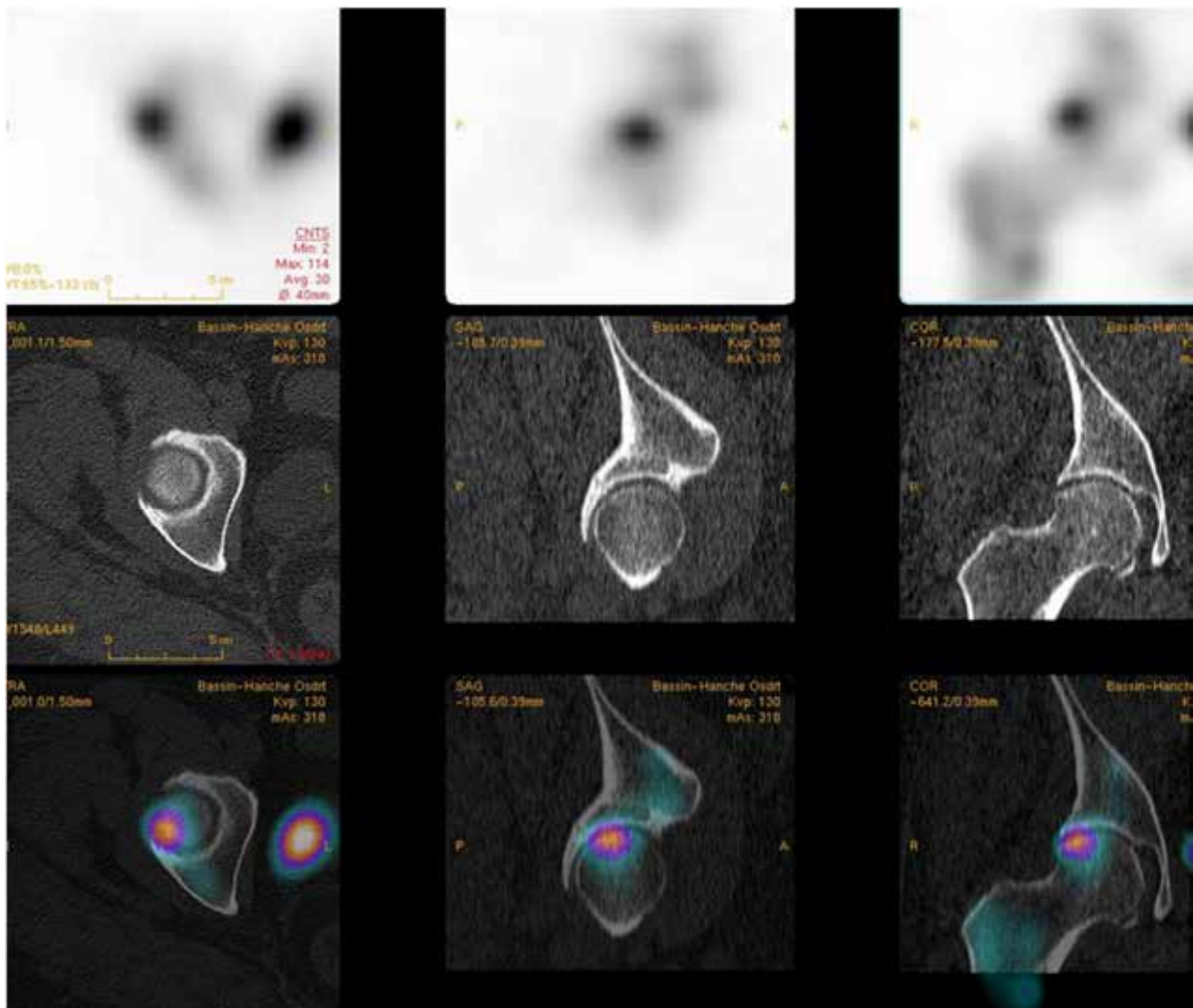
Metabolic changes are visible earlier than the morphologic changes.



(A)



(B)



(C)

5.6. CASE No. PH 6

Study type:	Orthopaedic		
Clinical indication:	Coxarthrosis		
Keywords:	Osteoarthritis		
SPECT/CT system:	Siemens Symbia T2	Tracer:	^{99m}Tc -DPD
Uptake:	5 and 160 min	Dose:	533 MBq
Tube loading:	120 mAs	Tube voltage:	80 kVp

Short clinical history

An 82 year old female patient with arthralgia in multiple joints and greatest intensity in the right hip. Bone scintigraphy was performed to verify medical indication for radiosynoviorthesis.

Findings

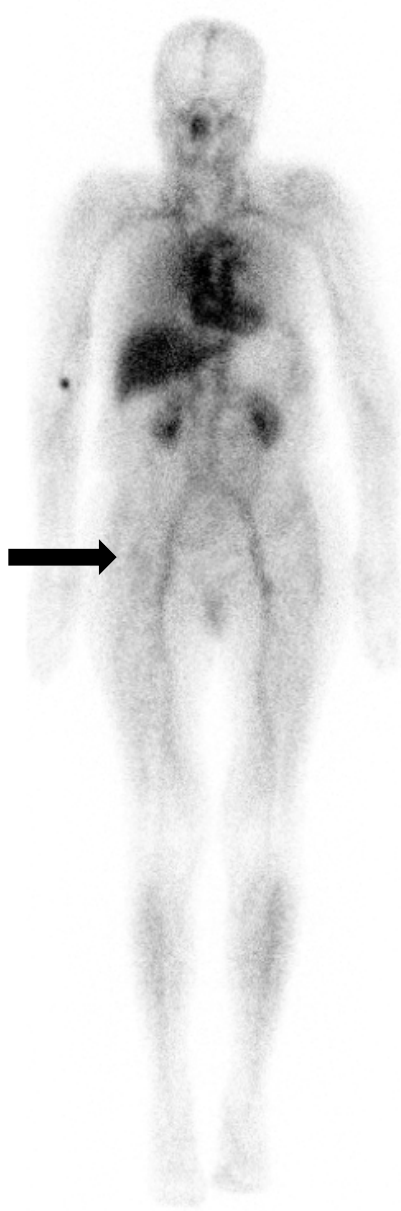
Planar images of blood pool (A): Shows focal uptake in the region of the right hip (arrow) representing synovialitis.

Planar image of mineralization (B): Shows intense uptake in the right hip (arrow). Furthermore, whole body scintigraphy shows polyarthrosis.

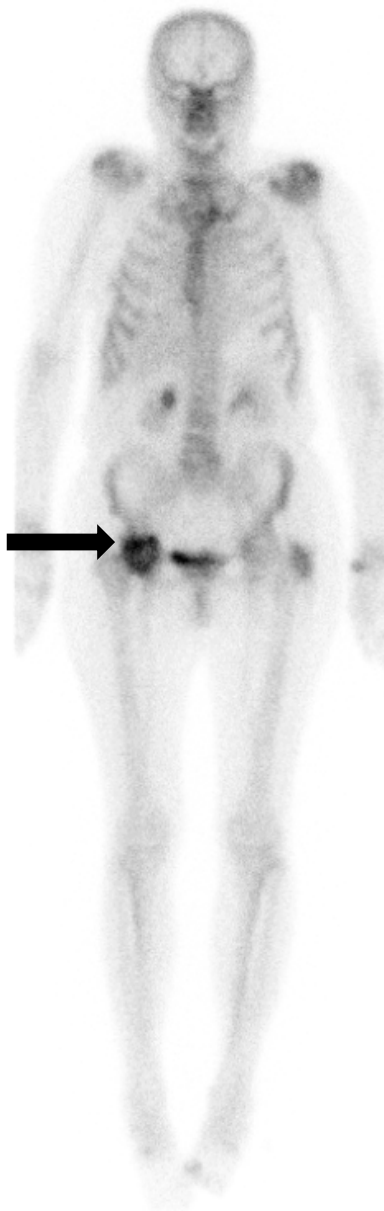SPECT/CT (C): Shows massive coxarthrosis with deformation of the femoral head.

Outcome

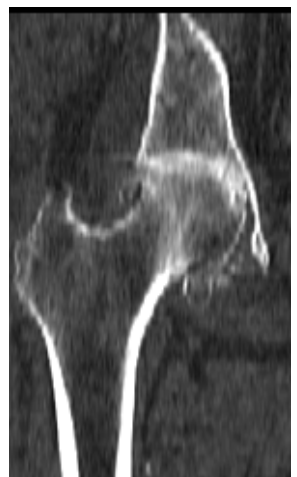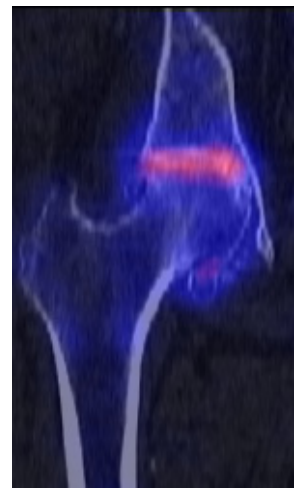
The patient refused joint replacement. Radiosynoviorthesis of the right hip was performed using 185 MBq ^{90}Y -citrate. In the follow-up 6 months later, the patient reported a decrease in pain (60% on the visual analogue scale).



(A)



(B)



(C)

5.7. CASE No. PH 7

Study type:	Orthopaedic		
Clinical indication:	Coxarthrosis		
Keywords:	Sclerosing tendopathy		
SPECT/CT system:	Siemens Symbia T2	Tracer:	^{99m}Tc -DPD
Uptake:	180 min	Dose:	501 MBq
Tube loading:	120 mAs	Tube voltage:	80 kVp

Short clinical history

A 68 year old female patient complained of permanent pain in both hips.

Findings

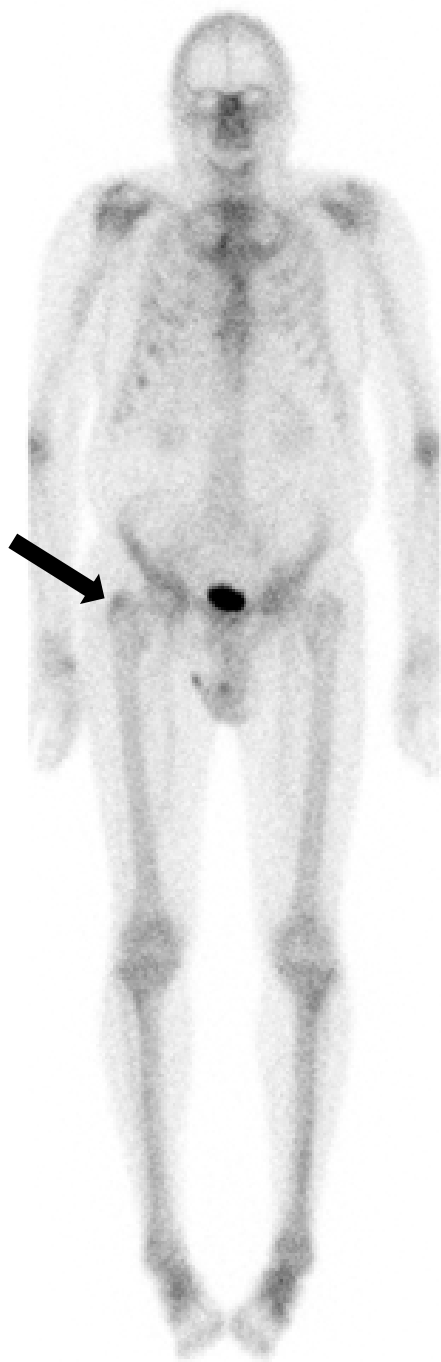Planar image (A): Shows slightly increased tracer uptake in both hips being more prominent in the trochanter region (arrow).

SPECT/CT (B): Shows massive coxarthrosis and a focal uptake in irregular cortical bone at the greater trochanter with additional ossification within the tendon (arrows) representing a sclerosing tendinopathy.

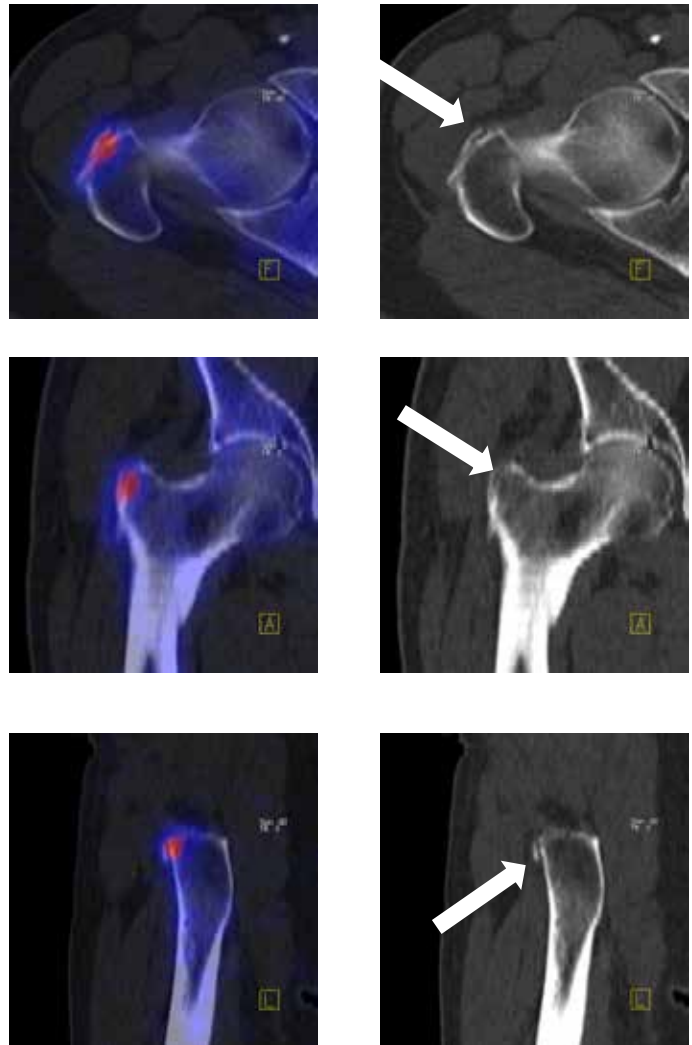
Outcome and teaching point

Conservative therapy.

Note SPECT/CT can differentiate between bursitis and sclerosing tendinopathy.



(A)



(B)

5.8. CASE No. PH 8

Study type:	Orthopaedics Degenerative		
Clinical indication:	Inconclusive MRI of the lumbar spine Integration of implant		
Keywords:	Pain Implants		
SPECT/CT system:	General Electric Discovery 670	Tracer:	^{99m} Tc-DPD
Uptake:	180 min	Dose:	635 MBq
Tube loading:	120–400 mAs	Tube voltage:	120 kVp

Short clinical history

A 60 year old female patient with ISJ arthropathy and consecutive iFuse arthrodesis in the left ISJ. Continuous lower back pain 8 months after surgery. MRI of the lumbar spine was reported with non-active osteochondrosis (Modic II). Clinical question for implant integration.

Findings

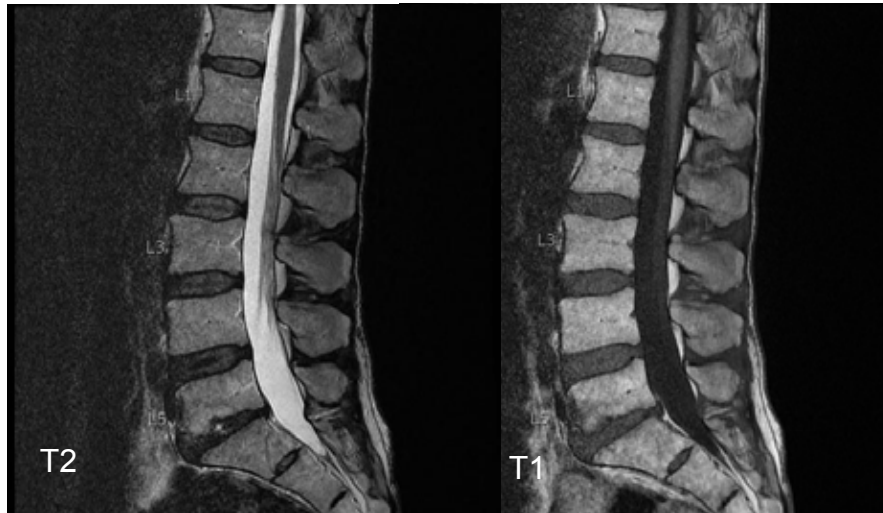MRI (A): Shows only slight bone oedema.

Planar bone scan (B): Shows elevated uptake in segment L5/S1.

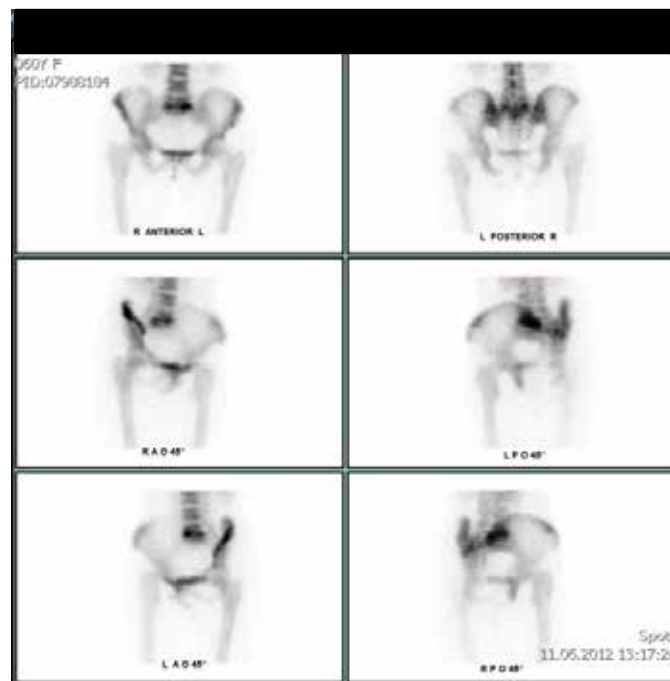
SPECT/CT (C): Shows active osteochondrosis in L5/S1 but no uptake at the arthrodesis — meaning full integration of the implant and overruling of the MRI report.

Outcome

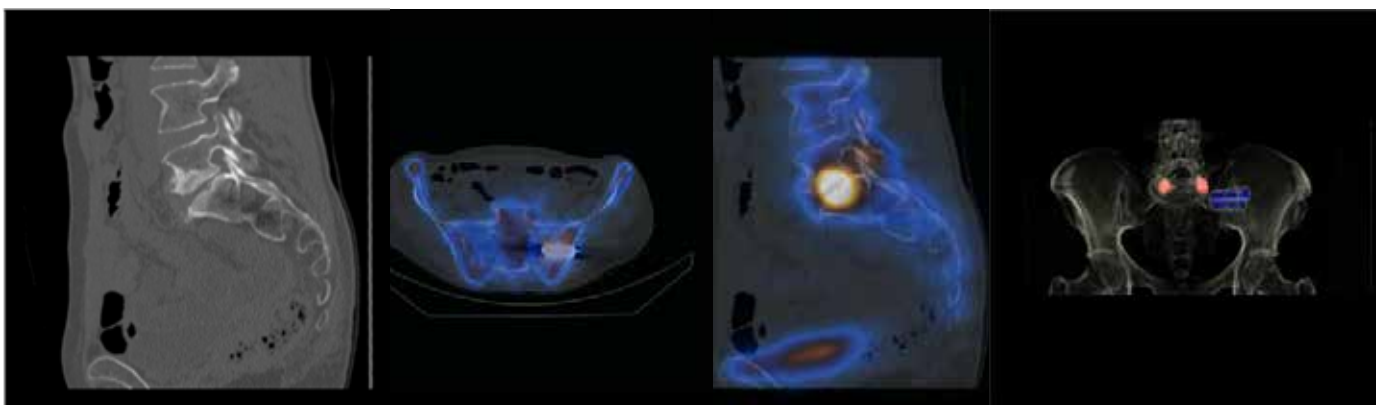
The ISJ implant is fully integrated and there is no need for removal or additional surgery concerning the implanted ISJ device. Change in treatment plan; treatment for activated osteochondrosis.



(A)



(B)



(C)

5.9. CASE No. PH 9

Study type:	Orthopaedics Degenerative		
Clinical indication:	Persistent pain post hip prosthesis Suspected loosening of screw		
Keywords:	Pain Prosthesis		
SPECT/CT system:	General Electric Discovery 670	Tracer:	^{99m}Tc -DPD
Uptake:	180 min	Dose:	650 MBq
Tube loading:	120–400 mAs	Tube voltage:	120 kVp

Short clinical history

A 75 year old female patient with s/p right-sided hip prosthesis 18 months earlier due to a multifragment proximal femoral fracture. Additional periprosthetic fracture and consecutive re-surgery with wire fixation. Persistent pain, clinical question for loosening of the prosthesis.

Findings

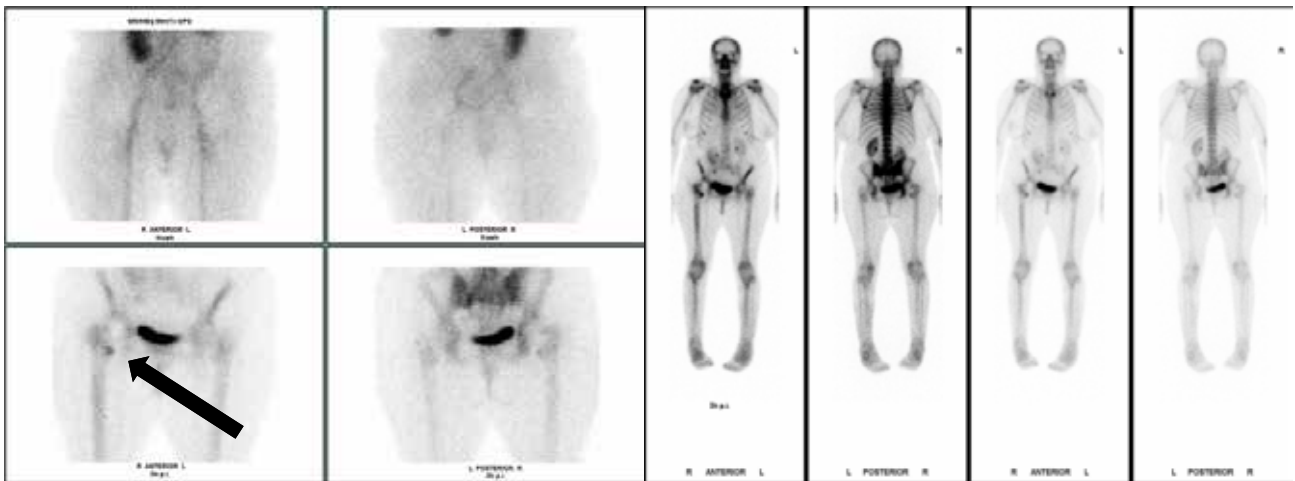
Planar bone scan (A): Shows focal uptake at the trochanter minor (arrow), indicating some loosening.

SPECT/CT (B): Shows significant focal uptake at the trochanter minor owing to heterotopic ossification with neo-articulation directly adjacent to the trochanter minor (arrow).

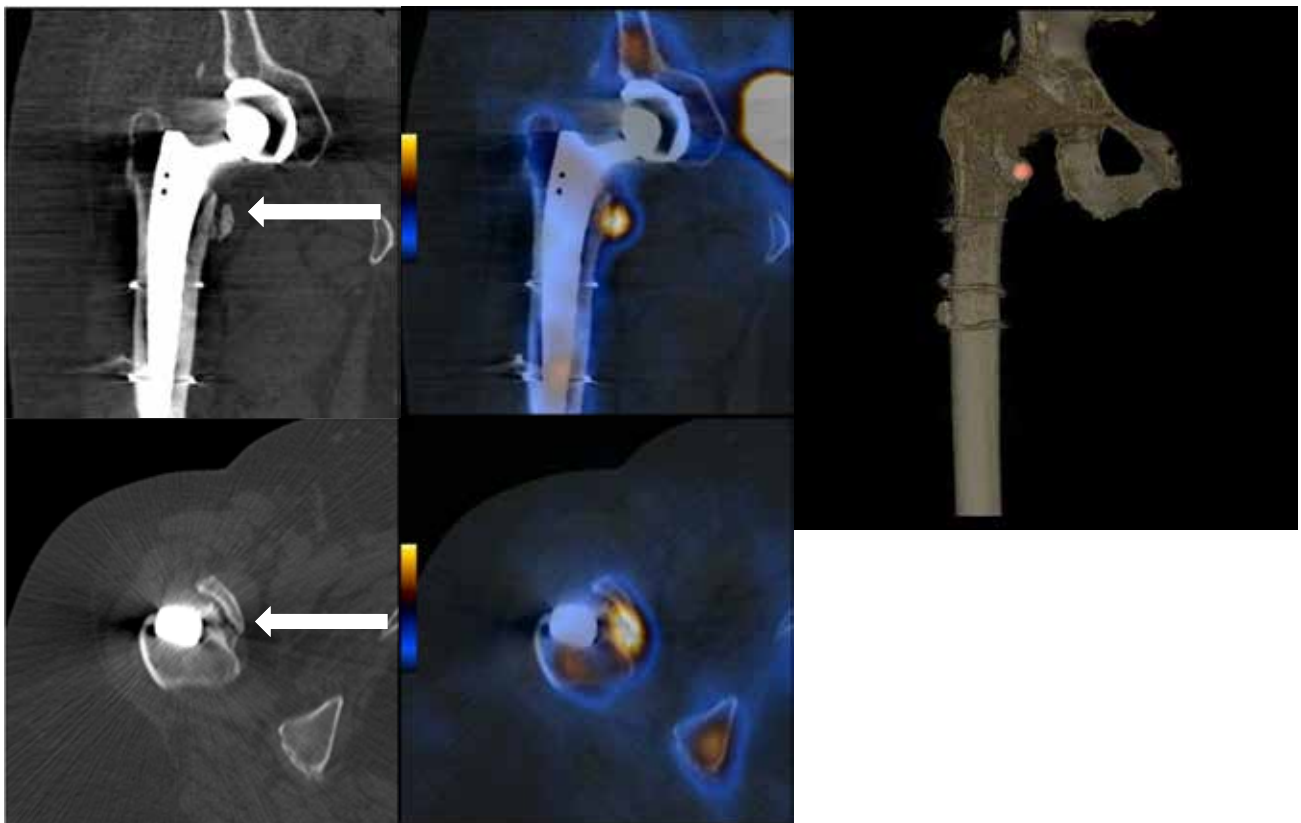
Outcome and teaching point

Partial, minimally invasive resection of the heterotopic ossification. No other follow-up.

Additional SPECT/CT can be helpful in selected, complex surgical cases.



(A)



(B)

5.10. CASE No. PH 10

Study type:	Orthopaedics Degenerative		
Clinical indication:	Ongoing pain after hip prosthesis implantation		
Keywords:	Pain Prosthesis		
SPECT/CT system:	General Electric Discovery 670	Tracer:	^{99m}Tc -DPD
Uptake:	180 min	Dose:	670 MBq
Tube loading:	120–400 mAs	Tube voltage:	120 kVp

Short clinical history

A 77 year old female patient with right-sided hip prosthesis for 2 years. The patient complained of constant lower back and hip pain.

Findings

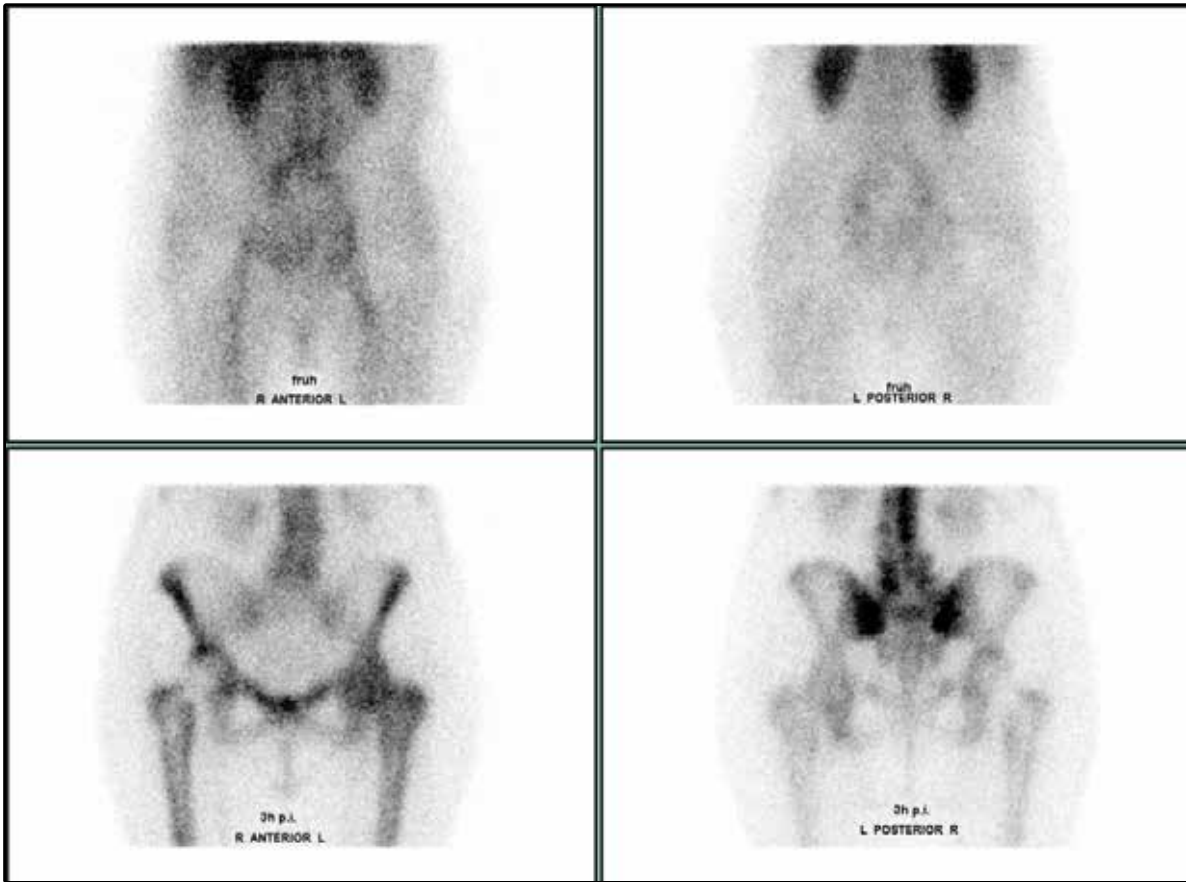
Planar bone scan (A): Shows increased uptake indicative of sacral insufficiency fractures on both sides.

SPECT/CT (B): Shows significant uptake on both sides of the sacrum with additional, non-dislocated fracture lines in CT (arrows). The right-sided hip prosthesis is unremarkable.

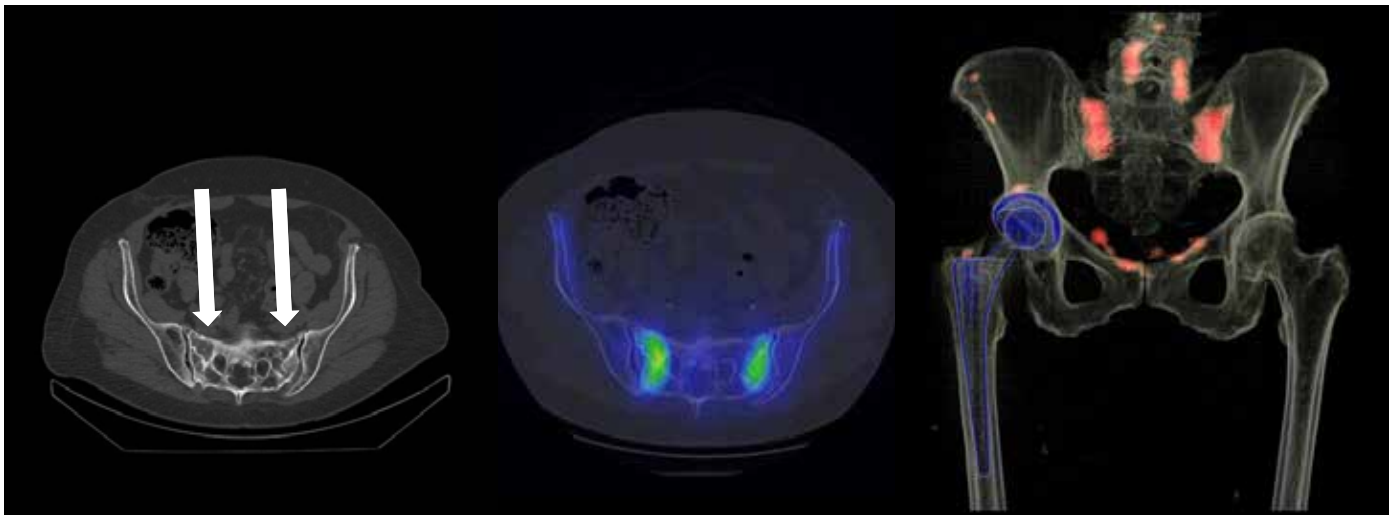
Outcome and teaching point

Conservative treatment and pain management. No further follow-up.

Note the classical appearance of a bilateral insufficiency sacral fracture (butterfly sign).



(A)



(B)

5.11. CASE No. PH 11

Study type:	Orthopaedics Degenerative		
Clinical indication:	Ongoing pain after hip prosthesis Suspected loosening of screw		
Keywords:	Pain Prosthesis		
SPECT/CT system:	General Electric Discovery 670	Tracer:	^{99m}Tc -DPD
Uptake:	180 min	Dose:	688 MBq
Tube loading:	120–400 mAs	Tube voltage:	120 kVp

Short clinical history

A 51 year old male patient with s/p left-sided hip prosthesis 18 months earlier. The patient complains of ongoing and persistent pain.

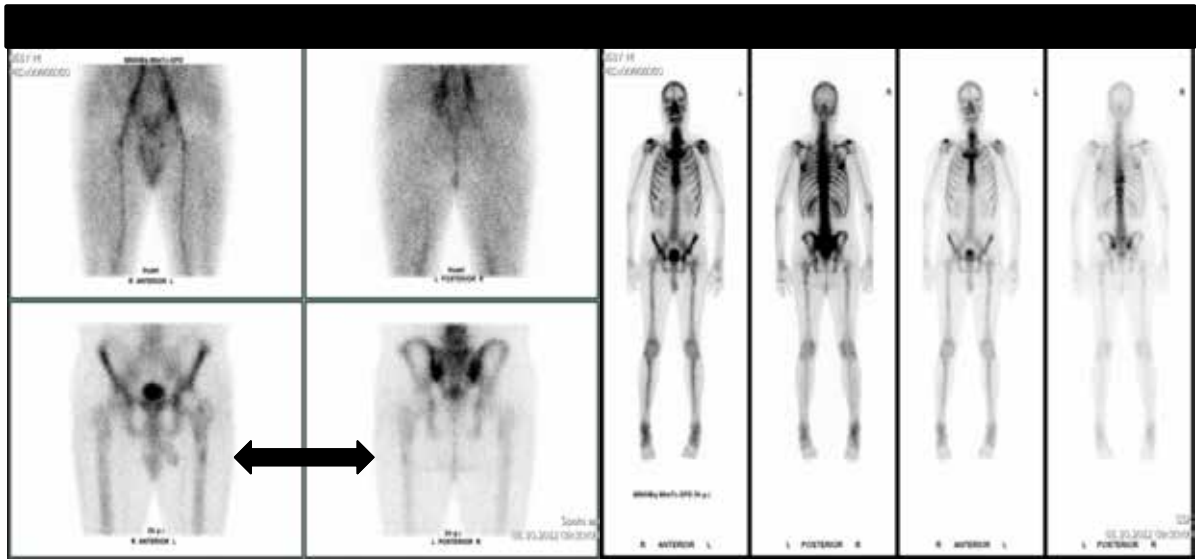
Findings

Planar bone scan (A): Shows only mild uptake at the tip of the femoral stem (arrow).

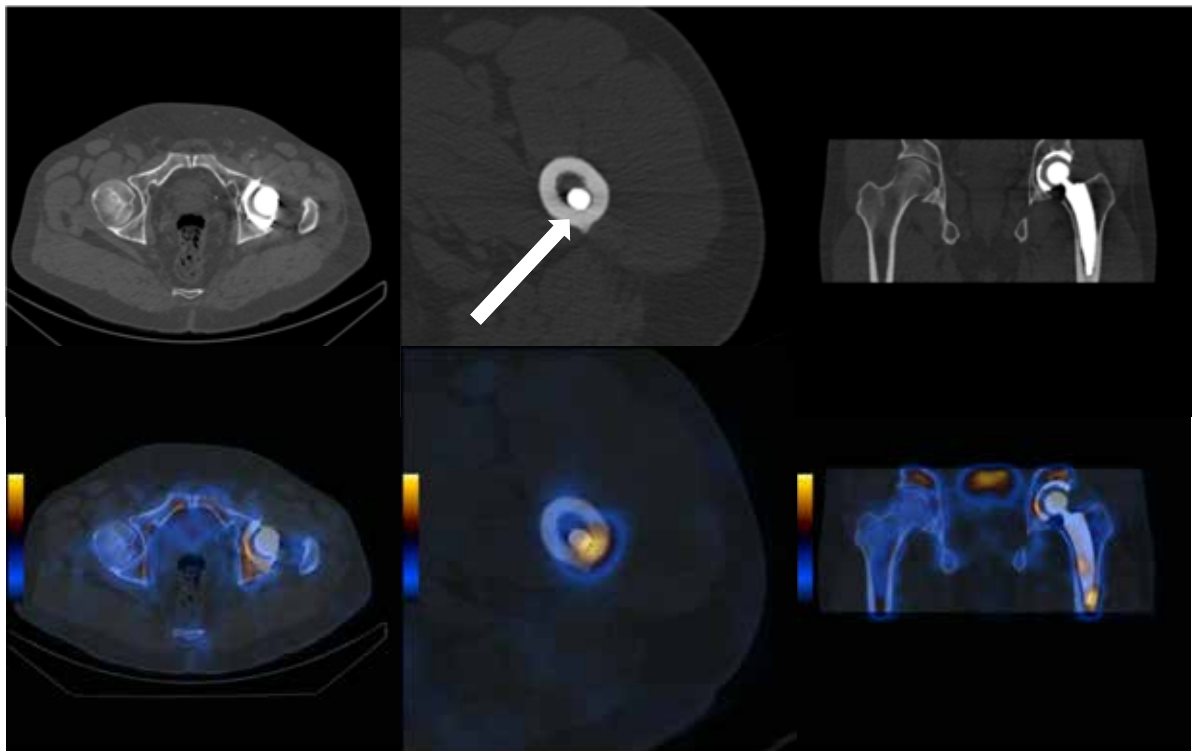
SPECT/CT (B): Shows significant focal uptake at the tip of the femoral stem. The stem is furthermore angled laterally (arrow) — indicative of loosening. There is no significant uptake around the acetabular cup.

Outcome

Conservative pain management. Change of prosthesis is scheduled when clinical situation is not manageable anymore. No further follow-up. The planar bone scan was inconclusive. Additional confirmatory information indicative for aseptic loosening was provided by the CT component.



(A)



(B)

5.12. CASE No. PH 12

Study type:	Orthopaedics Degenerative		
Clinical indication:	Hip pain		
Keywords:	Congenital dysplasia Exostosis Arthrosis		
SPECT/CT system:	Philips Precedence 16 slice	Tracer:	^{99m} Tc-HDP
Uptake:	120 min	Dose:	658 MBq
Tube loading:	120 mAs	Tube voltage:	120 kVp

Short clinical history

A 40 year old female patient with congenital dysplasia of the hip joints and exostosis. The patient complained of increasing pain in the right hip.

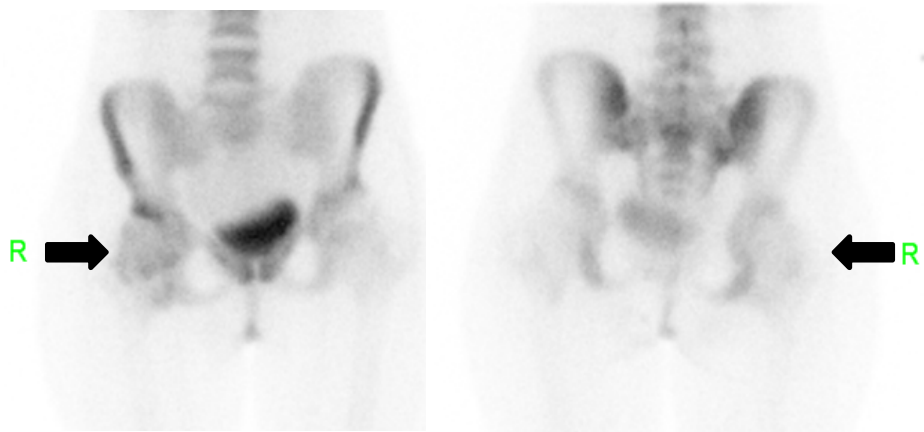
Findings

Planar bone scan (A): Shows asymmetry of the pelvis and diffusely increased bone metabolism in the right caput and collum femoris (arrows).

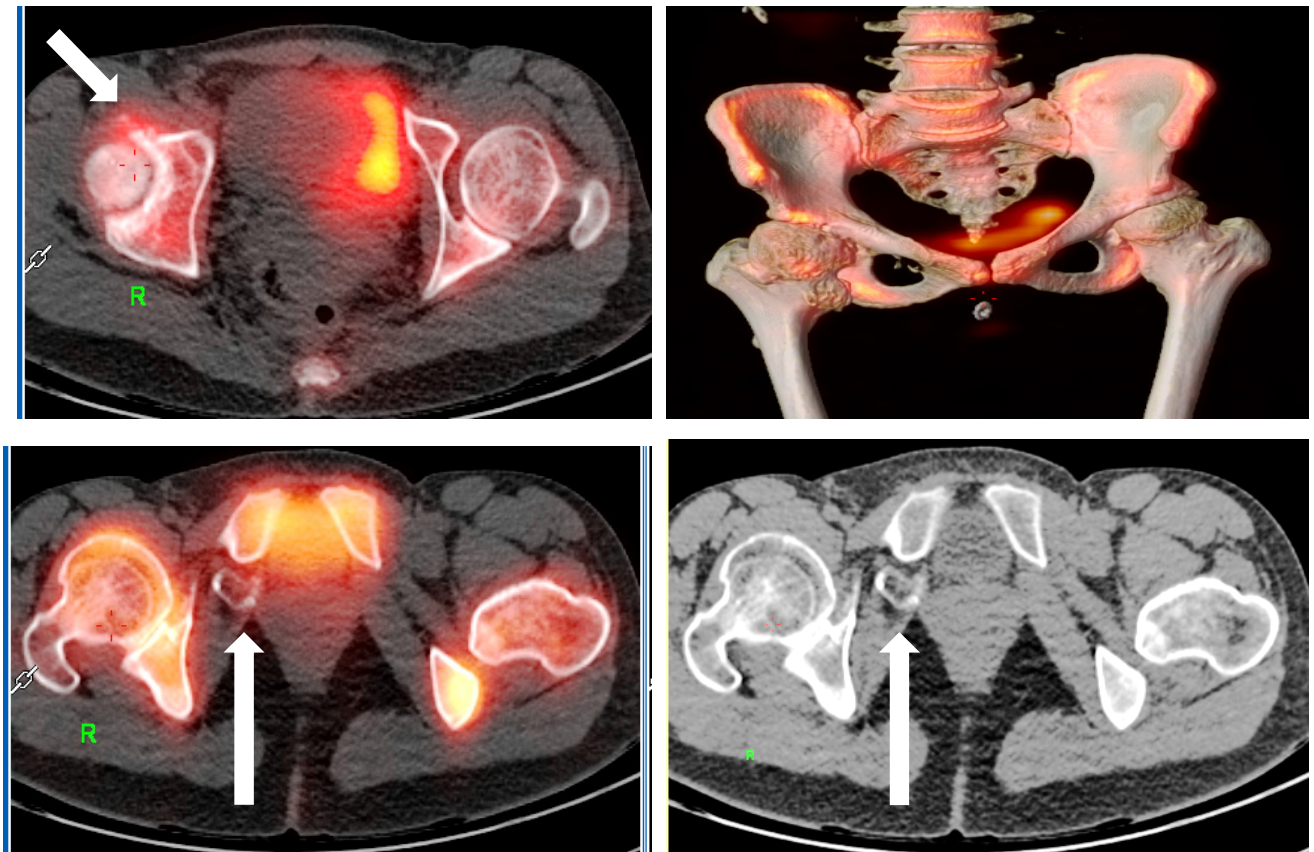
SPECT/CT (B): Shows increased uptake in the ceiling of the right acetabulum (arrow). CT shows bilateral dysplasia and a large osteophyte protruding into the small pelvis (long arrows).

Outcome

The patient was diagnosed with arthrosis and was offered an operation with complete hip replacement but she refused because during that period she was experiencing less pain than usual.



(A)



(B)

5.13. CASE No. PH 13

Study type:	Orthopaedics Traumatology		
Clinical indication:	Hip pain		
Keywords:	Pseudoarthrosis Fracture		
SPECT/CT system:	Philips Precedence 16 slice	Tracer:	^{99m} Tc-HDP
Uptake:	120 min	Dose:	685 MBq
Tube loading:	120 mAs	Tube voltage:	120 kVp

Short clinical history

An 83 year old male patient with increasing pain in the right hip region after osteosynthesis of a fracture of the femoral bone 1 year earlier.

Findings

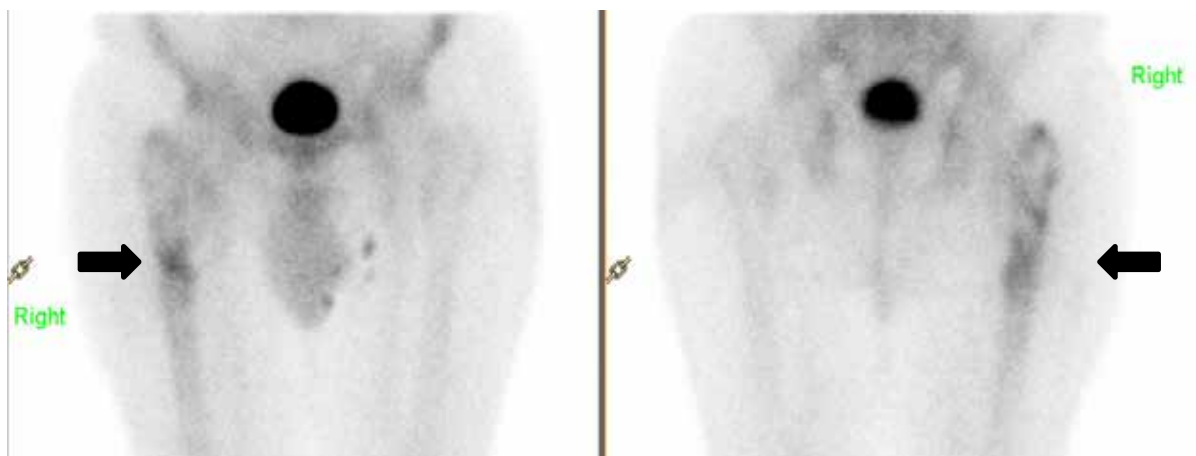
Planar bone scan (A): Shows foci with increased bone metabolism in the right femur from the trochanter area following the femoral stem.

SPECT/CT (B): Shows increased uptake corresponding to CT findings of pseudoarthrosis in the right proximal femur. The patient was diagnosed with a hypertrophic pseudoarthrosis of the right femur.

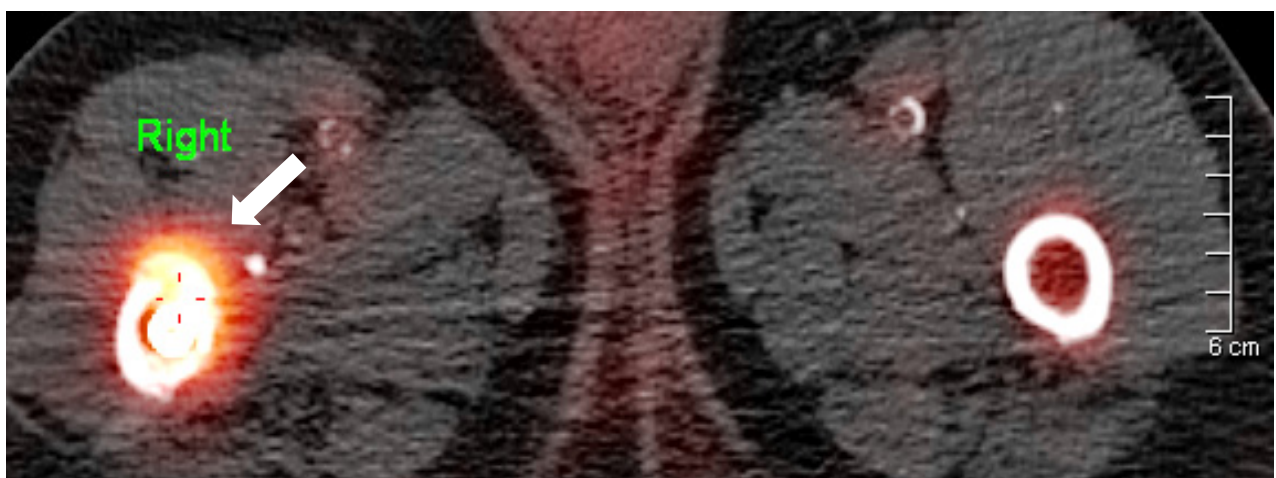
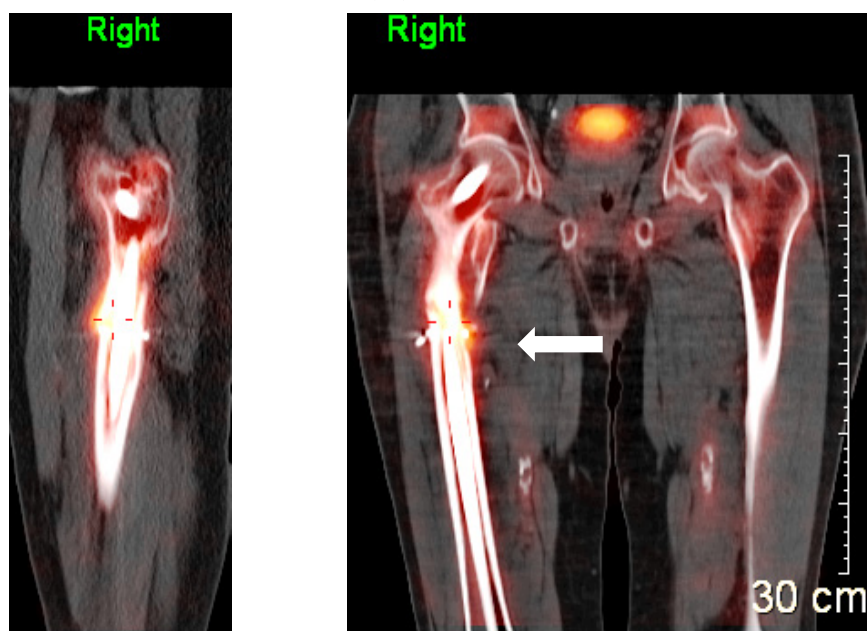
Outcome and teaching point

Planning of surgical treatment with the removal of screws.

Note the bone scan was non-specific, while CT demonstrated the psuedoarthrosis.



(A)



(B)

5.14. CASE No. PH 14

Study type:	Orthopaedics Traumatology		
Clinical indication:	Hip pain		
Keywords:	Arthrosis Fracture Osteoporosis		
SPECT/CT system:	Philips Precedence 16 slice	Tracer:	^{99m}Tc -HDP
Uptake:	120 min	Dose:	704 MBq
Tube loading:	120 mAs	Tube voltage:	120 kVp

Short clinical history

A 75 year old male patient diagnosed with osteoporosis and complained of increasing pain in the left hip region. Atypical fracture suspected due to bisphosphonate treatment.

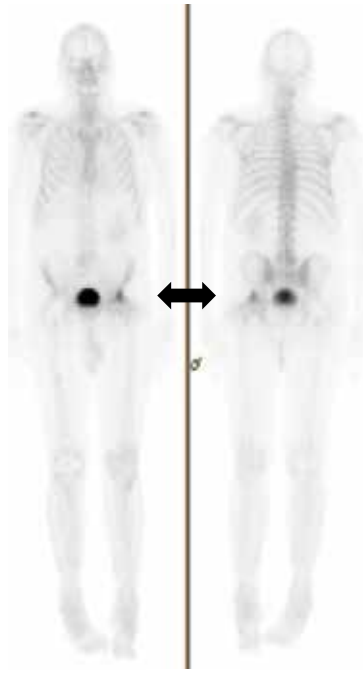
Findings

Whole body scintigraphy (A): Shows focally increased bone metabolism in the upper part of the left acetabulofemoral joint.

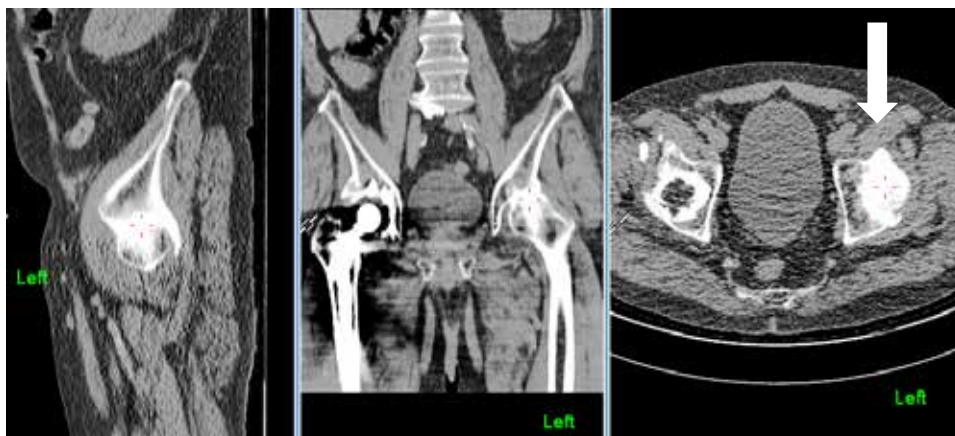
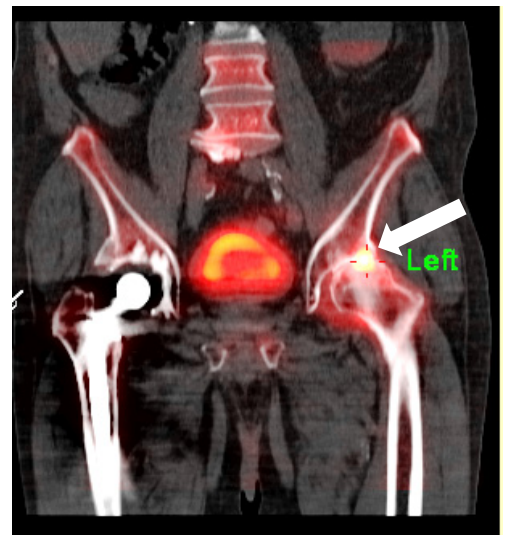
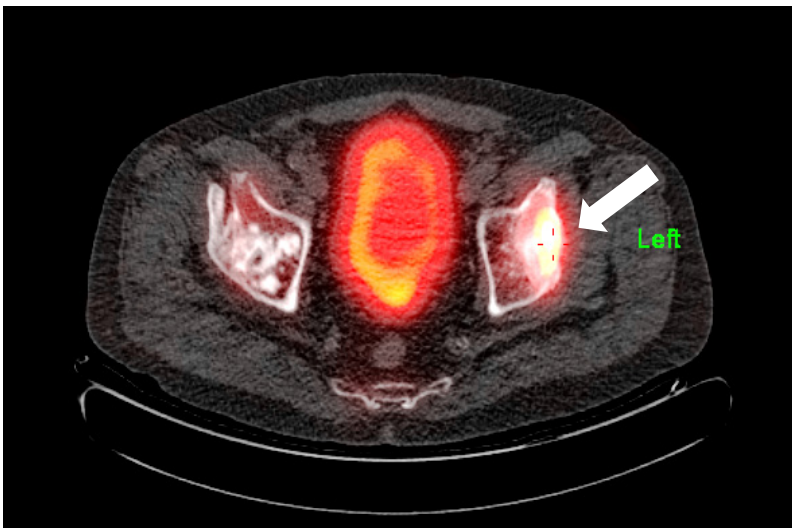
SPECT/CT (B): Confirms the increased uptake in the joint where CT shows narrowing of the joint space due to arthrosis. There is no sign of atypical fracture of the femur.

Outcome

Suspicion of a fracture was refuted by SPECT/CT, whereas arthrosis was diagnosed. Continuing control and treatment for osteoporosis.



(A)



(B)

5.15. CASE No. PH 15

Study type:	Orthopaedics		
Clinical indication:	Pain in the right hip Suspected loosening of THA		
Keywords:	Dislocation Heterotopic ossification		
SPECT/CT system:	Philips BrightView XCT	Tracer:	^{99m}Tc -HDP
Uptake:	180 min	Dose:	702 MBq
Tube loading:	34 mAs	Tube voltage:	120 kVp

Short clinical history

A 67 year old female patient diagnosed with Budd–Chiari syndrome and polycythemia vera and now experiencing pain in the right hip area. Suspected loosening of THA.

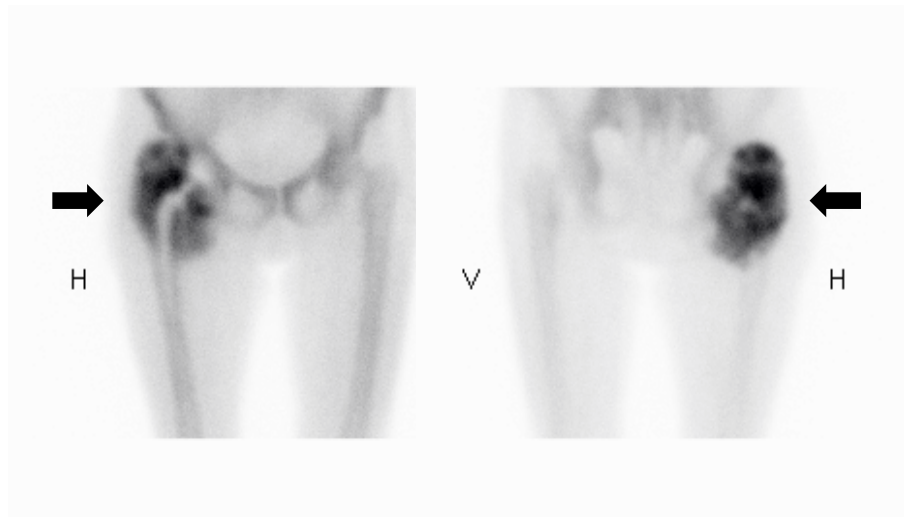
Findings

Planar bone scan (A): Shows a large area with high uptake around the THA adjacent to the proximal right femur.

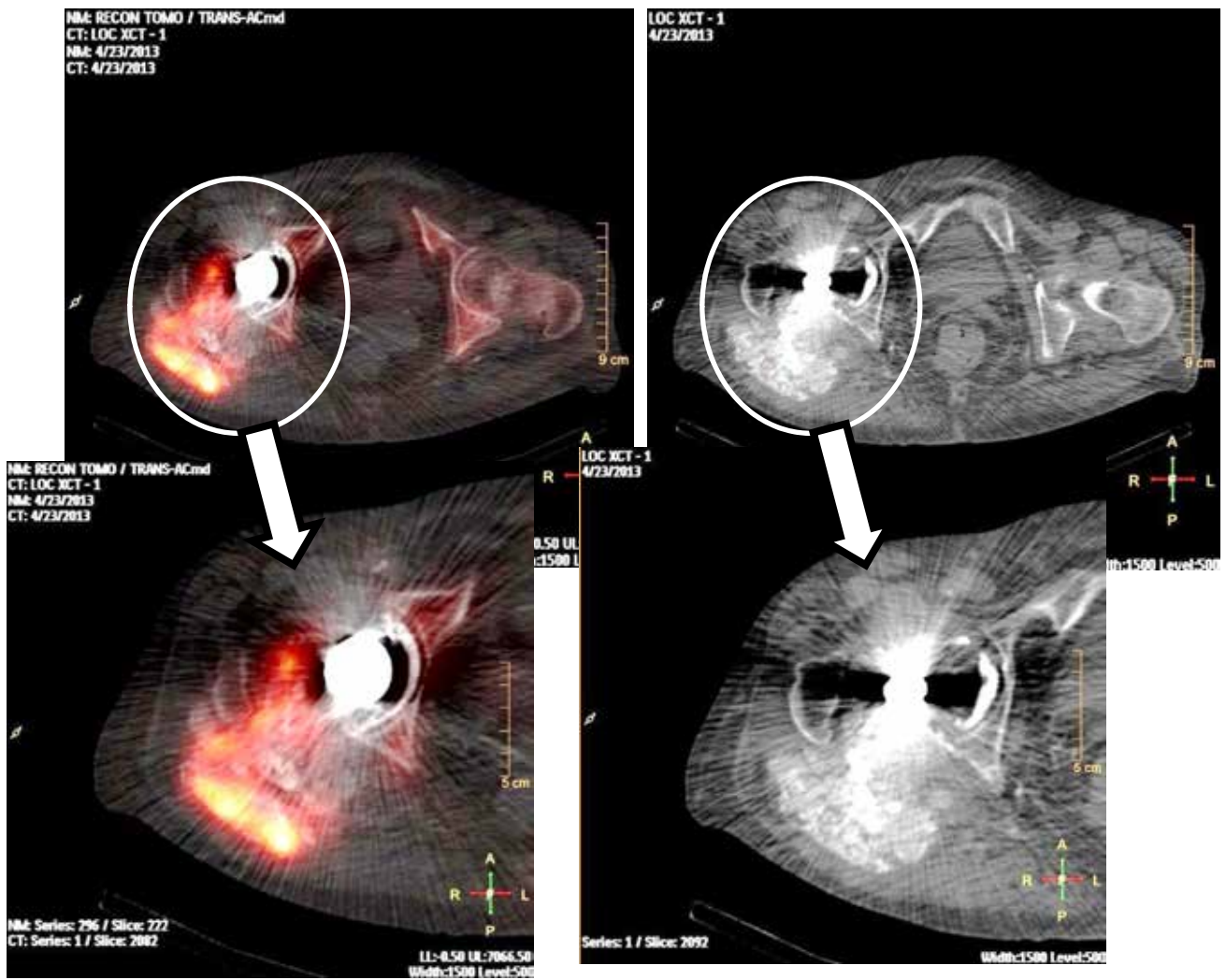
SPECT/CT (B): Demonstrates that uptake was located posteriorly to the proximal part of the right femur and is probably a haematoma, with heterotopic ossification.

Outcome

SPECT/CT contributed to the diagnosis of heterotopic ossification. Ultrasound, MRI and biopsy confirmed the diagnosis of heterotopic ossification.



(A)



(B)

6. SHOULDER AND ELBOW

6.1. CASE No. SE 1

Study type:	Orthopaedic		
Clinical indication:	Osteoarthritis of acromioclavicular joint		
Keywords:	Osteoarthritis		
SPECT/CT system:	Siemens Symbia T2	Tracer:	^{99m}Tc -DPD
Uptake:	5 and 180 min	Dose:	508 MBq
Tube loading:	120 mAs	Tube voltage:	80 kVp

Short clinical history

A 66 year old male patient with chronic shoulder pain on the right side.

Findings

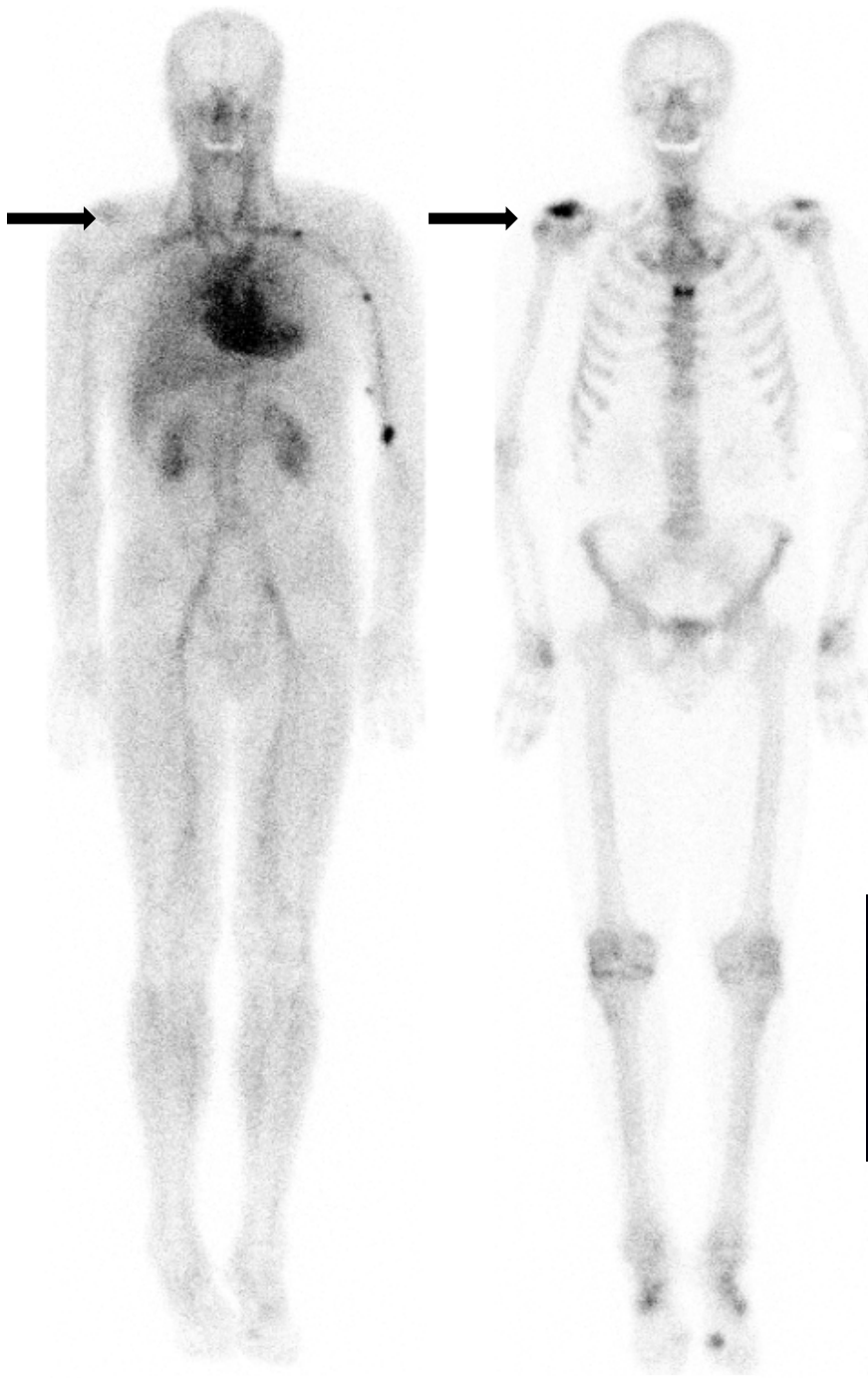
Planar images of blood pool (A): Shows focal uptake in the region of the right acromioclavicular joint (arrow) and uptake (less intensive) in the right knee, both representing synovialitis.

Planar image of mineralization (B): Shows intense uptake in right acromioclavicular joint (arrow). Furthermore, whole body scintigraphy shows polyarthrosis (maximum in both knees and first metatarsotarsal joint right) and uptake in the angulus sterni as a normal variant.

SPECT/CT: Shows osteoarthrosis of right acromioclavicular joint (C) and uptake in the right facet joint C3 (D) which presents normal in CT.

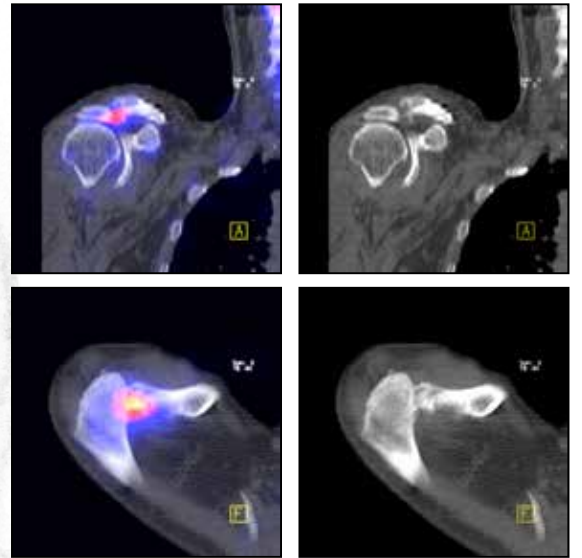
Outcome

Radiosynoviorthesis of right acromioclavicular joint was performed using 37 MBq ^{186}Re -colloid.

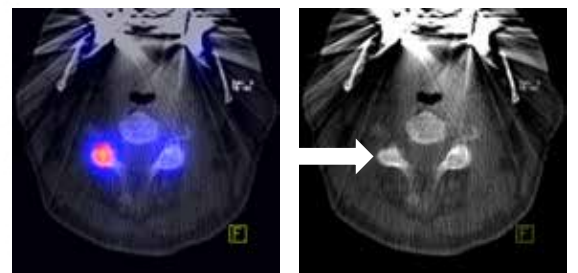


(A)

(B)



(C)



(D)

6.2. CASE No. SE 2

Study type:	Orthopaedic Traumatology		
Clinical indication:	Post-traumatic shoulder pain		
Keywords:	Contusion of humoral head		
SPECT/CT system:	Siemens Symbia T2	Tracer:	^{99m}Tc -DPD
Uptake:	5 and 180 min	Dose:	508 MBq
Tube loading:	120 mAs	Tube voltage:	80 kVp

Short clinical history

A 42 year old male patient with shoulder pain on the right side following a bicycle accident.

Findings

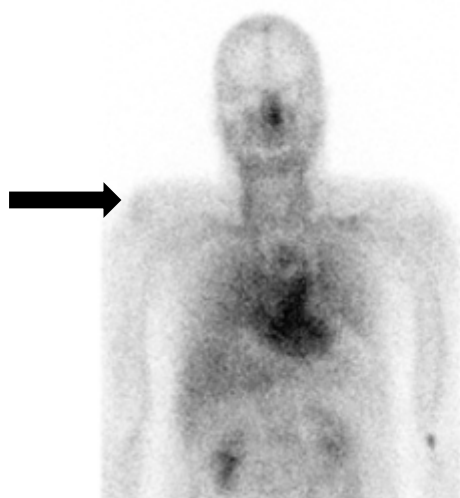Planar images of blood pool (A): Shows focal uptake in the lateral right head of the humerus (arrow).

Planar image of mineralization (B): Shows intense uptake in the lateral right head of the humerus (arrow).

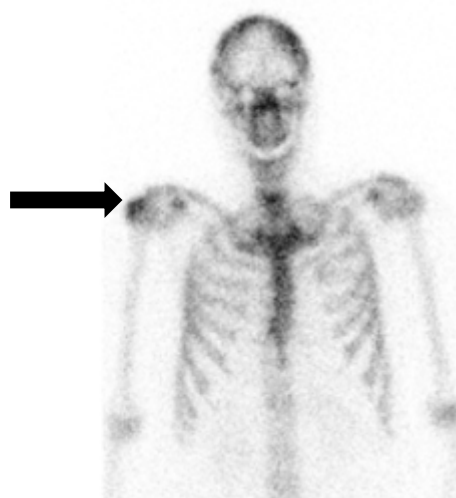SPECT/CT (C): Allowed the location of uptake in a CT morphologic dense area representing a contusion.

Outcome

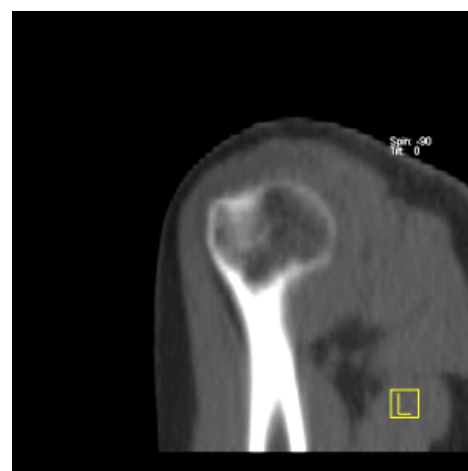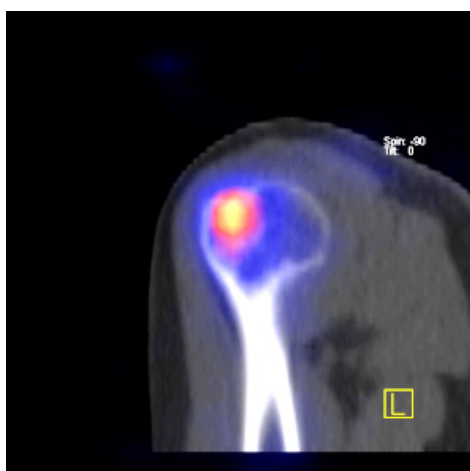
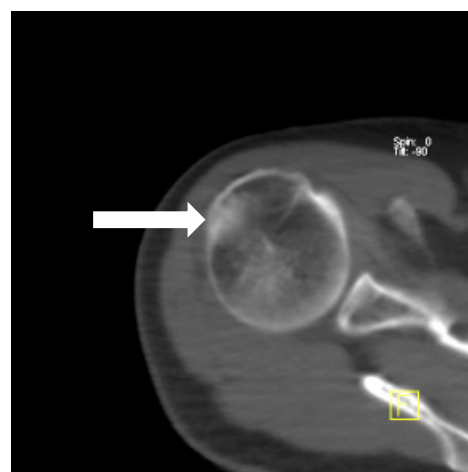
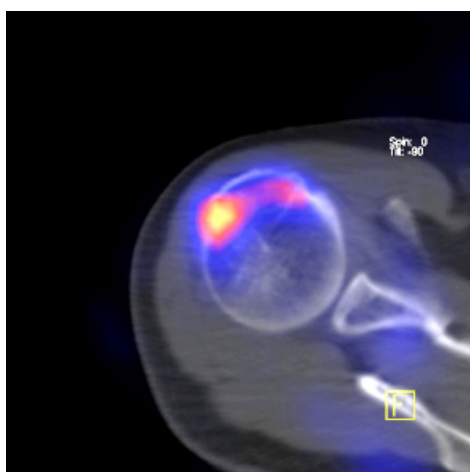
SPECT/CT is able to classify the type of post-traumatic injury. As a result, conservative therapy was applied.



(A)



(B)



(C)

6.3. CASE No. SE 3

Study type:	Orthopaedic Traumatology		
Clinical indication:	Shoulder pain		
Keywords:	Fracture of humoral head		
SPECT/CT system:	Siemens Symbia T2	Tracer:	^{99m}Tc -DPD
Uptake:	5 and 180 min	Dose:	508 MBq
Tube loading:	120 mAs	Tube voltage:	80 kVp

Short clinical history

A 72 year old female patient with right shoulder pain. No definite trauma in recent history.

Findings

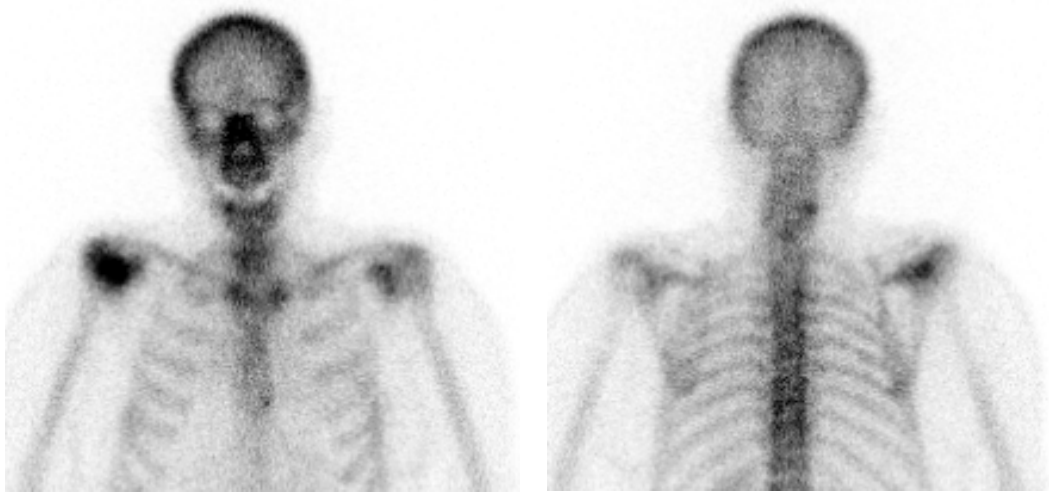Planar image (A): Shows intense uptake in the right humoral head.

SPECT/CT (B): Shows dense area (arrow) representing an infraction. No glenoid infraction.

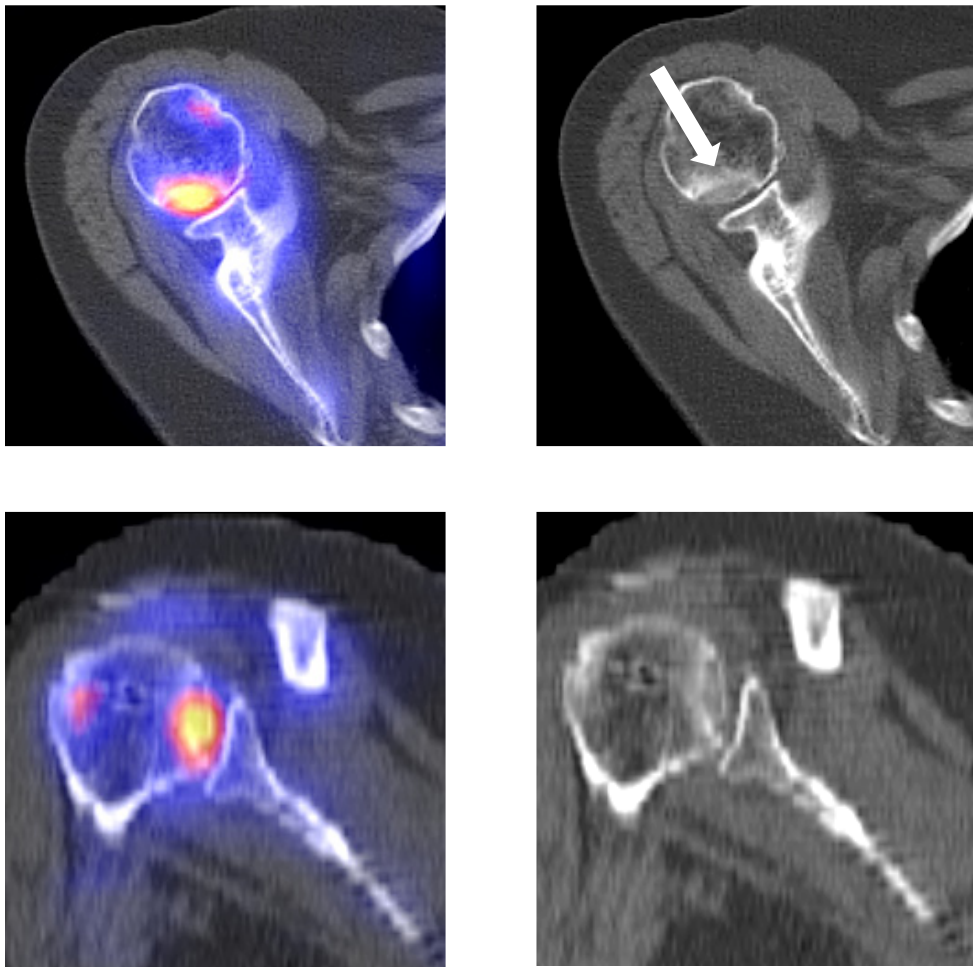
Outcome and teaching point

Conservative therapy.

Note SPECT/CT allows the specification of the type of post-traumatic injury.



(A)



(B)

6.4. CASE No. SE 4

Study type:	Orthopaedics Degenerative		
Clinical indication:	Exercise dependent pain after anterior shoulder luxation 4 years earlier		
Keywords:	Pain		
SPECT/CT system:	General Electric Discovery 670	Tracer:	^{99m}Tc -DPD
Uptake:	180 min	Dose:	677 MBq
Tube loading:	120–400 mAs	Tube voltage:	120 kVp

Short clinical history

A 22 year old male patient with exercise dependent pain in the right shoulder. S/p luxation, known Hill–Sachs and Bankart lesion and biceps tendinopathy. The MRI was inconclusive based on multiple areas with bone oedema.

Findings

Planar bone scan (A): Shows only mild diffuse uptake. Suspicion of early osteoarthritis.

SPECT/CT (B): Shows mild uptake at the posterior residual Hill–Sachs lesion (short arrow). In addition, there is mild uptake at the medial biceps sulcus and joint space narrowing (long arrow).

Overall, SPECT/CT shows early degenerative/post-traumatic osteoarthritic changes as well as residual post-traumatic bone remodelling.

Outcome and teaching point

Conservative therapy.

Note SPECT/CT allows the specification of the type of post-traumatic injury.

6.5. CASE No. SE 5

Study type:	Orthopaedics Degenerative		
Clinical indication:	Chronic pain after implantation of an inverted shoulder prosthesis on the right side		
Keywords:	Pain Prosthesis		
SPECT/CT system:	General Electric Discovery 670	Tracer:	^{99m}Tc -DPD
Uptake:	180 min	Dose:	651 MBq
Tube loading:	120–400 mAs	Tube voltage:	120 kVp

Short clinical history

A 59 year old female patient with chronic right shoulder pain after placement of inverted prosthesis 11 months prior to imaging. The MRI was inconclusive due to metallic artefacts. Suspected early loosening.

Findings

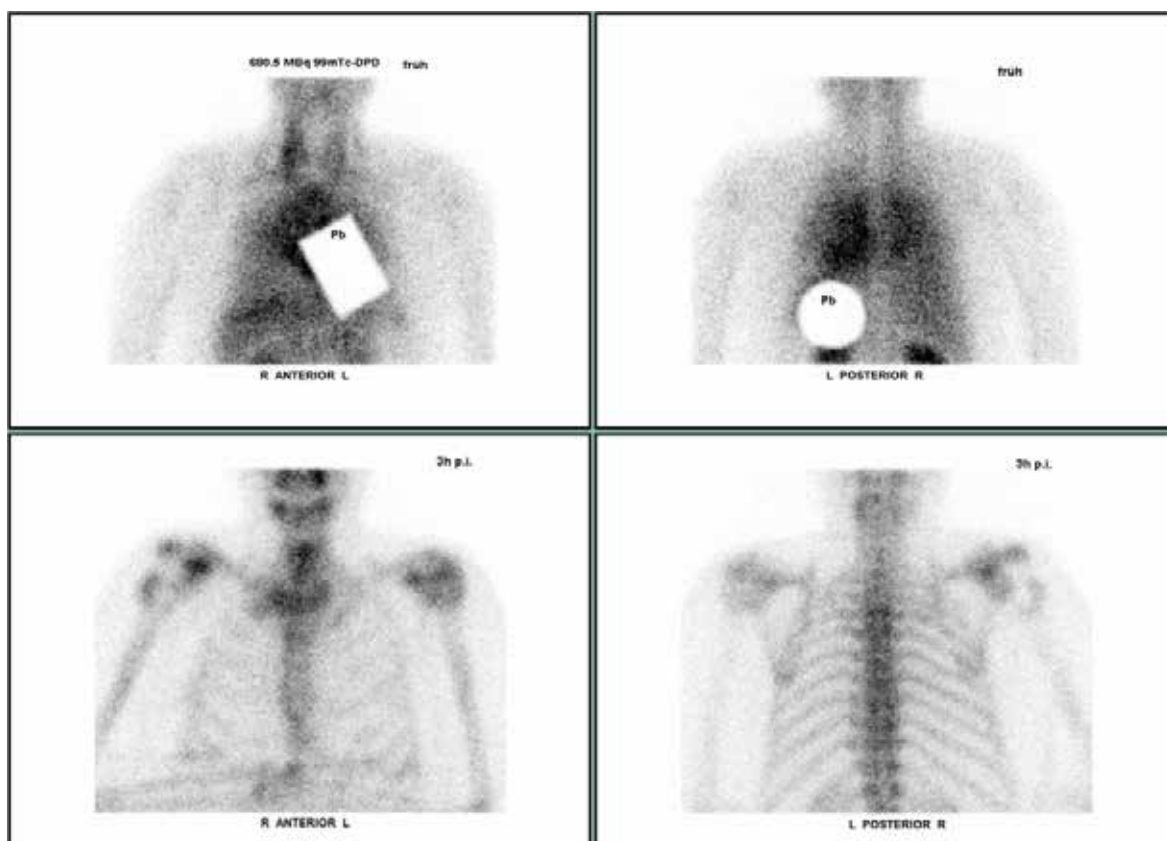
Planar bone scan (A): Shows only mild, inconclusive diffuse uptake in the right glenoid. From planar bone imaging no definite conclusion can be made whether this uptake is persistent bone remodelling or early loosening.

SPECT/CT (B): Shows significant uptake around the main prosthetic stem in the right glenoid. No other uptake noted in the superior part of the glenoid. Overall SPECT/CT is indicative for early loosening.

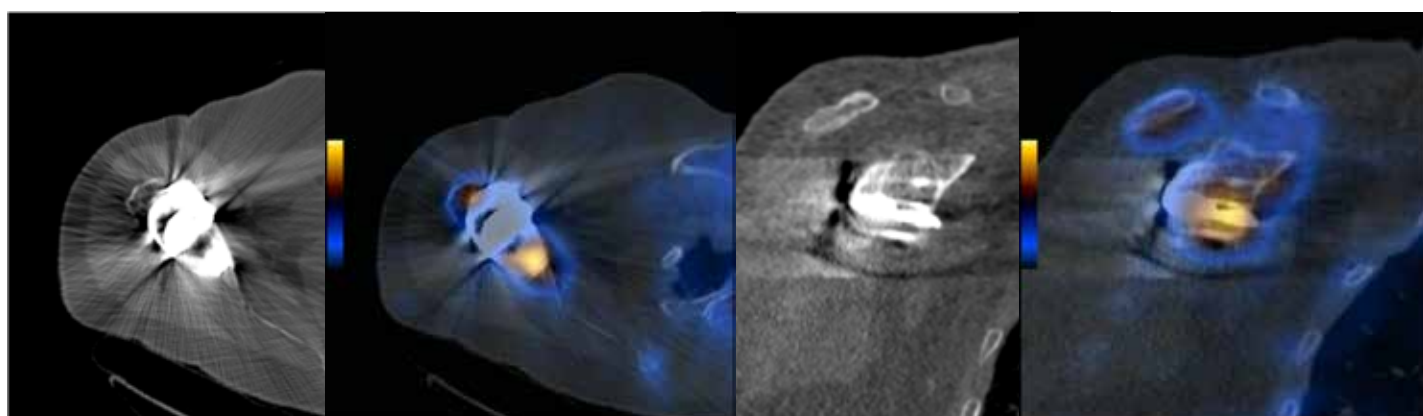
Outcome and teaching point

Clinical follow-up. Conservative pain management with no additional surgery so far.

Note SPECT/CT helps to localize the area of elevated metabolism in complex surgical cases.



(A)



(B)

6.6. CASE No. SE 6

Study type:	Traumatology Degenerative		
Clinical indication:	Bone healing Viability of bone graft		
Keywords:	Bone graft Delayed union		
SPECT/CT system:	General Electric Discovery 670	Tracer:	^{99m}Tc -DPD
Uptake:	180 min	Dose:	663 MBq
Tube loading:	120–400 mAs	Tube voltage:	120 kVp

Short clinical history

A 31 year old male patient with a multifragment fracture of the left forearm 2 years earlier. S/p pseudoarthrosis revision surgery and re-fixation and insertion of bone graft from the left pelvis 4 months earlier.

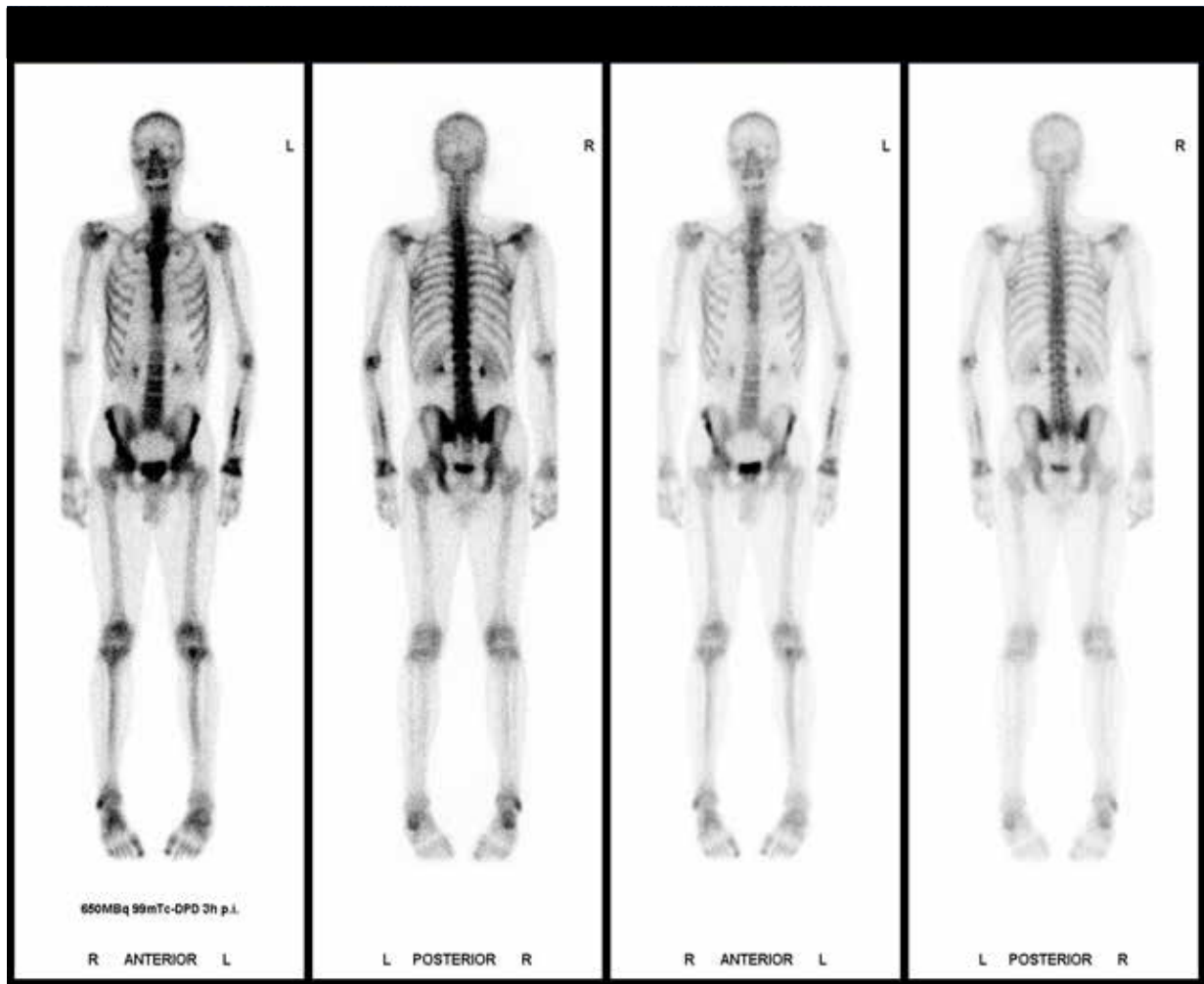
Findings

Planar bone scan (A): Shows increased uptake of the left forearm as well as diffuse reactive uptake of the left wrist.

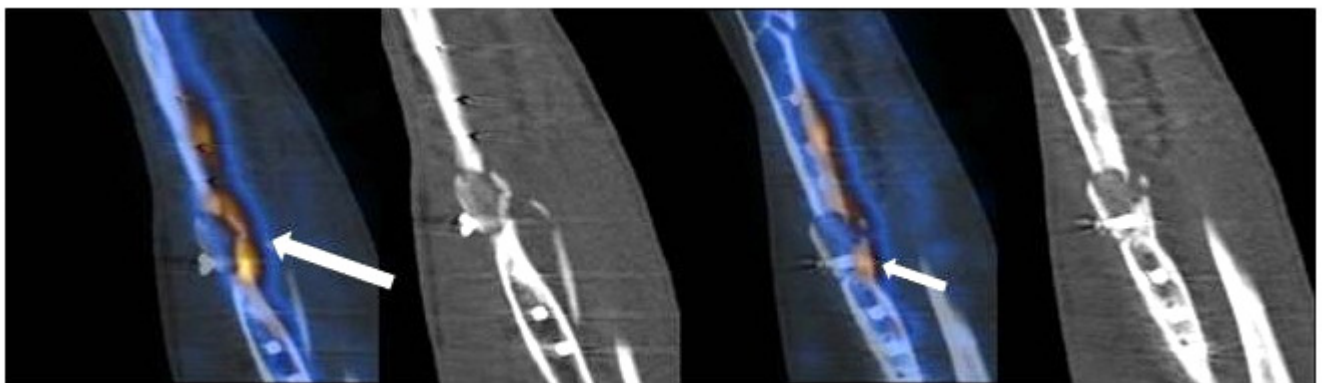
The SPECT/CT (B): Also shows the inserted bone graft with elevated uptake as a sign of viability, especially laterally (large arrow). In the corresponding CT, there is bone bridging seen. In addition, there is also uptake seen at the proximal insertion of the bone graft (small arrow), indicating further growth and bone bridging there as well.

Outcome

Depiction of viability based on SPECT/CT findings. Continuation of conservative supportive therapy.



(A)



(B)

6.7. CASE No. SE 7

Study type:	Rheumatology Degenerative		
Clinical indication:	Chronic pain in the left elbow		
Keywords:	Pain		
SPECT/CT system:	General Electric Discovery 670	Tracer:	^{99m}Tc -DPD
Uptake:	180 min	Dose:	677 MBq
Tube loading:	120–400 mAs	Tube voltage:	120 kVp

Short clinical history

A 38 year old male patient with chronic pain at the upper medial left condylus. No significant history of sport activities and no recent trauma. Pain for more than 2 years.

Findings

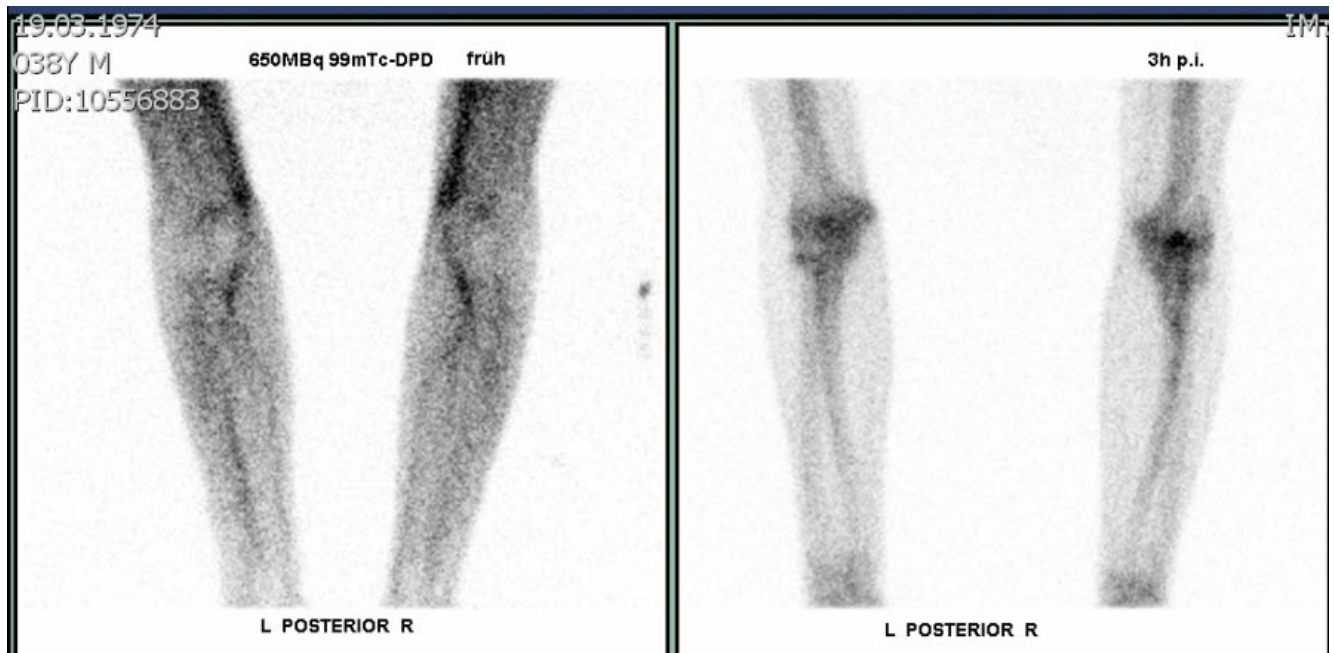The MRI was inconclusive and the planar bone scan (A) unremarkable.

SPECT/CT (B): Shows no significant uptake at, or superior to, the medial condylus. The morphological CT component shows a supracondylar process (arrow). A Struthers' ligament attached to the process may cause entrapment of the ulnar nerve.

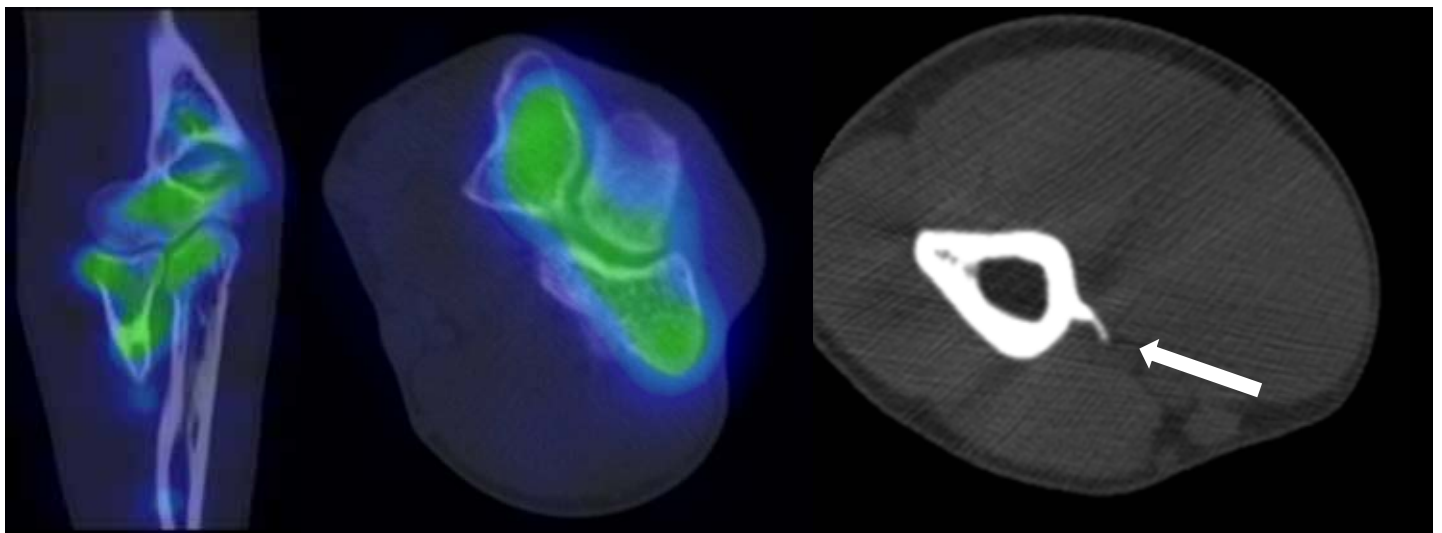
Outcome and teaching point

Additional MRI requested to visualize the ligament. Resection of the supracondylar process and the additional ligament.

Note that in cases with no obvious metabolic information from SPECT, the CT component has to be evaluated carefully.



(A)



(B)

7. HAND AND WRIST

7.1. CASE No. HW 1

Study type:	Orthopaedics Traumatology		
Clinical indication:	Pain in the right wrist		
Keywords:	Post-traumatic osteomalacia of the right os lunatum		
SPECT/CT system:	Siemens Symbia T2	Tracer:	^{99m}Tc -DPD
Uptake:	180 min	Dose:	498 MBq
Tube loading:	100 mAs	Tube voltage:	60 kVp

Short clinical history

A 34 year old female patient with pain in the right wrist for 4 months.

Findings

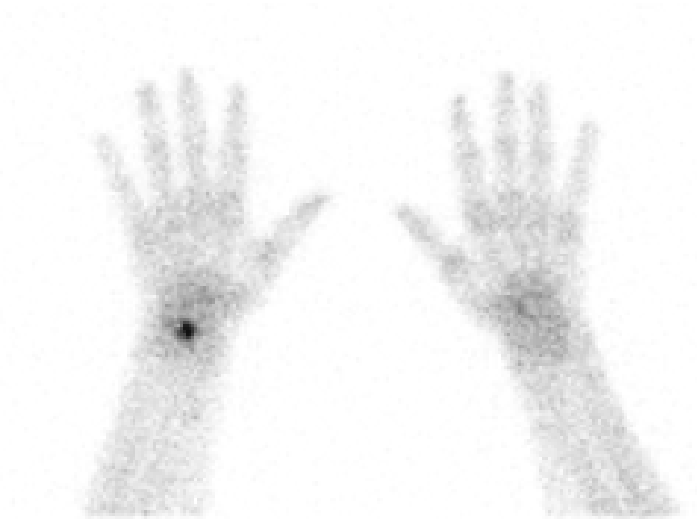Planar image (A): Shows intense uptake in the right wrist.

SPECT/CT (B): Shows focal tracer uptake in the right lunate bone with only minimum sclerotic changes on CT (arrow) representing an osteomalacia.

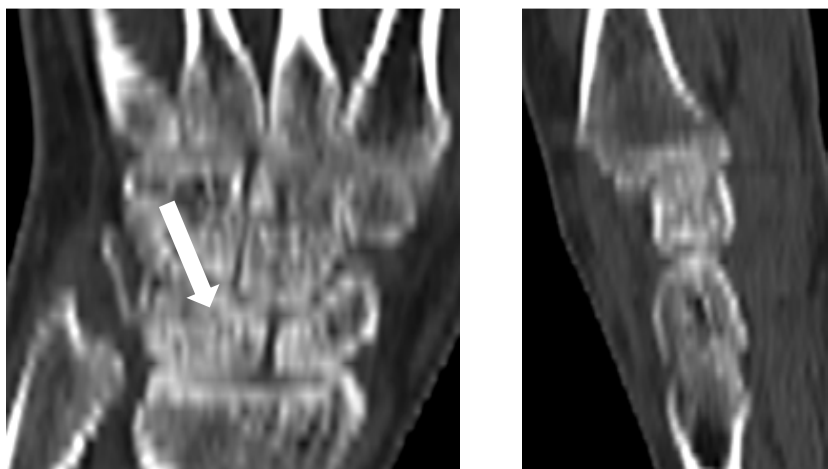
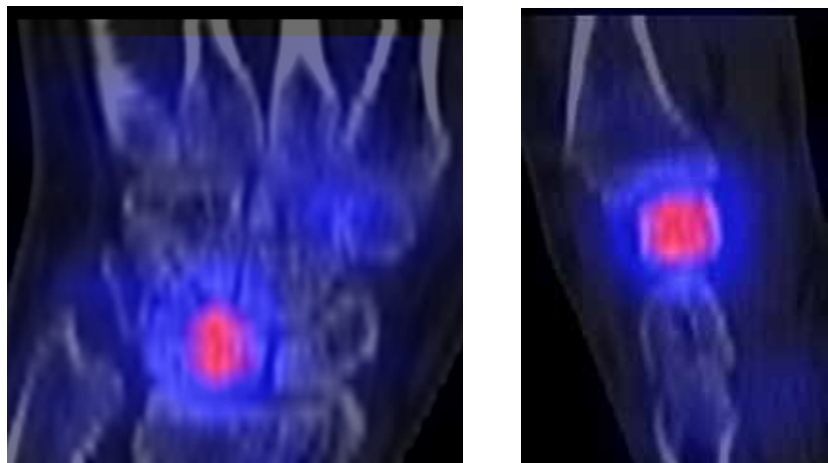
Outcome and teaching point

Conservative therapy.

Note SPECT/CT identifies early onset of bone necrosis/malacia with respect to metabolism and localization.



(A)



(B)

7.2. CASE No. HW 2

Study type:	Orthopaedics Traumatology		
Clinical indication:	Pain in the right hand, with the highest intensity in finger D4 Verification of medical indication to perform radiosynoviorthesis		
Keywords:	Osteoarthritis		
SPECT/CT system:	Siemens Symbia T2	Tracer:	^{99m}Tc -HPD
Uptake:	180 min	Dose:	519 MBq
Tube loading:	100 mAs	Tube voltage:	80 kVp

Short clinical history

A 34 year old female patient with pain in the right hand for 2 years. The pain had been increasing for 2 months.

Findings

Planar images of blood pool (A): Show focal uptake in the proximal interphalangeal joint D4 and metacarpophalangeal joint D1 (arrows), representing synovialitis.

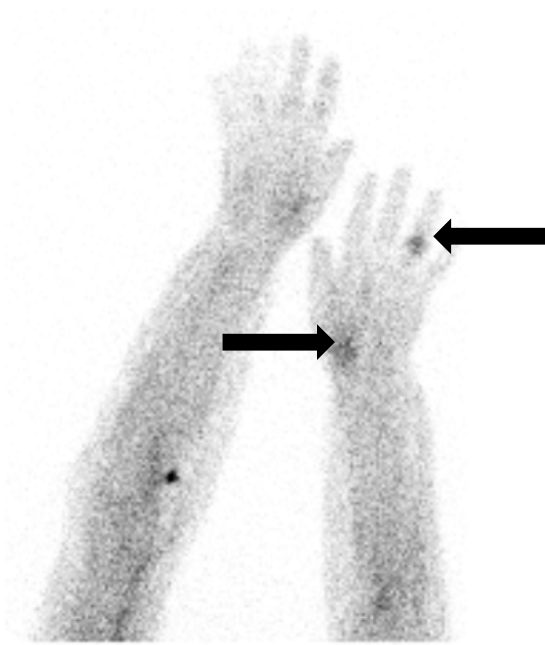
Planar image of mineralization (B): Shows intense uptake in the same areas.

SPECT/CT (C): Shows focal tracer uptake in the proximal interphalangeal joint D4 and metacarpophalangeal joint D1 with osteoarthritic changes in CT.

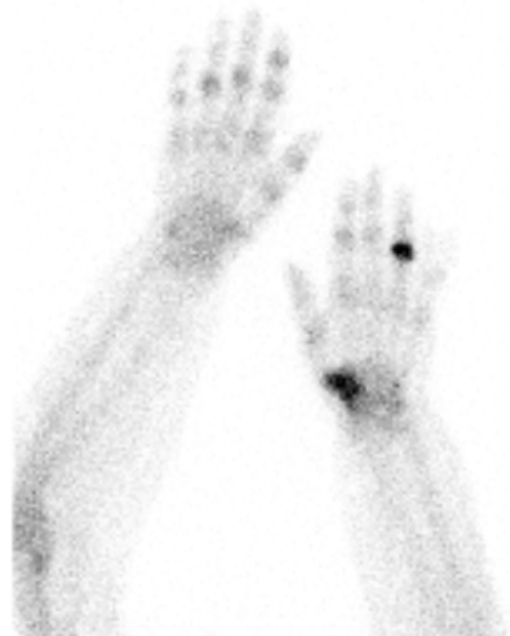Outcome and teaching point

Conservative therapy.

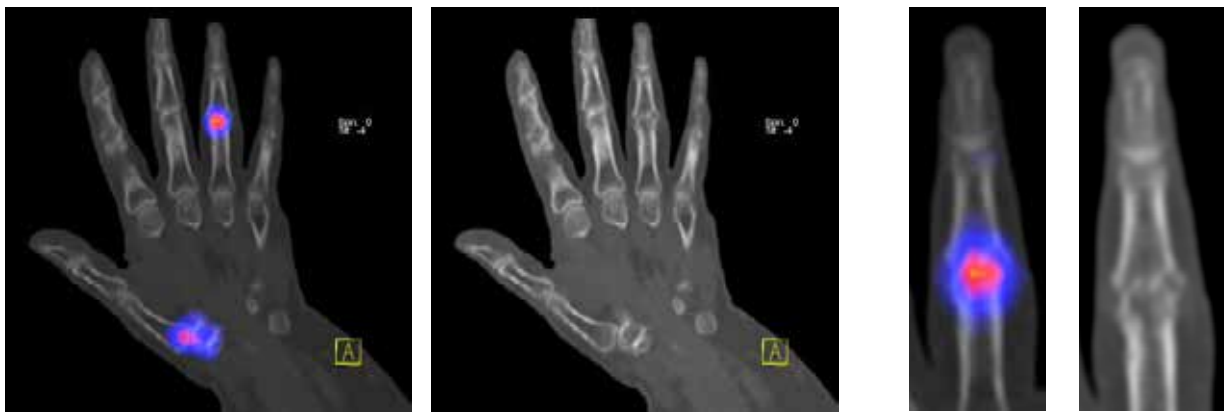Note SPECT/CT identifies early onset of bone necrosis/malacia with respect to metabolism and localization.



(A)



(B)



(C)

7.3. CASE No. HW 3

Study type:	Orthopaedic		
Clinical indication:	Pain in the left hand, with the highest intensity in the metacarpophalangeal joint D1		
Keywords:	Osteoarthritis		
SPECT/CT system:	Siemens Symbia T2	Tracer:	^{99m}Tc -HPD
Uptake:	180 min	Dose:	508 MBq
Tube loading:	100 mAs	Tube voltage:	60 kVp

Short clinical history

A 60 year old female patient with pain in the left hand.

Findings

Planar image of mineralization (A): Shows intense uptake in the metacarpophalangeal joint D1.

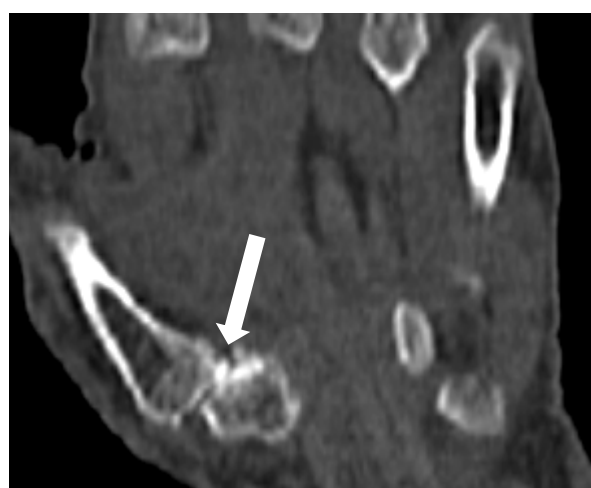
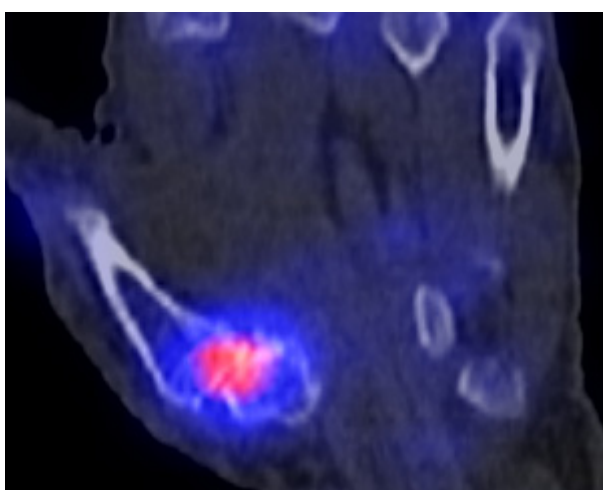
SPECT/CT (B): Shows exact area of focal tracer uptake in the metacarpophalangeal joint D1 with extensive degenerative changes in CT representing osteoarthritis (arrow).

Outcome

Radiosynoviorthesis was performed using 18 MBq ^{169}Er -citrate.



(A)



(B)

7.4. CASE No. HW 4

Study type:	Orthopaedic		
Clinical indication:	Pain in the left hand		
Keywords:	Osteoarthritis		
SPECT/CT system:	Siemens Symbia T2	Tracer:	^{99m}Tc -HPD
Uptake:	180 min	Dose:	508 MBq
Tube loading:	100 mAs	Tube voltage:	60 kVp

Short clinical history

A 58 year old male patient with pain in the left hand.

Findings

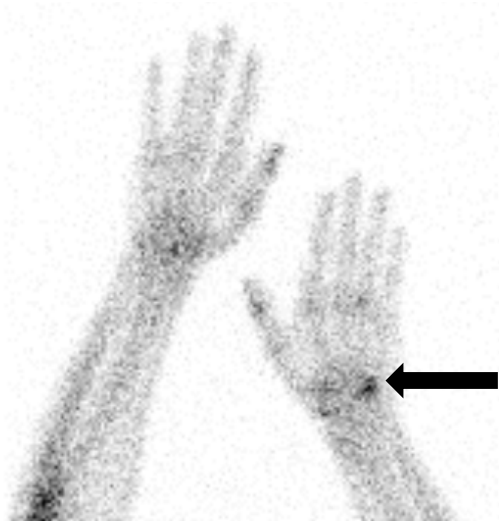Planar image (A): Shows intense uptake in the left ulnar aspect of the wrist (arrow). The exact localization on the planar image is not possible to know.

SPECT/CT (B, C): Shows the exact area of focal tracer uptake in the CMC 5 joint with degenerative changes in CT (arrow) representing osteoarthritis.

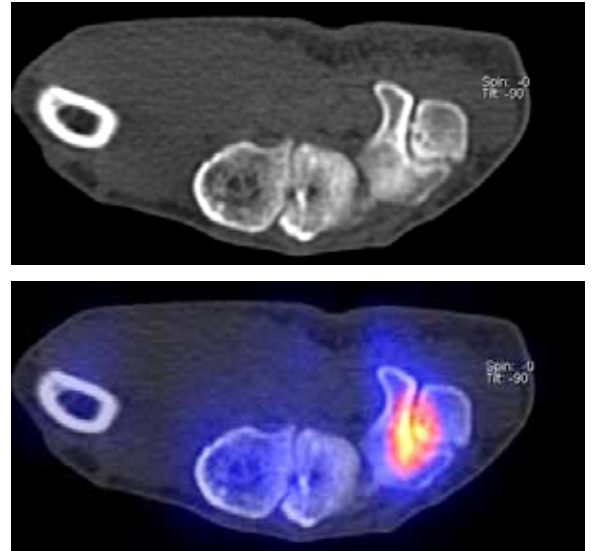
Outcome and teaching point

Conservative treatment.

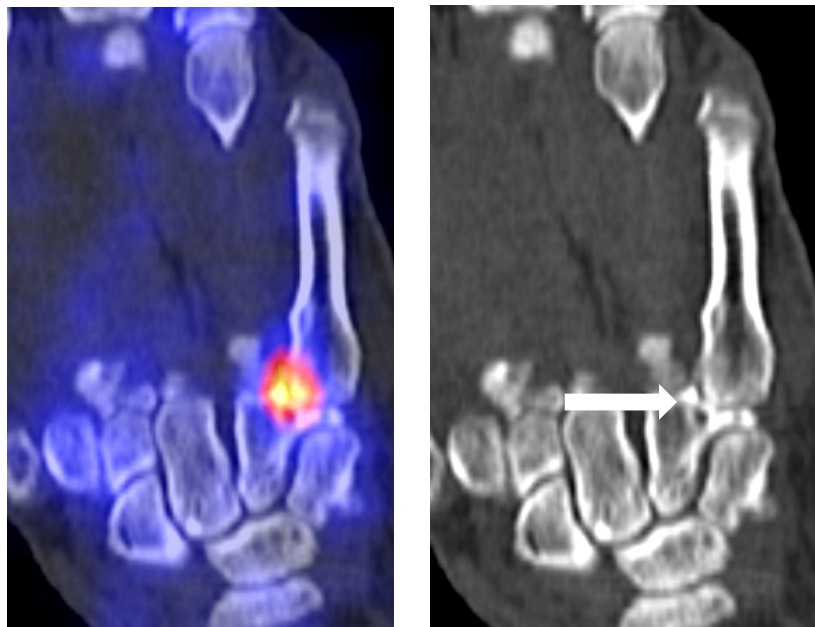
Note SPECT/CT allows the exact localization of the degenerative changes.



(A)



(B)



(C)

7.5. CASE No. HW 5

Study type:	Orthopaedic		
Clinical indication:	Pain in the right hand Verification of medical indication to perform radiosynoviorthesis		
Keywords:	Osteoarthritis of first metacarpophalangeal and scaphotrapeziotrapezoid joints		
SPECT/CT system:	Siemens Symbia T2	Tracer:	^{99m}Tc -DPD
Uptake:	180 min	Dose:	510 MBq
Tube loading:	100 mAs	Tube voltage:	60 kVp

Short clinical history

A 59 year old male patient with pain in the right hand.

Findings

Planar images of blood pool (A): Shows focal uptake in the area of the right first metacarpophalangeal joint (arrow) representing synovialitis.

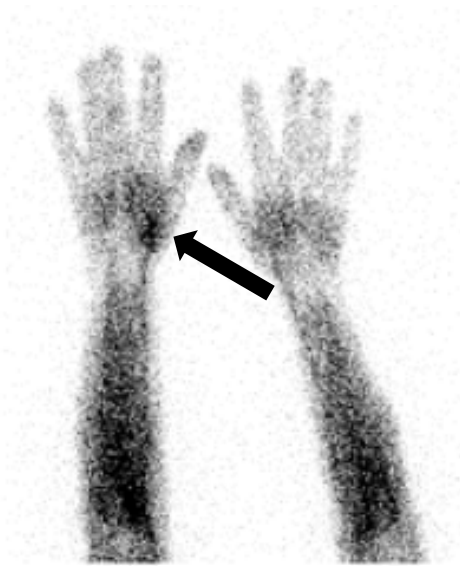Planar image of mineralization (B): Shows intense uptake in the same area (arrow).

SPECT/CT (C): Shows the exact area of focal tracer uptake in the first metacarpophalangeal joint and the adjacent scaphotrapeziotrapezoid joint with degenerative changes in CT (arrows), representing osteoarthritis.

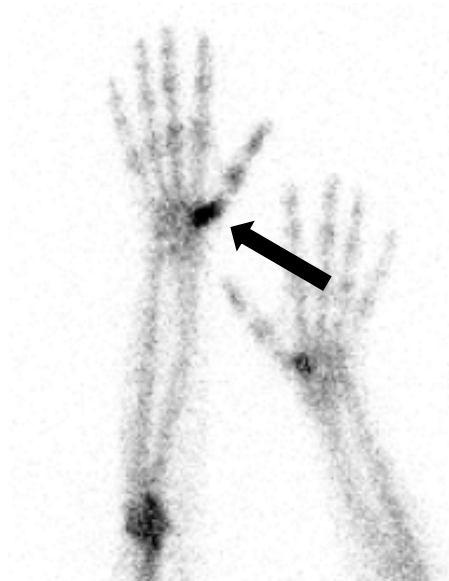Outcome and teaching point

Radiosynoviorthesis of both joints was performed using 18 MBq ^{169}Er -citrate.

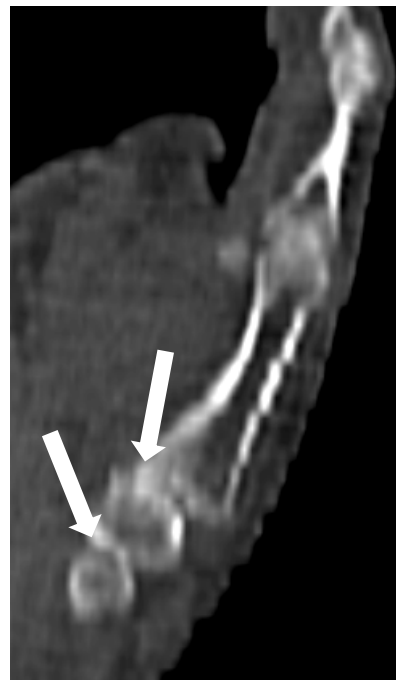
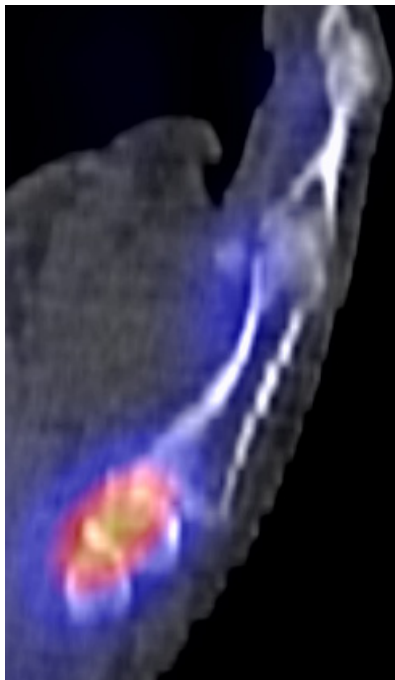
Note planar imaging alone is not able to differentiate between small joints, which is important with respect to therapy.



(A)



(B)



(C)

7.6. CASE No. HW 6

Study type:	Orthopaedics Traumatology		
Clinical indication:	Finger pain		
Keywords:	Pseudoarthrosis Fracture		
SPECT/CT system:	Philips Precedence 16 slice	Tracer:	^{99m}Tc -DPD
Uptake:	120 min	Dose:	672 MBq
Tube loading:	120 mAs	Tube voltage:	120 kVp

Short clinical history

A 53 year old female patient with a 5th metacarpal fracture 4 years earlier. The patient underwent osteotomy four times owing to pseudoarthrosis, with no sufficient result.

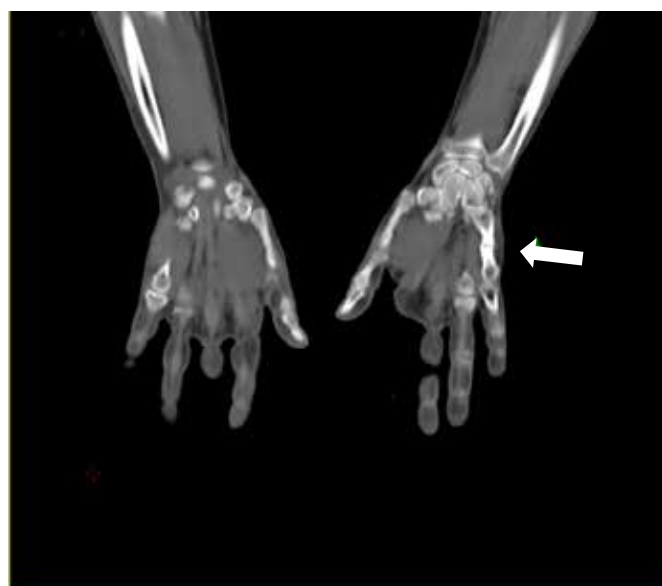
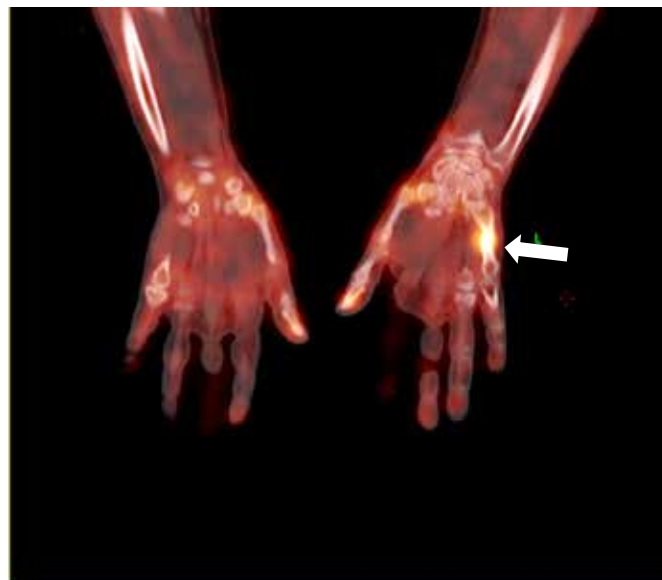
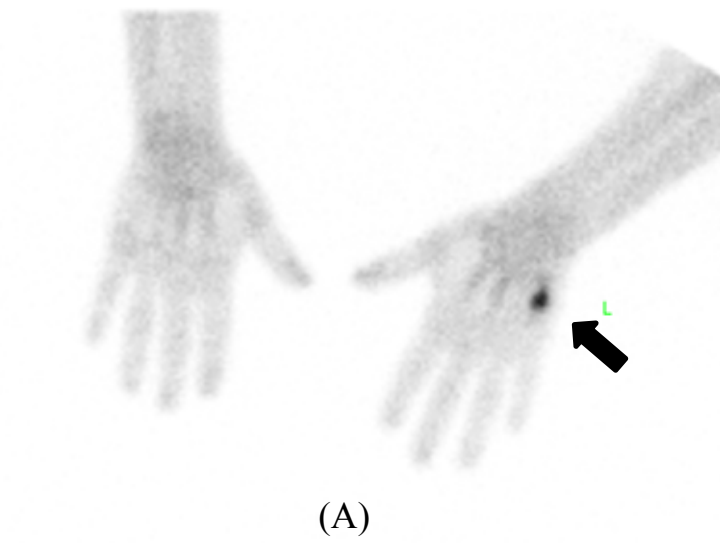
Findings

Planar images (A): Shows an isolated focus in the proximal part of the 5th left metacarpal bone (arrow).

SPECT/CT (B): Shows increased bone uptake in the pseudoarthrosis (arrow) with no morphologic signs of healing on CT.

Outcome

Surgery due to precise SPECT/CT diagnosis of pseudoarthrosis in the 5th left metacarpal bone (failed healing). Bone chips from allograft and K-wire were used for stabilization.



(B)

7.7. CASE No. HW 7

Study type:	Traumatology		
Clinical indication:	Pain		
Keywords:	Bone bruise		
SPECT/CT system:	Siemens Symbia T6	Tracer:	^{99m}Tc -DPD
Uptake:	240 min	Dose:	756 MBq
Tube loading:	48 mAs	Tube voltage:	130 kVp

Short clinical history

A 35 year old male patient complained of pain in the left wrist after a recent fall. The X ray was negative.

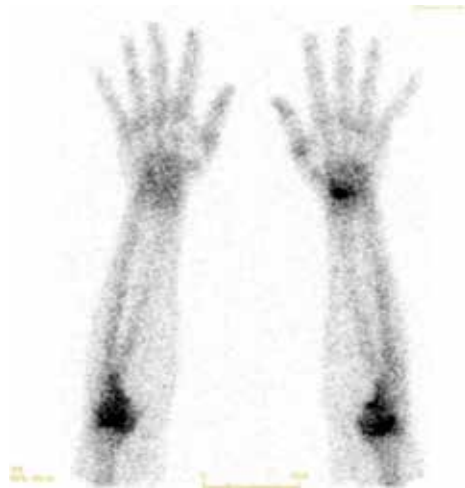
Findings

Planar image (A): Shows slightly increased activity in the left wrist.

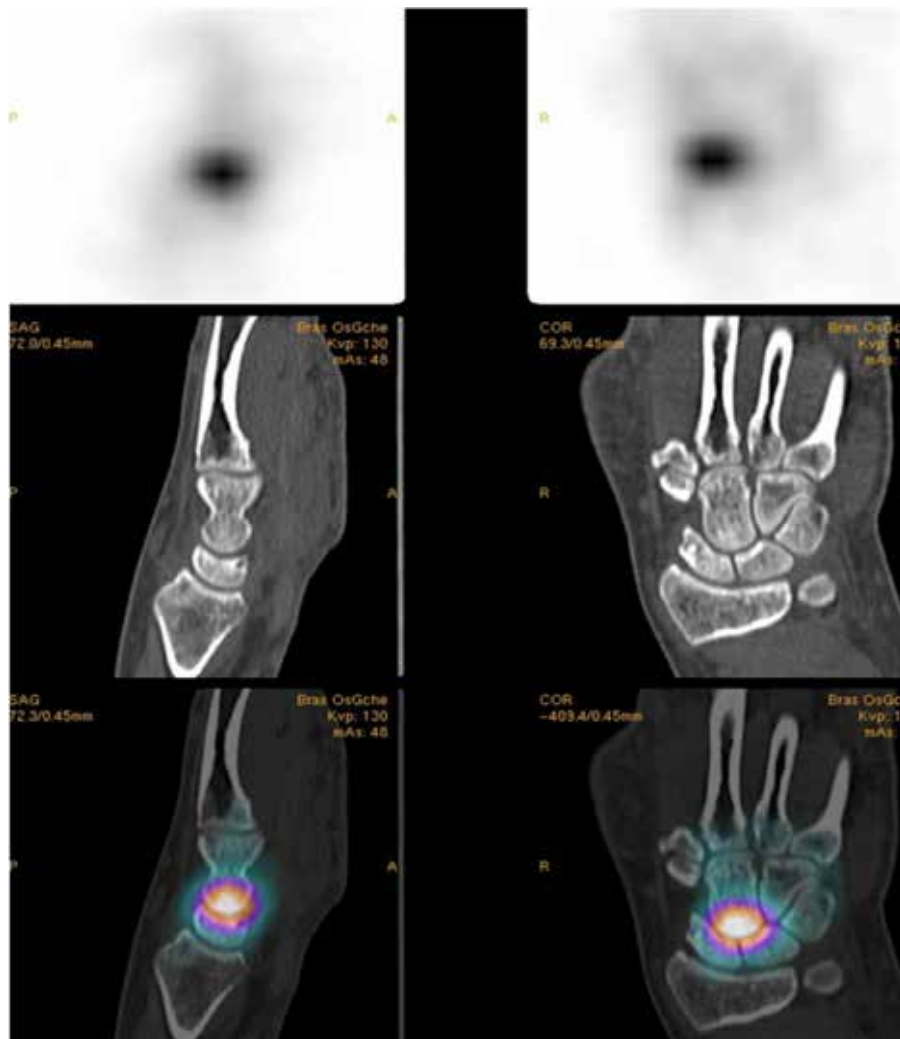
SPECT/CT (B): Shows focus of increased activity located at the proximal aspect of the capitate bone, with normal CT, consistent with a bone bruise.

Teaching point

For the hand and wrist, even in the absence of structural anomalies CT can be very useful for precise localization of metabolic anomalies.



(A)



(B)

7.8. CASE No. HW 8

Study type:	Infection		
Clinical indication:	Wrist pain and inflammation		
Keywords:	Septic arthritis		
SPECT/CT system:	Siemens Symbia T6	Tracer:	^{99m}Tc -DPD
Uptake:	240 min	Dose:	719 MBq
Tube loading:	53 mAs	Tube voltage:	130 kVp

Short clinical history

A 64 year old male patient presenting with swelling and tenderness of the wrist, suggesting wrist arthritis. The patient had been previously diagnosed with osteoarthritis of the hands, but there was no previous history of inflammatory joint disorder.

Findings

Planar image (A): Shows diffusely increased uptake in the right wrist, and to a lesser extent in the right hand.

SPECT/CT (B, C, D): Show diffusely increased uptake in the right wrist and CMC joints. CT shows synovial thickening, extensive carpal and carpometacarpal chondrolysis and loss of integrity of the carpal structure, consistent with septic arthritis.

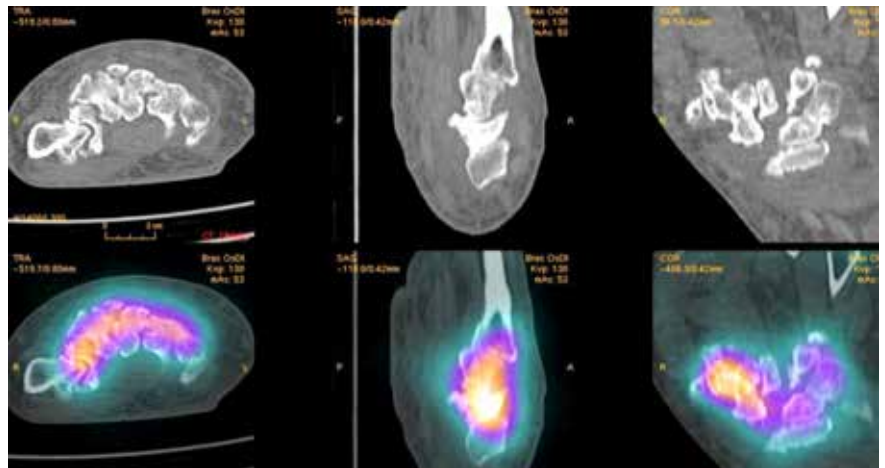
Outcome and teaching point

Empiric antibiotherapy was started, with a favourable clinical evolution.

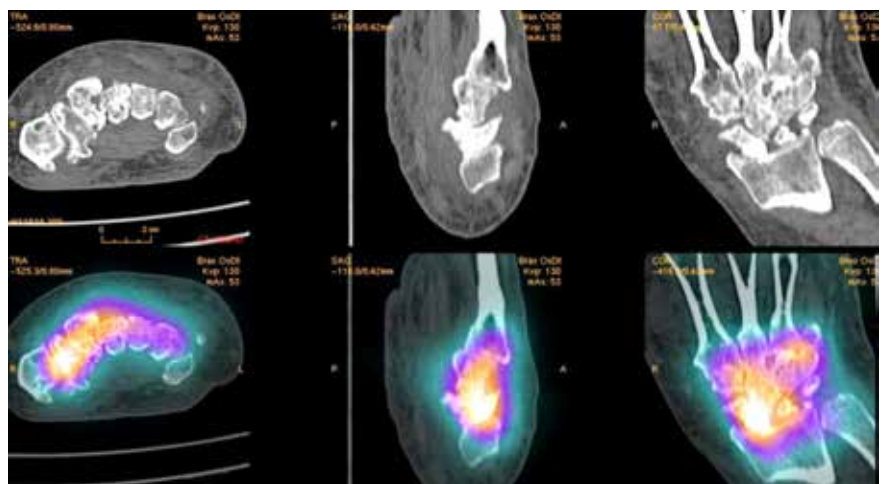
Note the CT study is highly suggestive of septic arthritis, whereas the metabolic anomalies are non-specific.



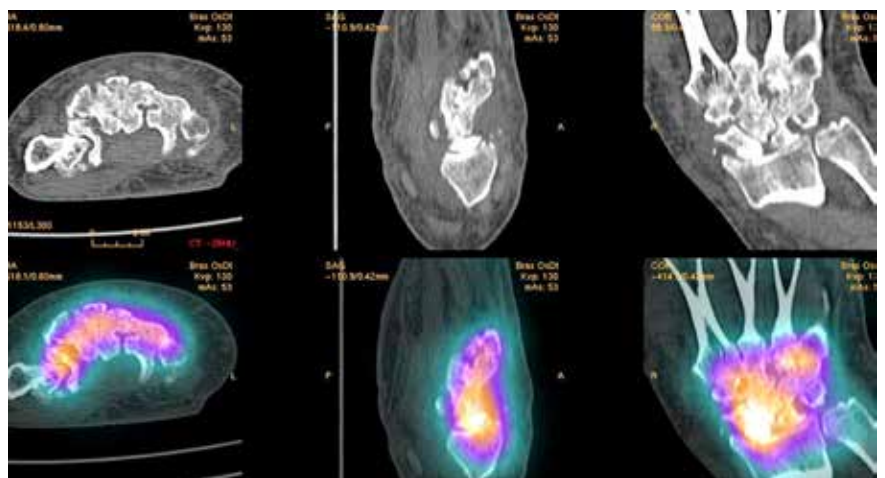
(A)



(B)



(C)



(D)

7.9. CASE No. HW 9

Study type:	Traumatology Degenerative		
Clinical indication:	Chronic wrist pain		
Keywords:	Post-traumatic osteoarthritis		
SPECT/CT system:	Siemens Symbia T6	Tracer:	^{99m}Tc -DPD
Uptake:	240 min	Dose:	719 MBq
Tube loading:	34 mAs	Tube voltage:	130 kVp

Short clinical history

A 53 year old male patient had fractured his left wrist 31 years earlier. The patient now complained of chronic pain, worsening over the previous few weeks.

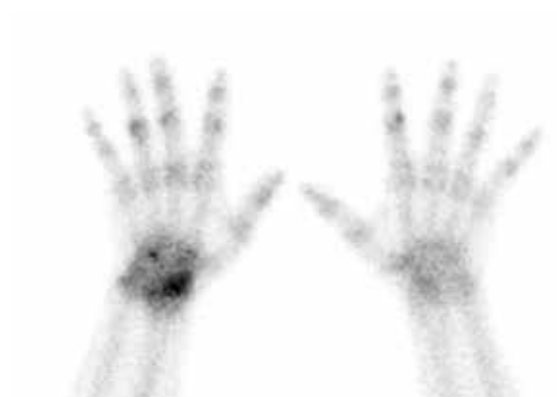Findings

Planar image (A): Shows diffusely increased uptake in the left wrist, especially in the radial aspect.

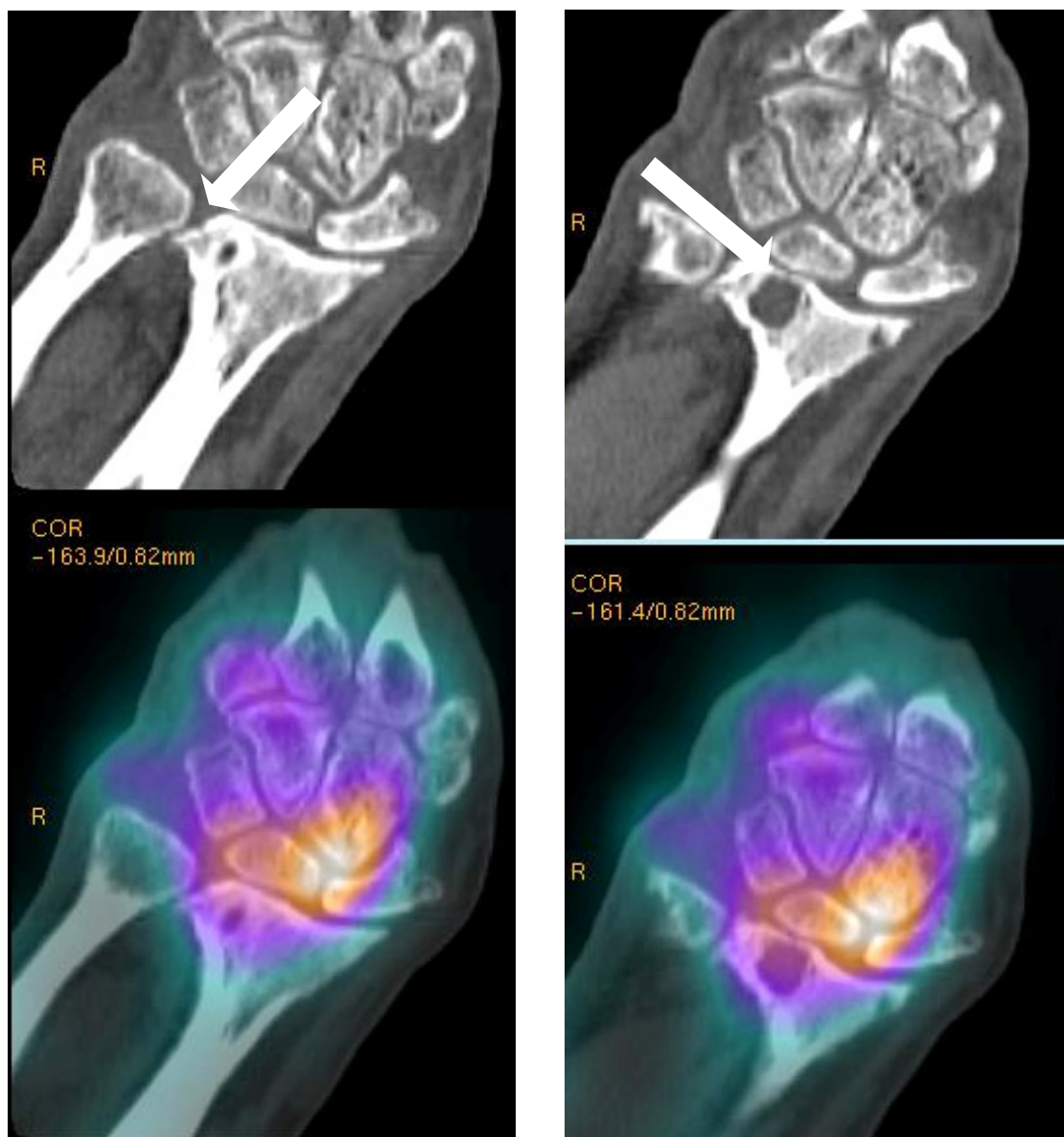
SPECT/CT (B): The main focus of increased bone remodelling is located at the articulation between the capitate, scaphoid and lunate, whereas the most marked degenerative changes on CT are observed at the level of the radioulnar and radiocarpal joints (arrows).

Teaching point

Note in this case, the metabolic information shows the current area of active bone remodelling despite extensive morphological osteoarthritis.



(A)



(B)

7.10. CASE No. HW 10

Study type:	Orthopaedics Degenerative		
Clinical indication:	Pain in both wrists post left-sided reduction osteotomy		
Keywords:	Pain Surgery		
SPECT/CT system:	General Electric Discovery 670	Tracer:	^{99m}Tc -DPD
Uptake:	180 min	Dose:	650 MBq
Tube loading:	120–400 mAs	Tube voltage:	120 kVp

Short clinical history

A 23 year old male patient with wrist pain on both sides. S/p reduction osteotomy of the left ulna. There was clinical suspicion for lunate malacia again on the left side owing to prior impaction of the previously prolonged ulna.

Findings

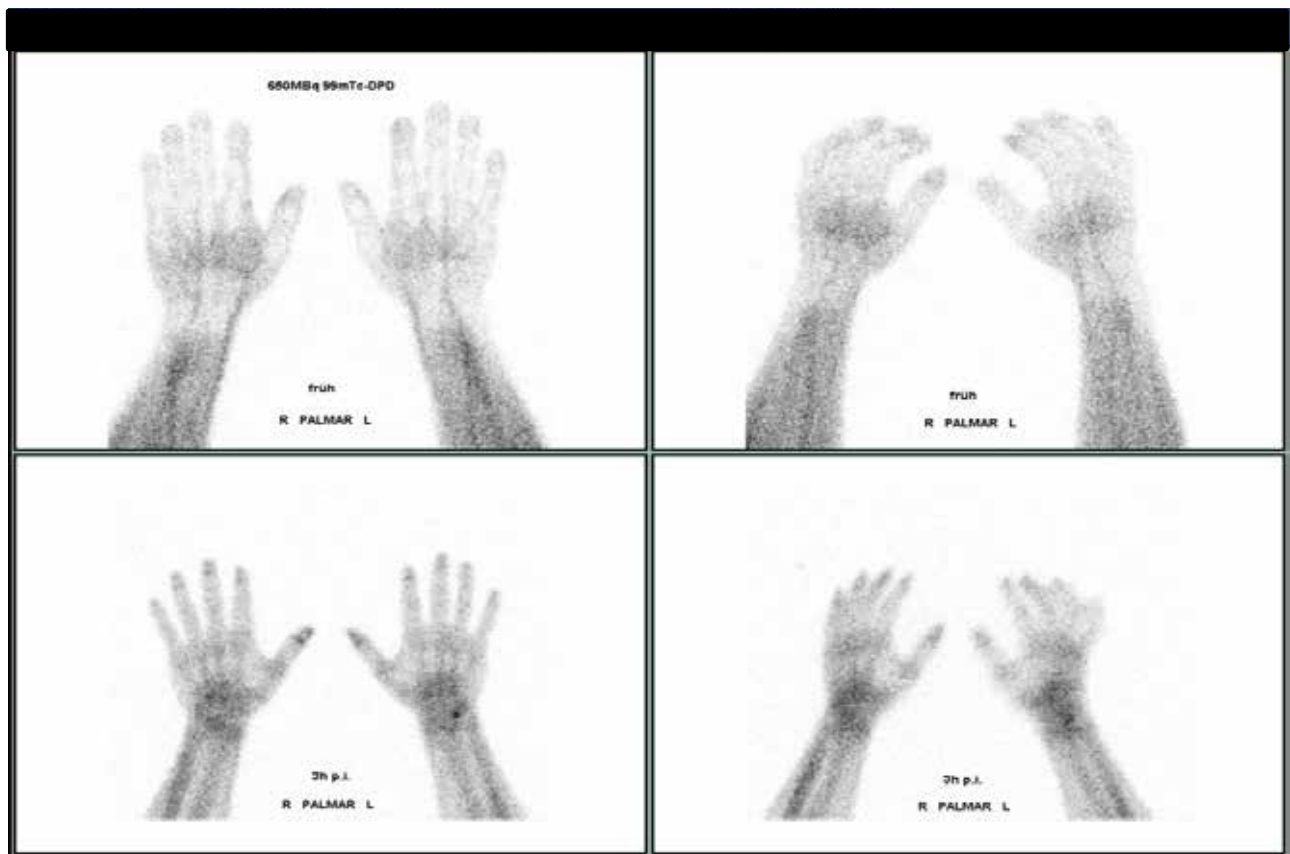
Planar bone scan (A): Shows additional uptake within the lunate bone on the right side owing to ulnar impaction. In addition, there is a subcortical degenerative cyst due to the impaction. Thus, the ulna is too long on the right side as well.

SPECT/CT (B): Shows physiologic uptake in the left ulna post reduction osteotomy. No signs of impaction or malacia of the lunate bone.

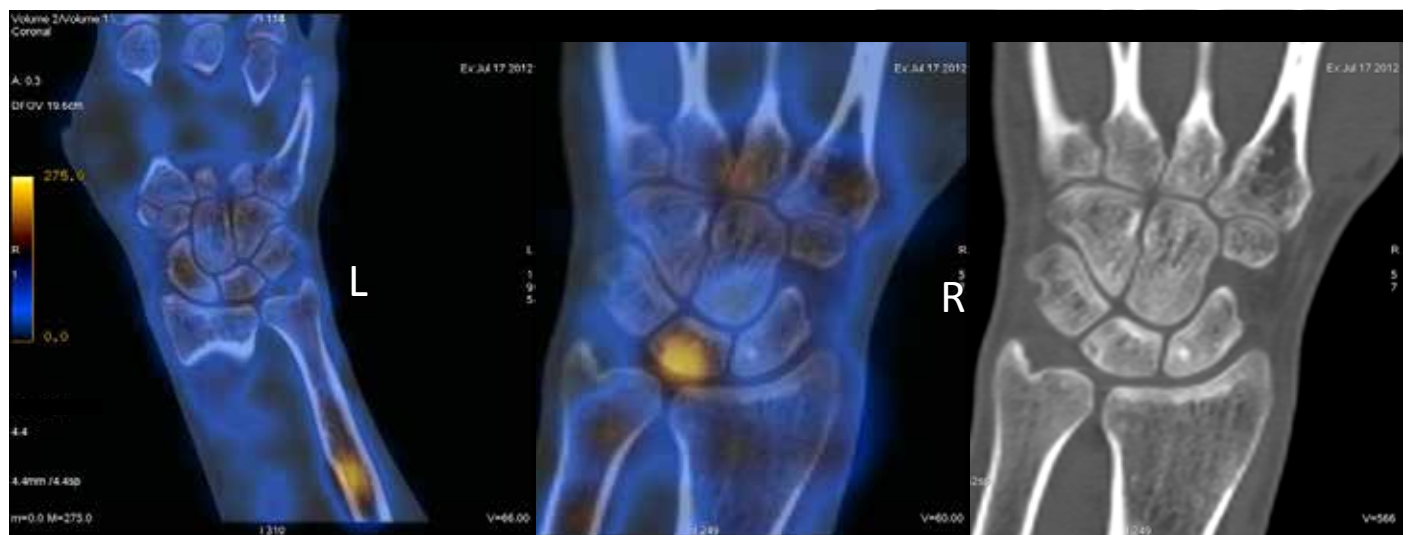Outcome and teaching point

Change in treatment plan and additional reduction osteotomy performed in the right ulna as well. No further imaging follow-up.

Note SPECT/CT identified the cause of pain on the right side and excluded the suspected pathology in the left wrist.



(A)



(B)

7.11. CASE No. HW 11

Study type:	Orthopaedics Degenerative		
Clinical indication:	Left-sided pain post removal of surgical plate after trauma		
Keywords:	Pain Trauma		
SPECT/CT system:	General Electric Discovery 670	Tracer:	^{99m} Tc-DPD
Uptake:	180 min	Dose:	650 MBq
Tube loading:	120–400 mAs	Tube voltage:	120 kVp

Short clinical history

A 31 year old male patient with persistent pain after intra-articular radial fracture 30 months earlier. The surgical plate has already been removed. MRI of the wrist was reported inconclusive without bone oedema or significant damage to the TFCC. The intracarpal ligaments are intact.

Findings

MRI of the wrist (A): Inconclusive.

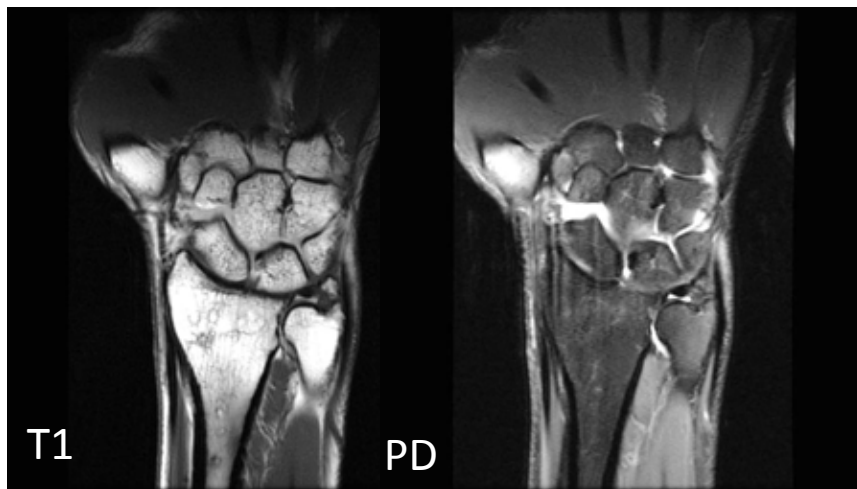
Planar bone scan (B): Shows only mild uptake in the distal radius.

SPECT/CT (C): Shows mild, physiologic uptake in the left distal radius post removal of the surgical plate. Mild uptake also in the DRUJ. In addition, joint space narrowing, remodelling of the medial radial surface and cortical irregularities (arrow). Overall indicative for post-traumatic DRUJ arthritis.

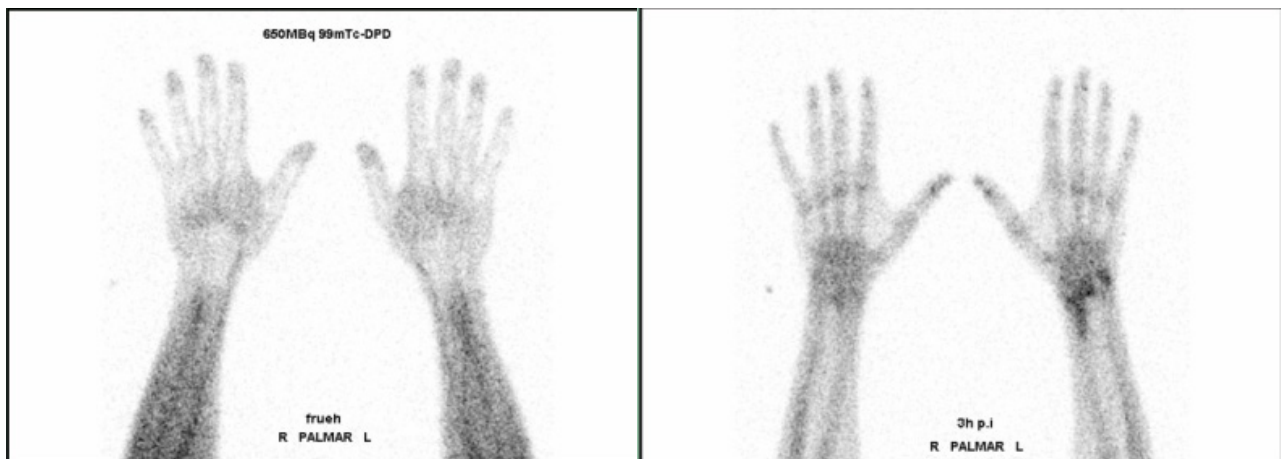
Outcome and teaching point

MRI of the wrist for unspecific wrist pain is highly sensitive but not very specific.

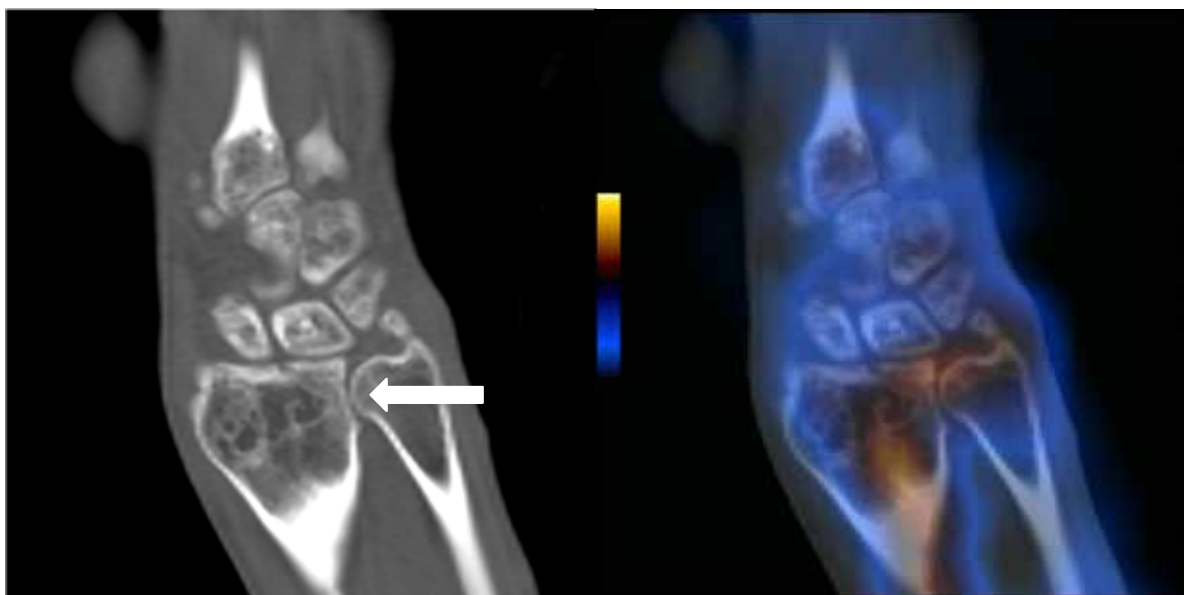
Note the SPECT/CT was able to highlight the underlying pathology specifically. An additional MRI confirmed the SPECT/CT findings of post-traumatic DRUJ arthritis based on joint narrowing, bone remodelling, cartilage destruction and cortical irregularities.



(A)



(B)



(C)

7.12. CASE No. HW 12

Study type:	Orthopaedics Degenerative		
Clinical indication:	Right-sided wrist pain		
Keywords:	Ulnar impaction		
SPECT/CT system:	Philips Brilliance XCT	Tracer:	^{99m} Tc-DPD
Uptake:	180 min	Dose:	678 MBq
Tube loading:	100 mAs	Tube voltage:	80 kVp

Short clinical history

A 43 year old male patient with pain in the right wrist. No recent history of trauma.

Findings

Planar bone scan (A): Shows elevated focal uptake in the right wrist.

The arthro-CT (B) and SPECT/CT (C): Confirm the uptake in the lunate bone as well as a corresponding rupture of the scapholunate ligament (arrow), the TFCC (arrow) and the cartilage defect at the lunate.

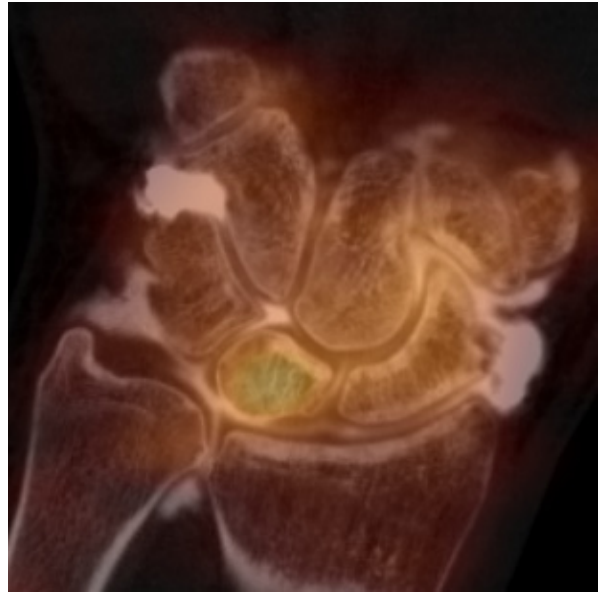
SPECT/CT arthrography and MR arthrography (D) findings correspond with those of an ulnar impaction.

Teaching point

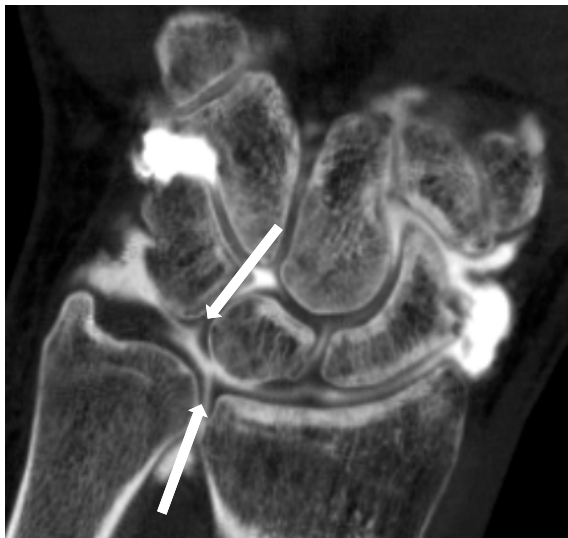Note full diagnostic arthro-CT with intra-articular contrast media is possible with SPECT/CT and has the same overall diagnostic accuracy compared to arthro-MR.



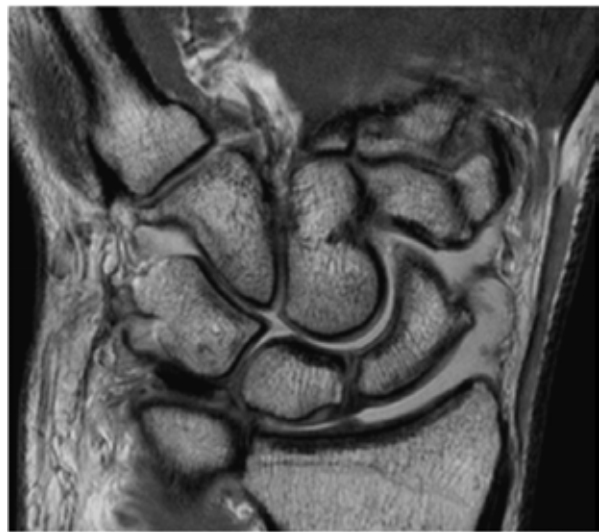
(A)



(C)



(B)



(D)

8. KNEE

8.1. CASE No. K 1

Study type:	Orthopaedics Oncology		
Clinical indication:	Restaging for breast cancer Gonarthrosis		
Keywords:	Osteoarthritis Fracture		
SPECT/CT system:	Siemens Symbia T2	Tracer:	^{99m}Tc -DPD
Uptake:	180 min	Dose:	677 MBq
Tube loading:	120 mAs	Tube voltage:	80 kVp

Short clinical history

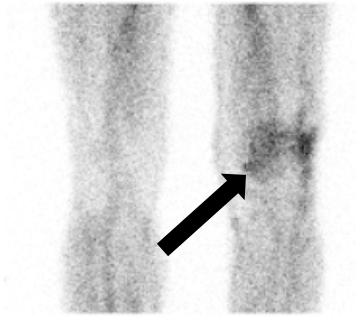
A 79 year old female patient with a history of breast cancer underwent a bone scan for restaging purposes. Owing to increasing pain in the left knee and thorax following a car accident, a 2 phase bone scan was performed.

Findings

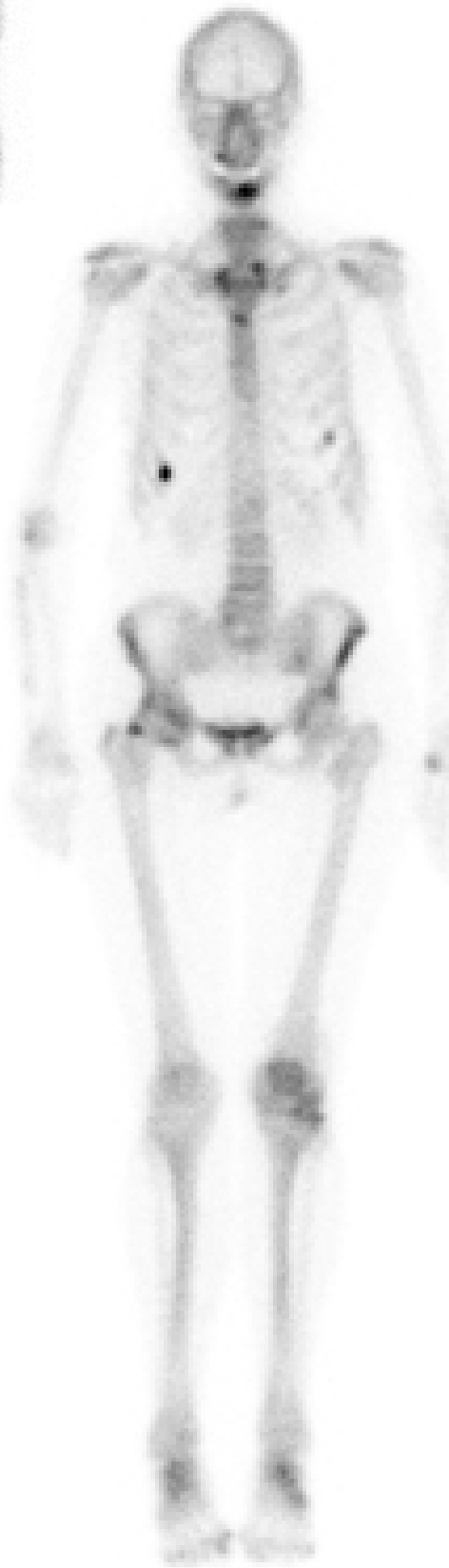Planar image of blood pool (A): Shows focal uptake in region of left knee (arrow) representing synovitis.

Late planar image (B): Shows intense uptake in the left knee. Further foci were found on the 6th right rib, 7th left rib, mandible, both hips and lumbosacral region.

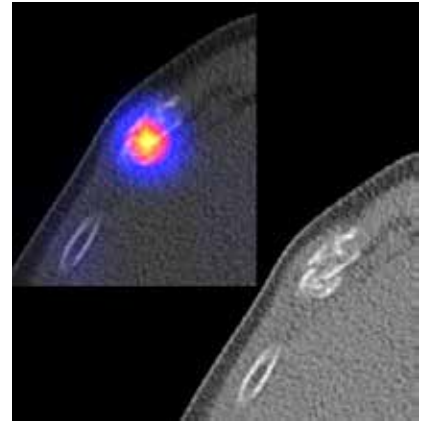
SPECT/CT: Shows a recent rib fracture (C) and a lateral gonarthrosis (D).



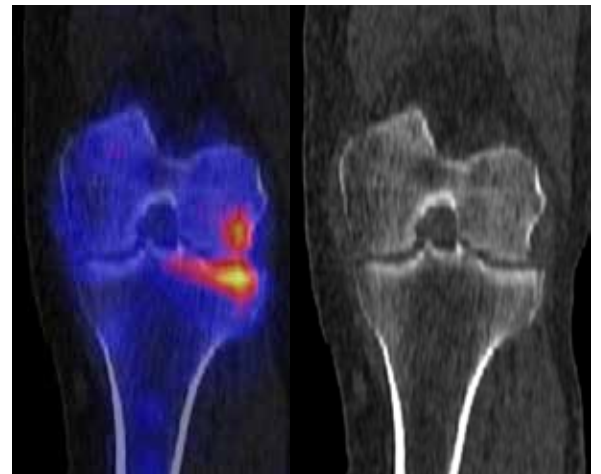
(A)



(B)



(C)



(D)

8.2. CASE No. K 2

Study type:	Oncology		
Clinical indication:	Staging		
Keywords:	Bone infarction		
SPECT/CT system:	Siemens Symbia T2	Tracer:	^{99m}Tc -DPD
Uptake:	180 min	Dose:	652 MBq
Tube loading:	120 mAs	Tube voltage:	80 kVp

Short clinical history

A 64 year old female patient with first diagnosis of breast cancer.

Findings

Planar image (A): Shows focal uptake in the left femur (arrow).

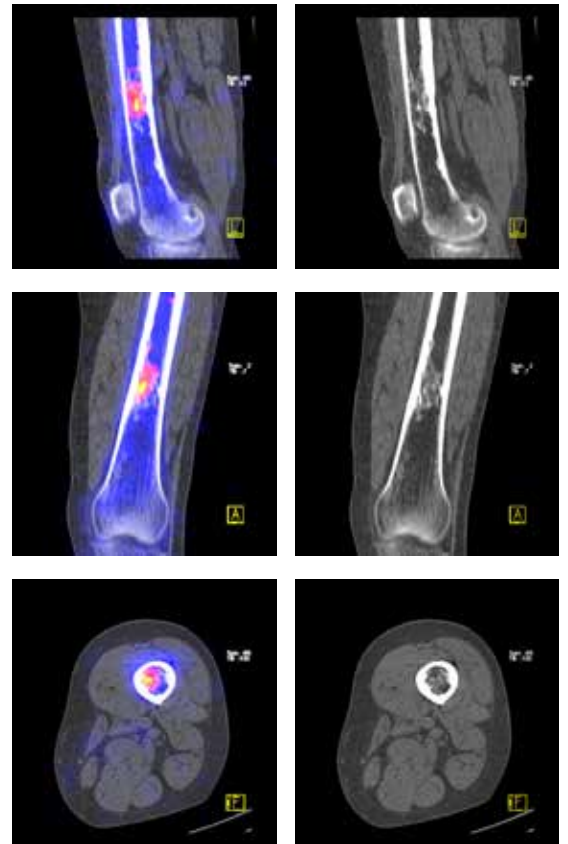
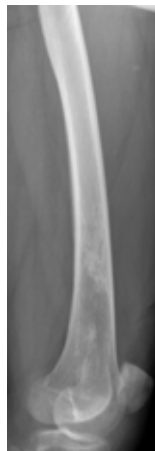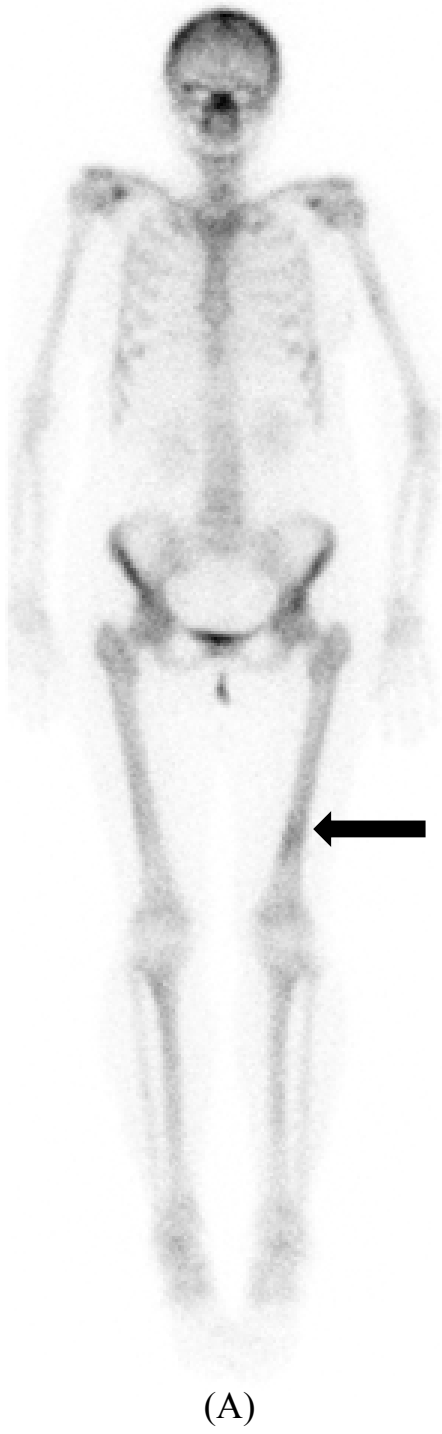
Planar radiography (B): Shows typical appearance of a bone infarction.

SPECT/CT (C): Shows spotty ossifications in bone marrow representing bone infarction. No osseous metastasis.

Outcome and teaching point

No treatment.

Note SPECT/CT is more specific than planar scintigraphy to rule out osseous metastases.



8.3. CASE No. K 3

Study type:	Orthopaedic		
Clinical indication:	Knee pain on both sides Post arthroplasty in the left knee		
Keywords:	Arthroplasty		
SPECT/CT system:	Siemens Symbia T2	Tracer:	^{99m}Tc -DPD
Uptake:	180 min	Dose:	522 MBq
Tube loading:	120 mAs	Tube voltage:	80 kVp

Short clinical history

A 57 year old male patient with history of left-sided knee arthroplasty 1 year earlier. The patient complained of continuous pain in both knees.

Findings

Planar image of blood pool (A): Shows focal uptake in the region of the left tibial knee replacement.

Late planar image (B): Shows uptake at the left tibial region close to the prosthesis and in the medial compartment of the right knee.

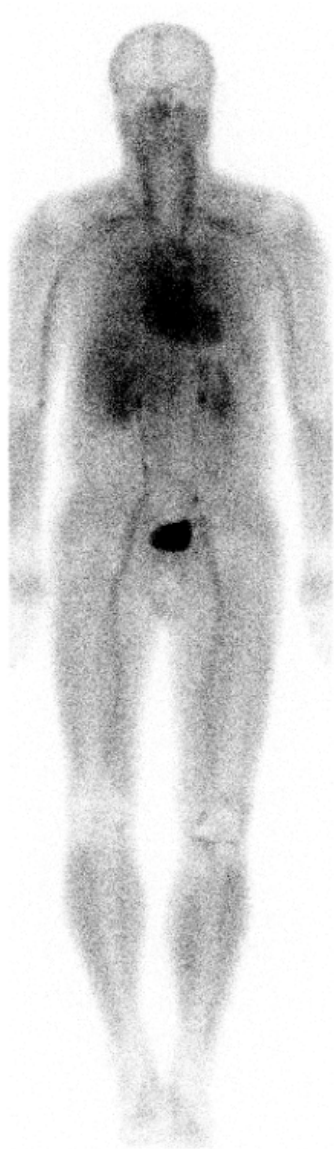SPECT/CT (C): Shows uptake at the tibial prosthesis interface that was not continuous. Metal implant artefacts on CT. No loosening of prosthesis but delayed healing with mild synovitis.

Uptake in the medial compartment of the right knee consistent with osteoarthritis.

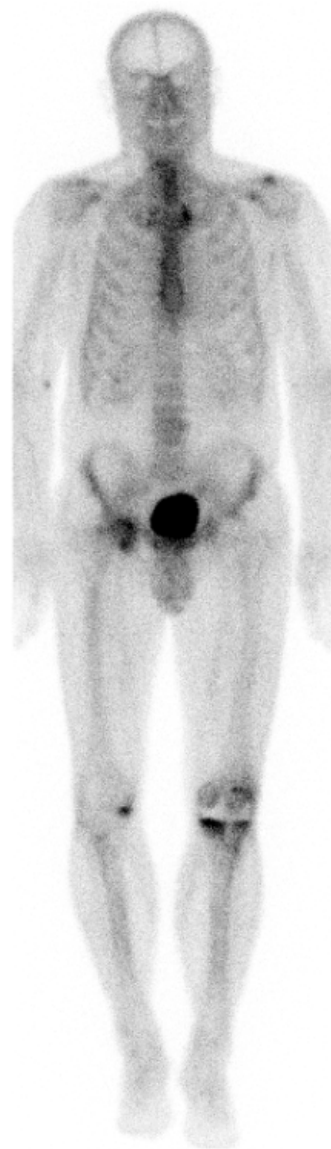Outcome and teaching point

No treatment. Wait and follow-up.

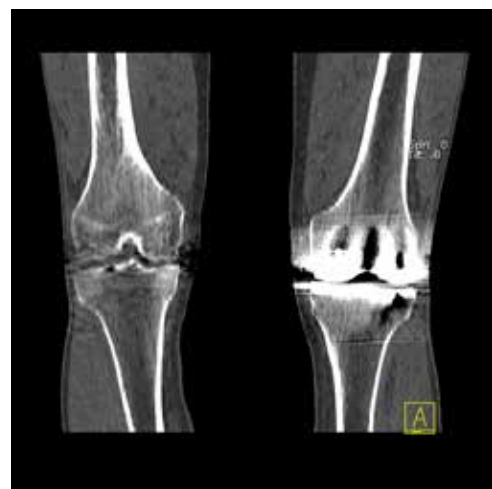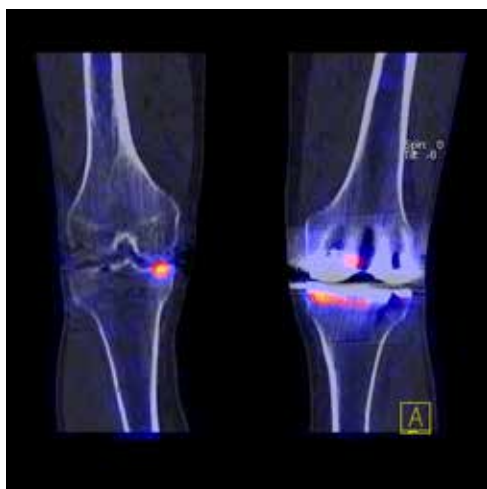Note the case represents a classic example of how a knee prosthesis presents itself in bone scintigraphy in the first year post surgery.



(A)



(B)



(C)

8.4. CASE No. K 4

Study type:	Orthopaedics Infection		
Clinical indication:	Comminuted fracture of the left tibia 37 years earlier Recurrent pretibial ulcer		
Keywords:	Osteomyelitis		
SPECT/CT system:	Siemens Symbia T2	Tracer:	^{99m}Tc -DPD
Uptake:	180 min	Dose:	534 MBq
Tube loading:	120 mAs	Tube voltage:	80 kVp

Short clinical history

An 80 year old female patient with history of comminuted tibial fracture 37 years earlier. The patient is now presenting with a recurrent pretibial ulcer.

Findings

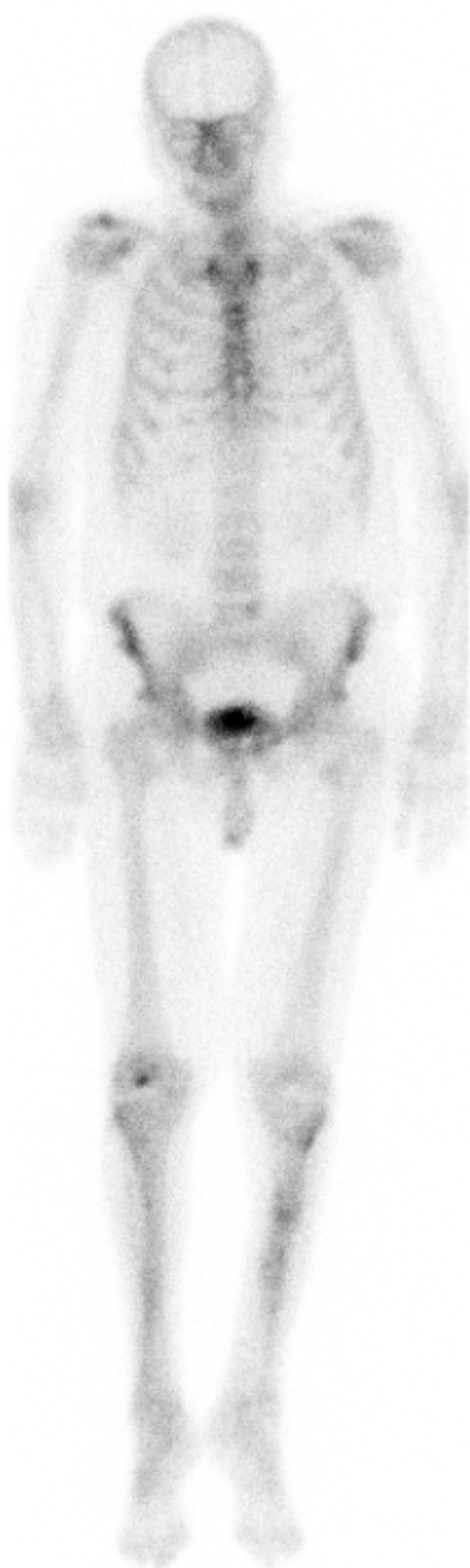Planar image (A): Shows mild diffuse uptake in the upper part of the left tibia.

SPECT/CT (B): Shows inhomogeneous tracer uptake with multiple foci in grossly deformed tibia with abolished trabecular structure and cortical defects (arrow).

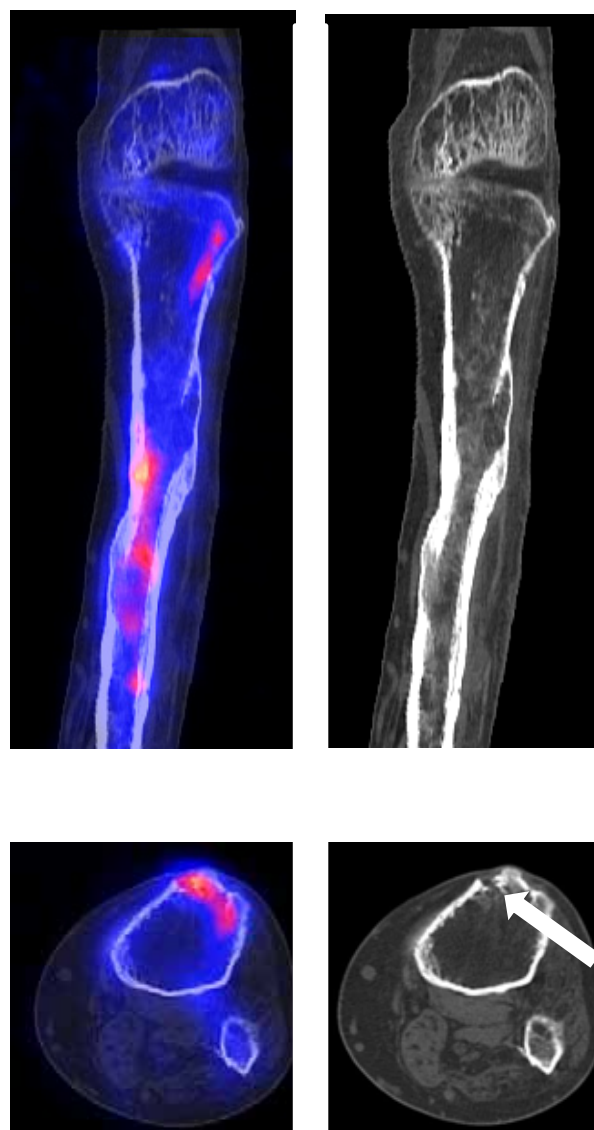
Outcome and teaching point

Antibiotic treatment of chronic osteomyelitis.

Note without SPECT/CT the interpretation of the increased bone metabolism would be unspecific.



(A)



(B)

8.5. CASE No. K 5

Study type:	Orthopaedic Traumatology		
Clinical indication:	Gonarthrosis worsening in the previous 2 weeks		
Keywords:	Fracture Ligament tear		
SPECT/CT system:	Siemens Symbia T2	Tracer:	^{99m}Tc -DPD
Uptake:	180 min	Dose:	516 MBq
Tube loading:	120 mAs	Tube voltage:	80 kVp

Short clinical history

A 79 year old female patient previously diagnosed with gonarthrosis. The patient's condition was particularly aggravated in the previous 2 weeks.

Findings

Planar image (A): Shows intense tracer uptake in the medial tibial plateau (long arrow) and an intercondylar focus (short arrow).

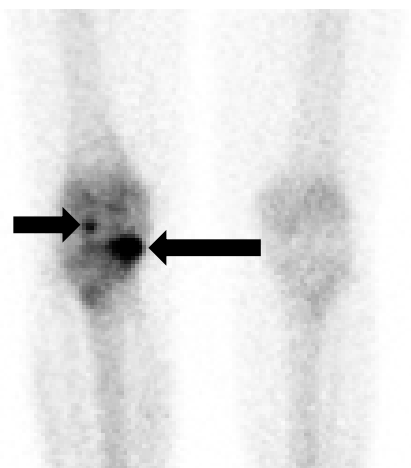
SPECT/CT (B): Shows exact area of focal tracer uptake in the medial tibial plateau with a fracture line in CT (arrow) representing fracture of the tibial head.

Furthermore, intercondylar focal uptake (C) represents an anterior cruciate ligament tear with osseous avulsion (arrows).

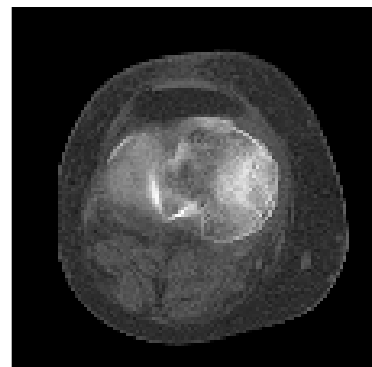
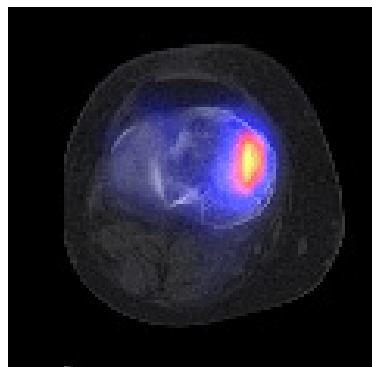
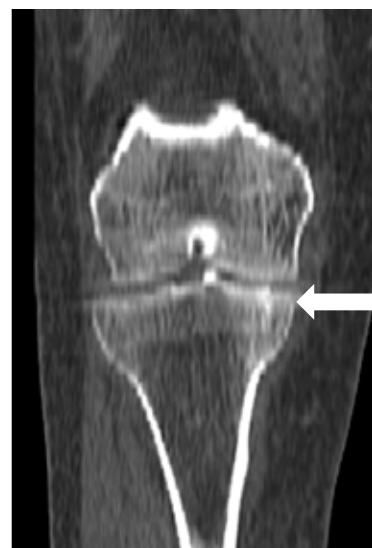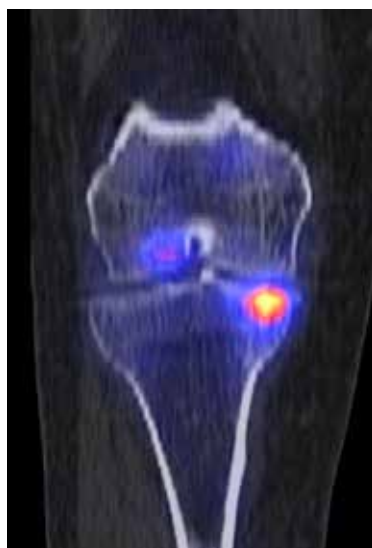Outcome and teaching point

Surgery was performed.

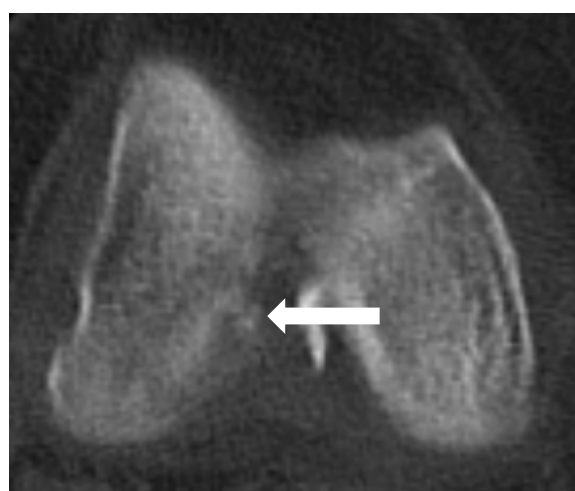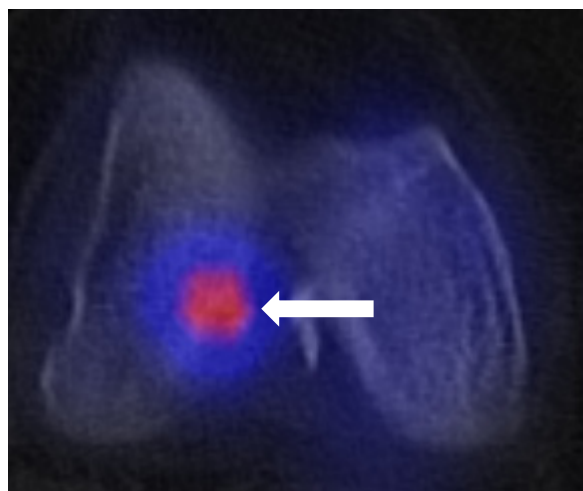
Note SPECT/CT allows the diagnosis of complex post-traumatic injuries.



(A)



(B)



(C)

8.6. CASE No. K 6

Study type:	Orthopaedics		
Clinical indication:	Knee pain		
Keywords:	Osgood–Schlatter disease		
SPECT/CT system:	Siemens Symbia T2	Tracer:	^{99m}Tc -DPD
Uptake:	240 min	Dose:	940 MBq
Tube loading:	80 mAs	Tube voltage:	130 kVp

Short clinical history

A 20 year old male patient with a painful knee precisely located at the right anterior tibial tuberosity. The patient was also an avid football player.

Findings

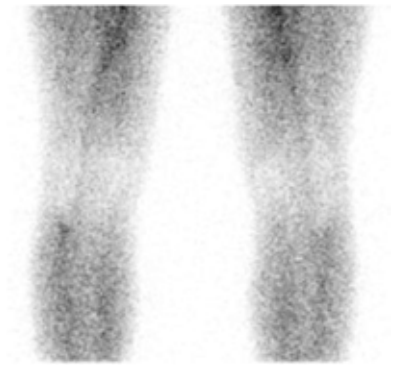
Blood pool and late planar images (A, B): Increased tracer uptake on the anterior tibial tuberosity.

SPECT/CT (C): No corresponding CT anomaly. The findings are consistent with Osgood–Schlatter disease.

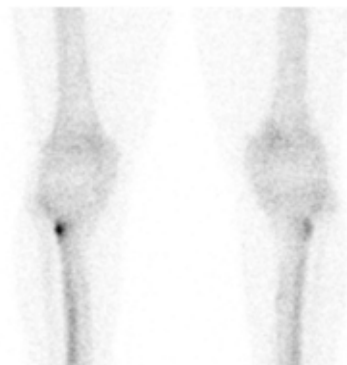
Outcome and teaching point

Conservative treatment.

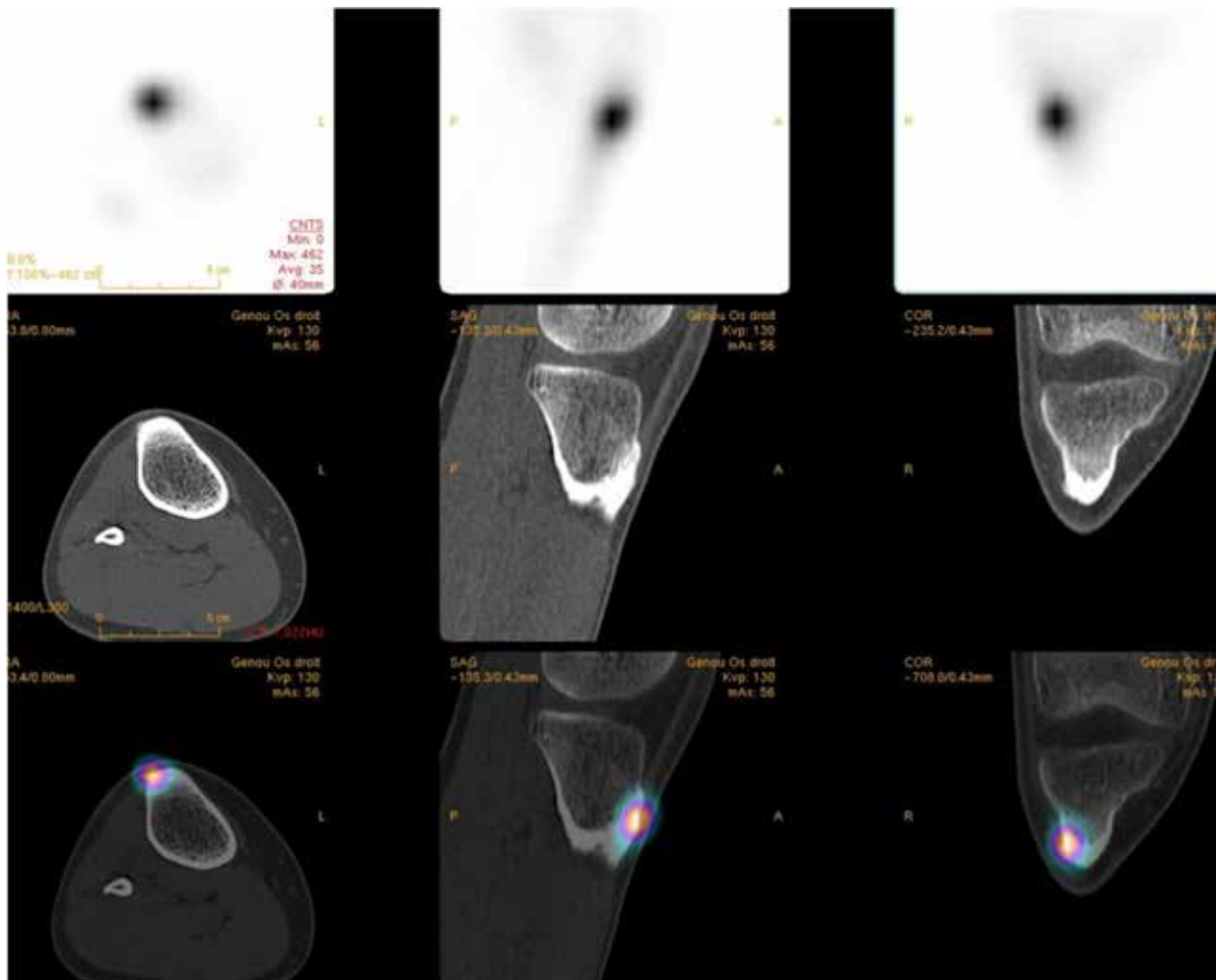
Note in this case, the diagnosis is quite evident based on the scintigraphy, whereas the CT basically excludes any other pathology.



(A)



(B)



(C)

8.7. CASE No. K 7

Study type:	Traumatology		
Clinical indication:	Pain in the right lower extremity		
Keywords:	Fracture		
SPECT/CT system:	Siemens Symbia T6	Tracer:	^{99m}Tc -DPD
Uptake:	240 min	Dose:	800 MBq
Tube loading:	97 mAs	Tube voltage:	130 kVp

Short clinical history

A 70 year old female patient with history of breast cancer 3 years earlier (hormone therapy). The patient had recently tripped and fallen to the ground.

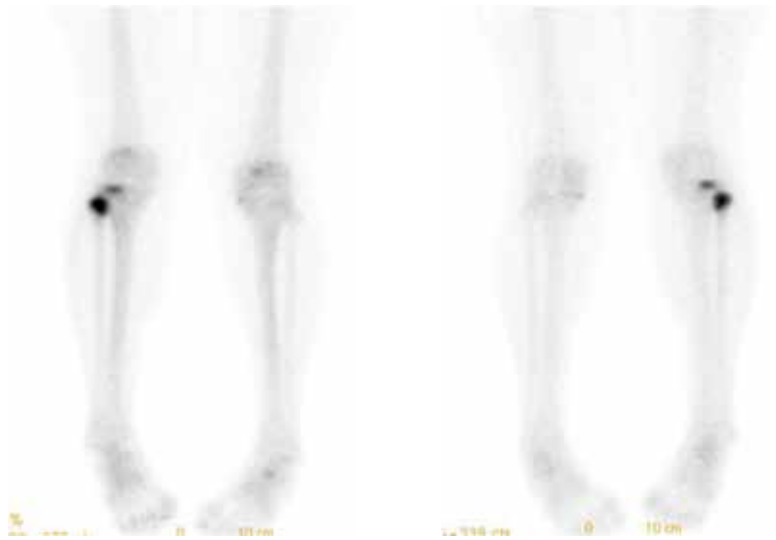
Findings

Planar (anterior and posterior, A, B): Shows increased tracer uptake at the head of the right fibula and the lateral plateau of the right tibia.

SPECT/CT (C): The fibular focus of increased activity corresponds to a non-displaced fracture, whereas no radiologic lesion is seen on the tibia, consistent with a bone bruise (arrow).

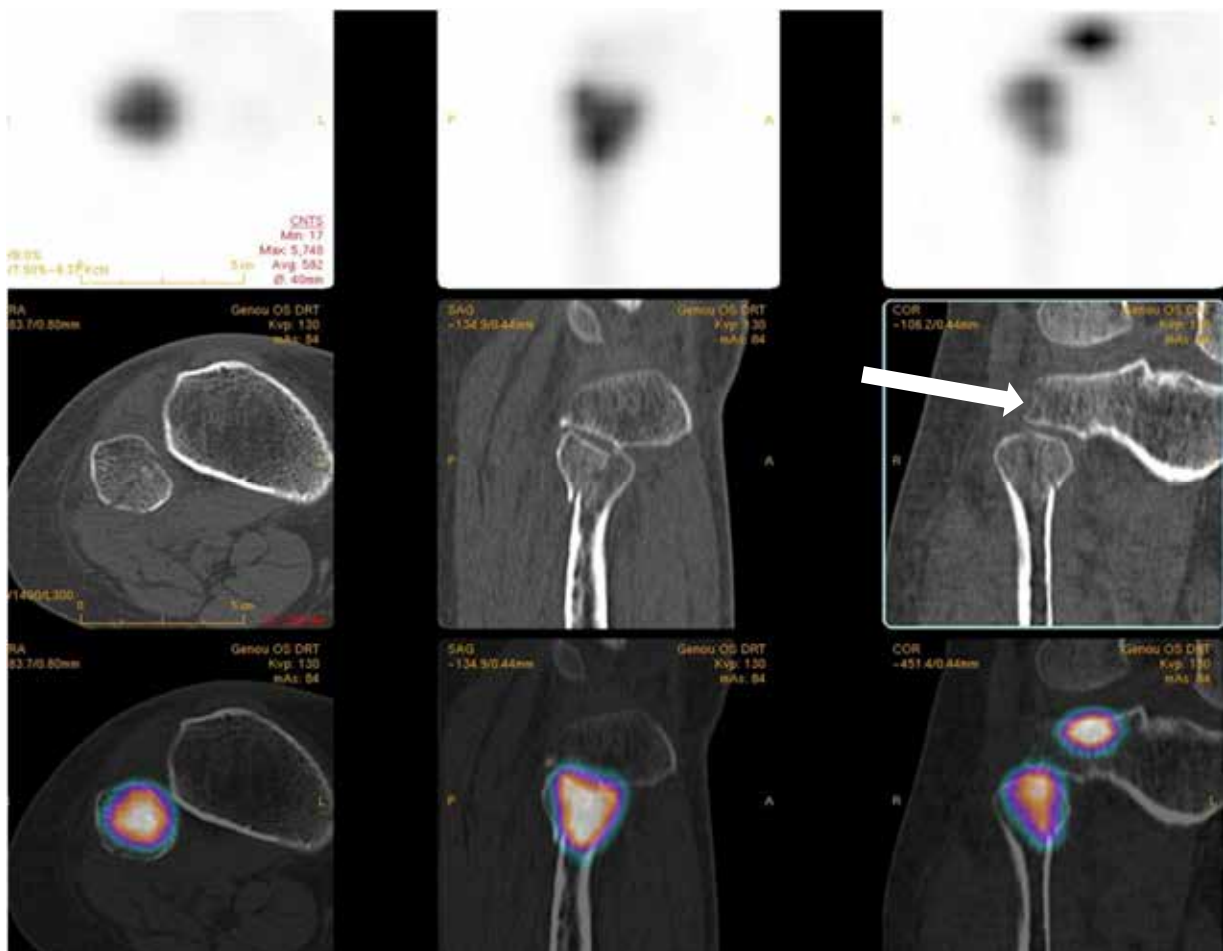
Teaching point

Note the combination of the metabolic and morphologic studies allows for a precise and comprehensive assessment of the post-traumatic damages.



(A)

(B)



(C)

8.8. CASE No. K 8

Study type:	Degenerative		
Clinical indication:	Knee pain		
Keywords:	Osteoarthritis		
SPECT/CT system:	Siemens Symbia T6	Tracer:	^{99m}Tc -DPD
Uptake:	240 min	Dose:	738 MBq
Tube loading:	75 mAs	Tube voltage:	130 kVp

Short clinical history

A 63 year old male patient with bilateral gonalgia for approximately 2 years. The patient had never undergone further investigation.

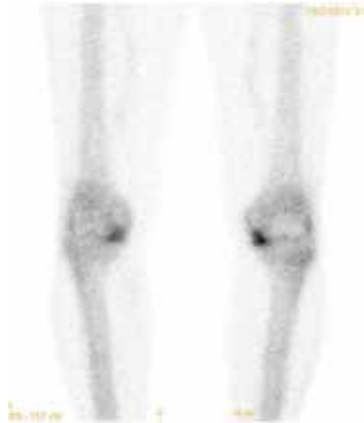Findings

Planar (A): Shows increased uptake in the medial compartment of both knees ($L > R$).

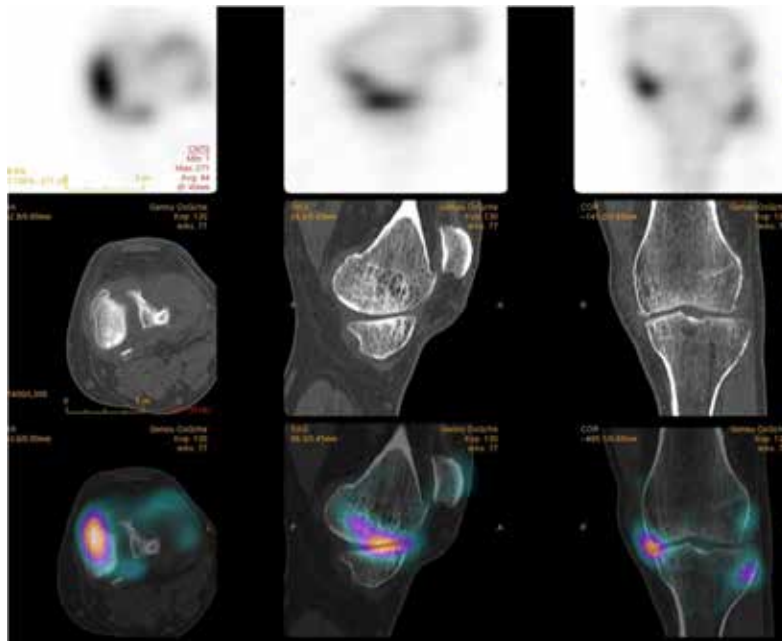
SPECT/CT: Knee osteoarthritis, predominant in the medial femorotibial joints (B: left knee), degenerative changes in the superior tibiofibular joint (C: left knee).

Teaching point

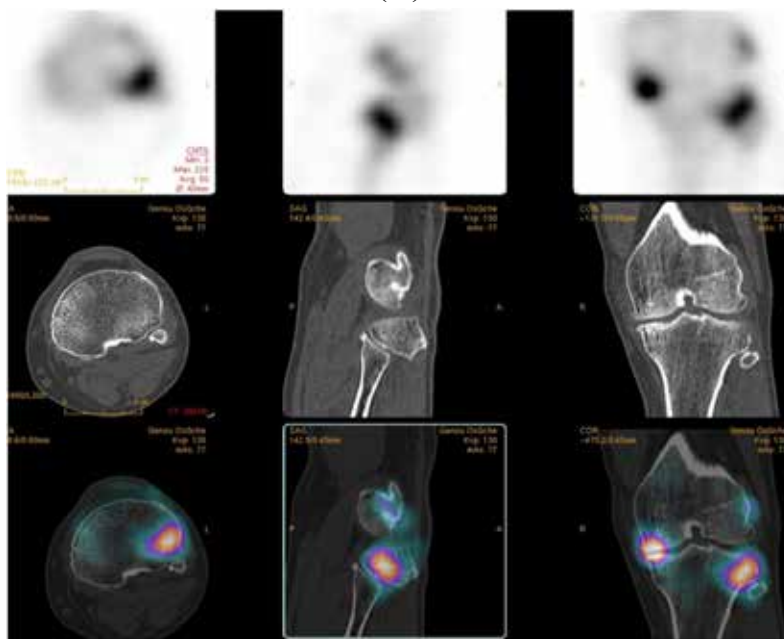
This case shows the typical pattern of degenerative knee osteoarthritis.



(A)



(B)



(C)

8.9. CASE No. K 9

Study type:	Traumatology		
Clinical indication:	Knee pain		
Keywords:	Ligament tear		
SPECT/CT system:	Siemens Symbia T6	Tracer:	^{99m}Tc -DPD
Uptake:	240 min	Dose:	747 MBq
Tube loading:	44 mAs	Tube voltage:	130 kVp

Short clinical history

A 52 year old female patient fell from a ladder 6 weeks earlier. The patient complained from persistent pain in the left knee.

X ray and MRI are both negative.

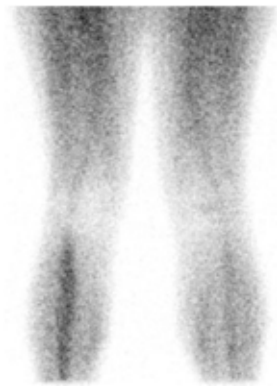Findings

Blood pool planar image is normal (A): Shows that there is mild focus of increased uptake on the left lateral condyle on the late planar image (B).

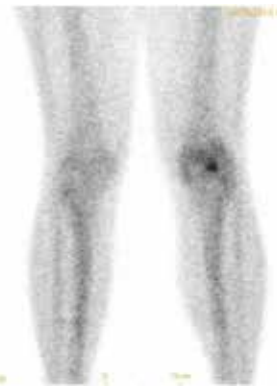SPECT/CT (C, D): Shows foci at the insertion sites (femur and tibia, arrows) of the posterior cruciate ligament, without corresponding CT anomalies. This is consistent with a tear.

Teaching point

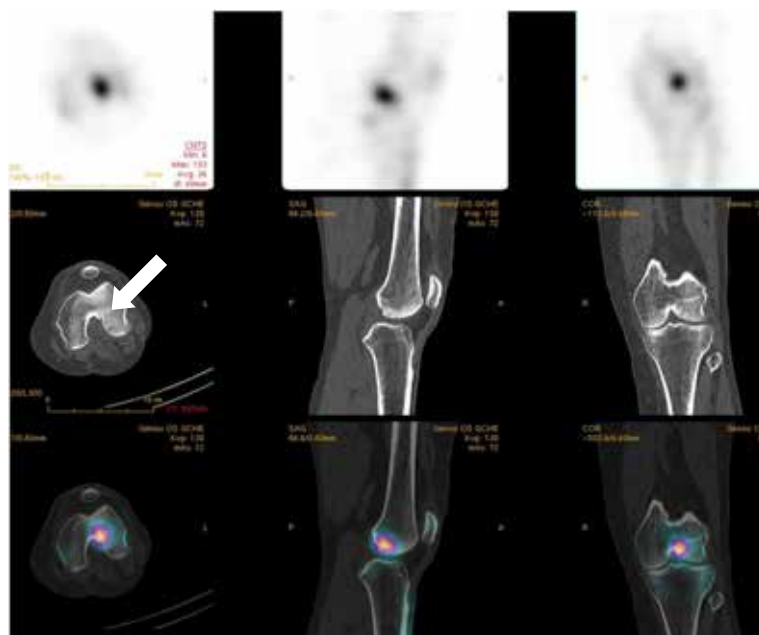
Note the functional study is highly sensitive, but even if there are no, or minimal, morphologic changes on CT, it is needed to precisely locate the areas of increased bone remodelling to facilitate the diagnosis.



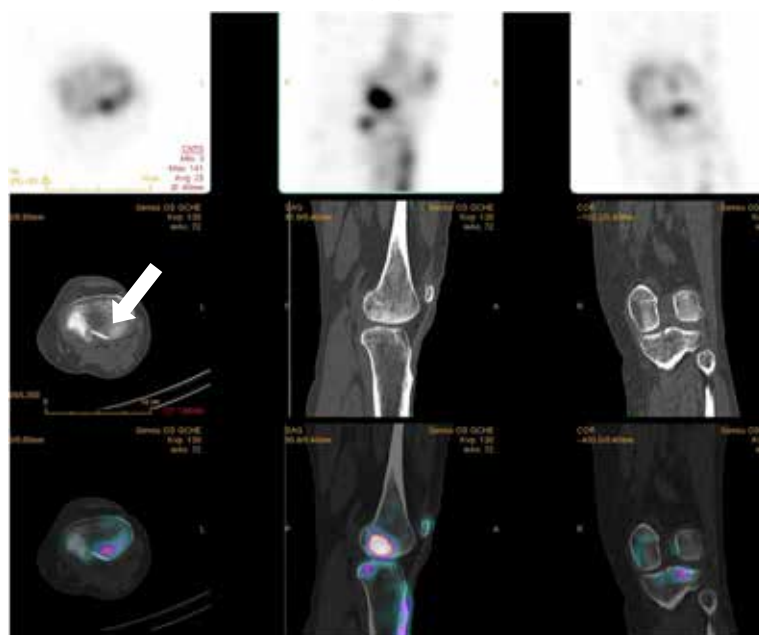
(A)



(B)



(C)



(D)

8.10. CASE No. K 10

Study type:	Orthopaedics		
Clinical indication:	Pain and swelling in the leg		
Keywords:	Fracture		
SPECT/CT system:	Siemens Symbia T6	Tracer:	^{99m}Tc -DPD
Uptake:	240 min	Dose:	770 MBq
Tube loading:	76 mAs	Tube voltage:	130 kVp

Short clinical history

A 70 year old female patient with history of breast cancer treated with surgery and adjuvant radiation and chemotherapy 7 years earlier. She presented with pain and swelling in the right leg. There was no history of trauma.

Findings

Blood pool planar image (A): Shows increased activity in the right leg.

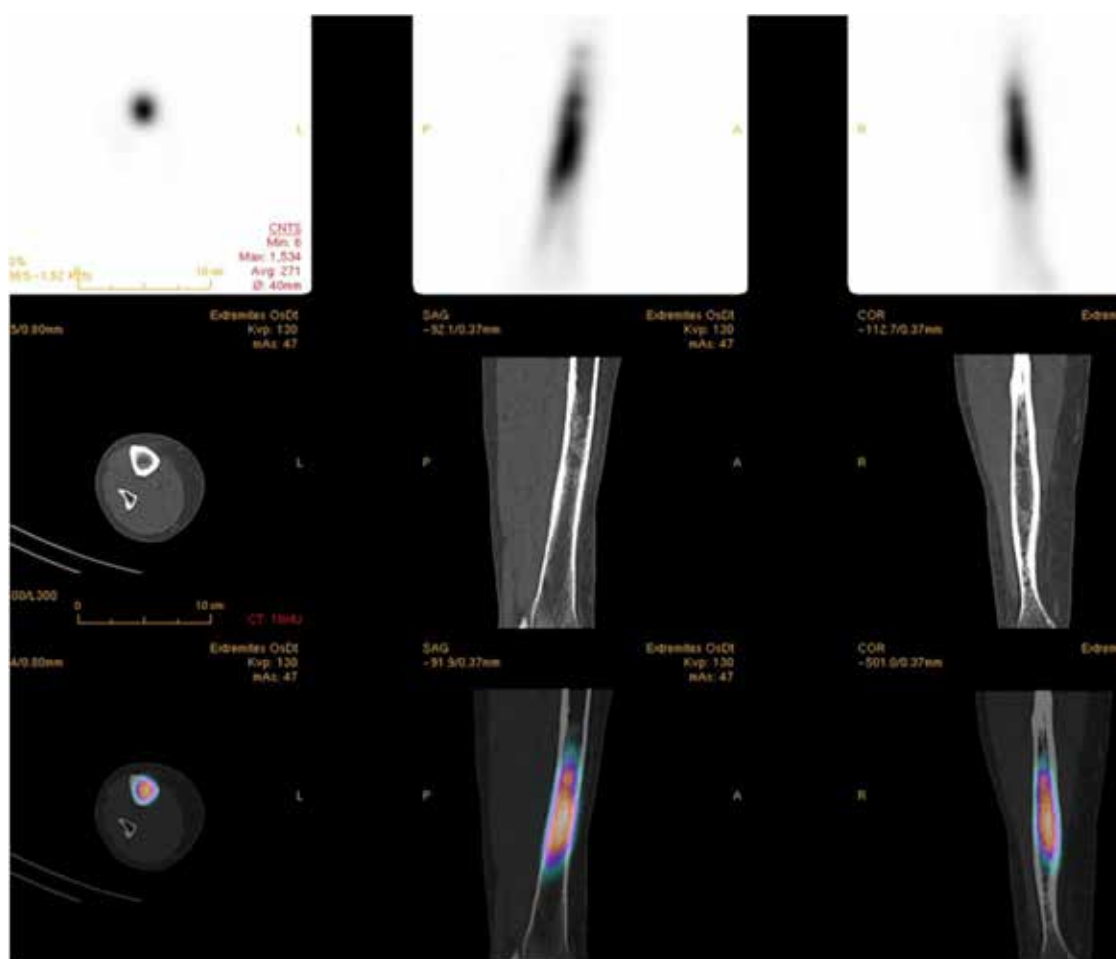
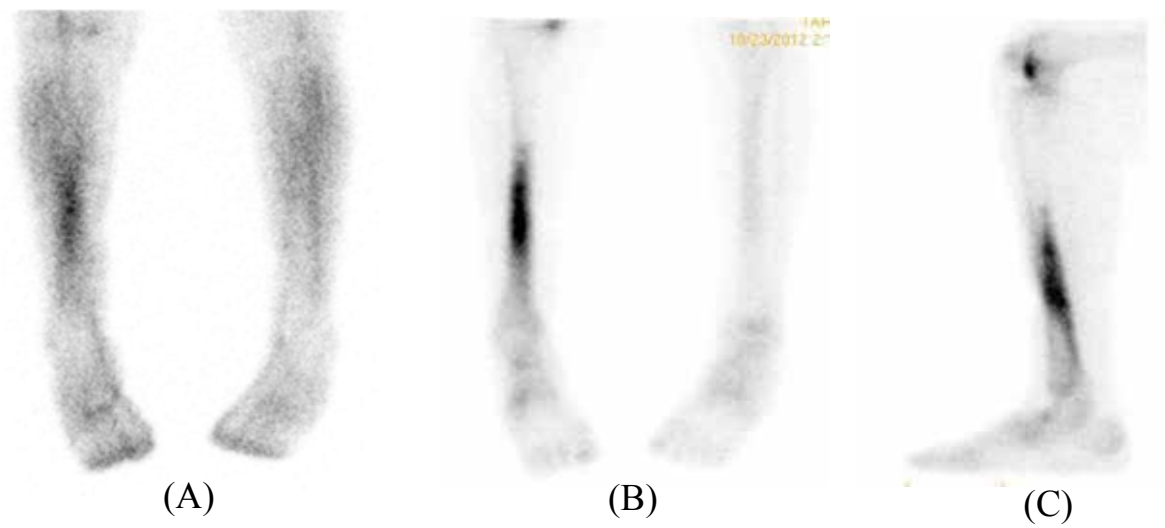
Planar bone scan and SPECT (B, C): Show highly increased uptake in the right tibia.

CT (D): Shows a very subtle periosteal reaction.

These findings are consistent with a stress fracture.

Outcome

Considering the major alteration seen on the scintigraphy, an MRI was performed, which confirmed the diagnosis of a stress fracture. A conservative treatment was given (pain relieving and rest), leading to full recovery.



8.11. CASE No. K 11

Study type:	Traumatology		
Clinical indication:	Pain in the right leg		
Keywords:	Shin splint		
SPECT/CT system:	Siemens Symbia T6	Tracer:	^{99m}Tc -DPD
Uptake:	240 min	Dose:	781 MBq
Tube loading:	86 mAs	Tube voltage:	130 kVp

Short clinical history

A 30 year old female patient experiencing pain in the anterior and distal part of the right leg. The patient plays basketball, and the pain has been enhanced at practice over the previous 10 days.

Findings

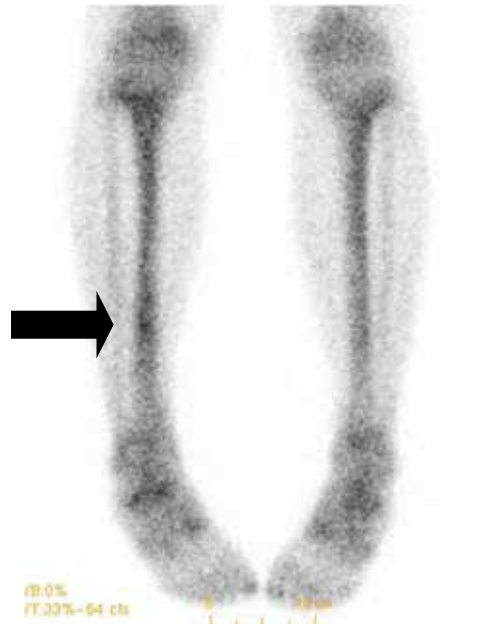
Blood pool planar image is normal (not shown).

The late phase planar image (A, arrow): Shows increased linear uptake in the anterior aspect of the right tibia.

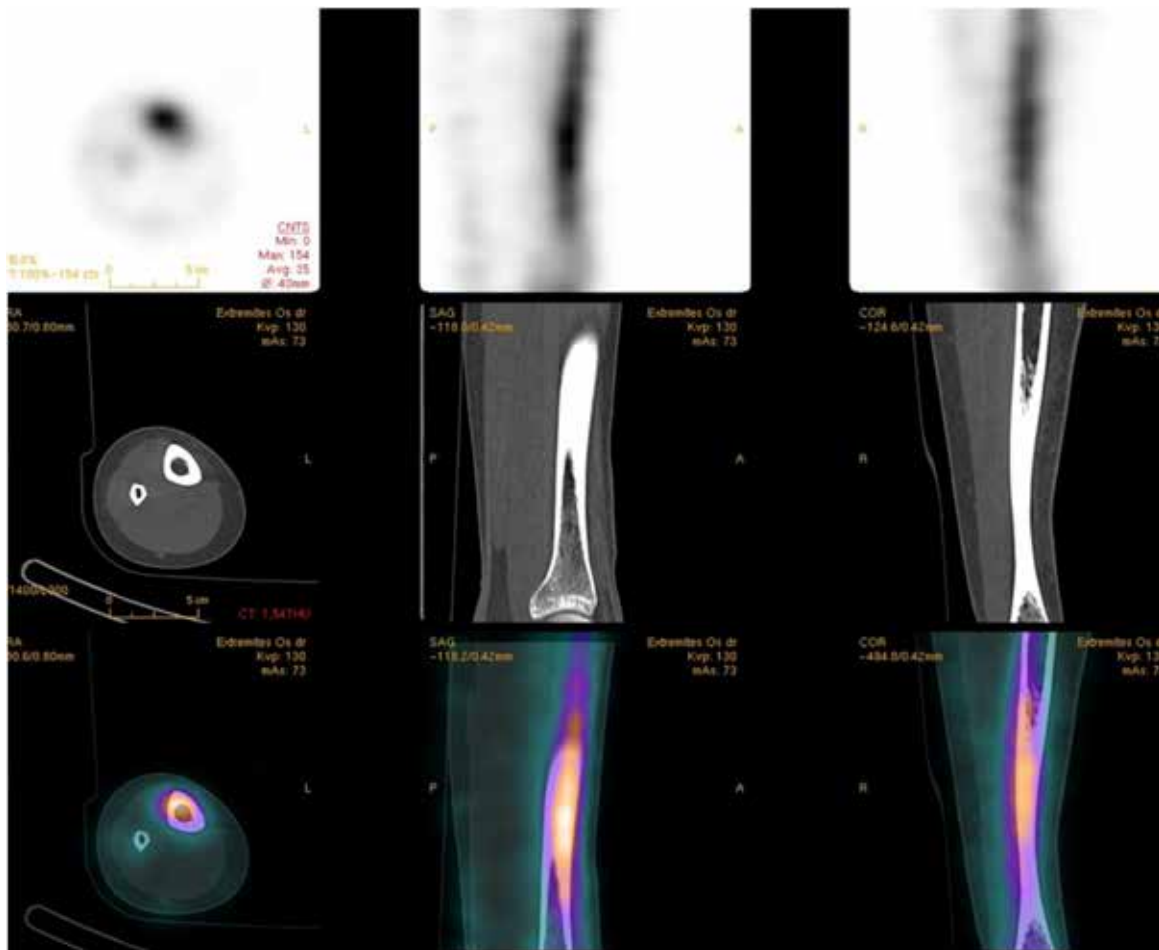
SPECT/CT (B): Shows normal bone structure on CT, consistent with a shin splint.

Teaching point

Note the metabolic study is able to describe very subtle changes. An early diagnosis allows for a shorter interruption in the sport activity.



(A)



(B)

8.12. CASE No. K 12

Study type:	Orthopaedics Traumatology		
Clinical indication:	Pain in the lower leg		
Keywords:	Fracture		
SPECT/CT system:	Philips Precedence 16 slice	Tracer:	^{99m}Tc -DPD
Uptake:	120 min	Dose:	674 MBq
Tube loading:	120 mAs	Tube voltage:	120 kVp

Short clinical history

A 39 year old male patient with pain over the last 2 months in the right lower leg. The patient had no history of trauma.

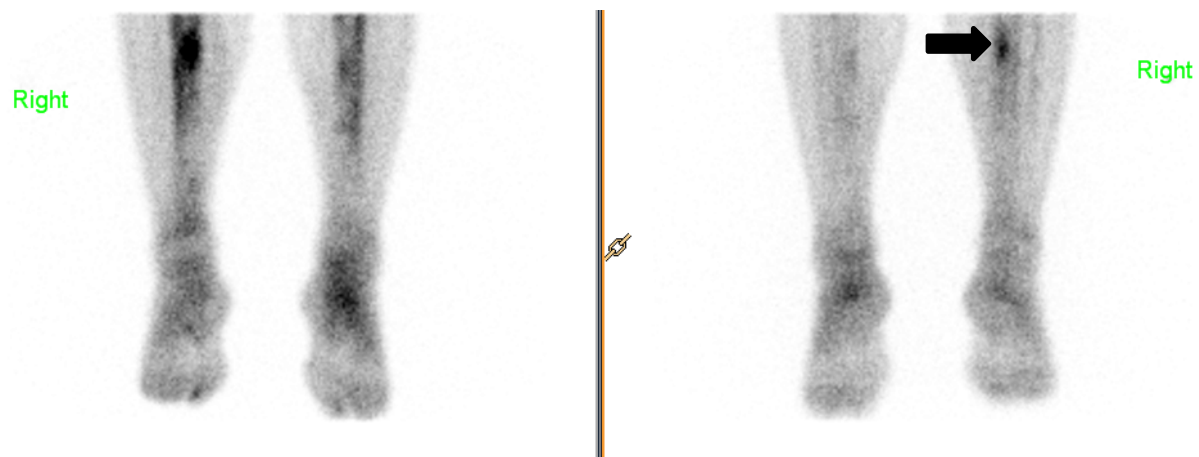
Findings

Planar bone scan (A): Shows a bone focus located in the central part of the right tibia (arrow).

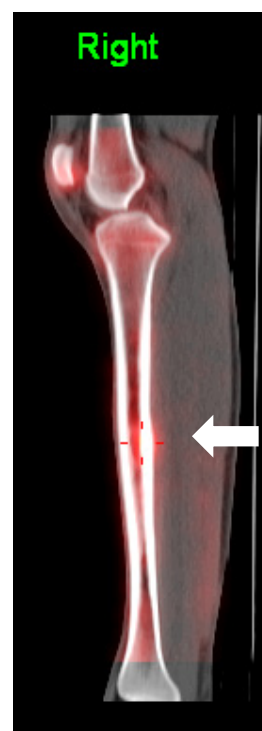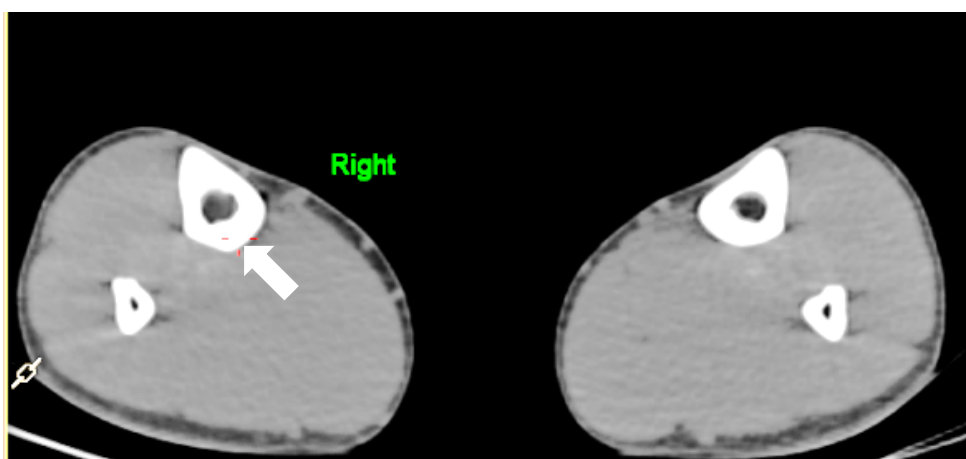
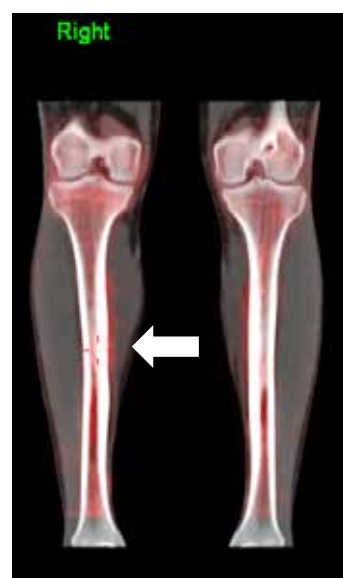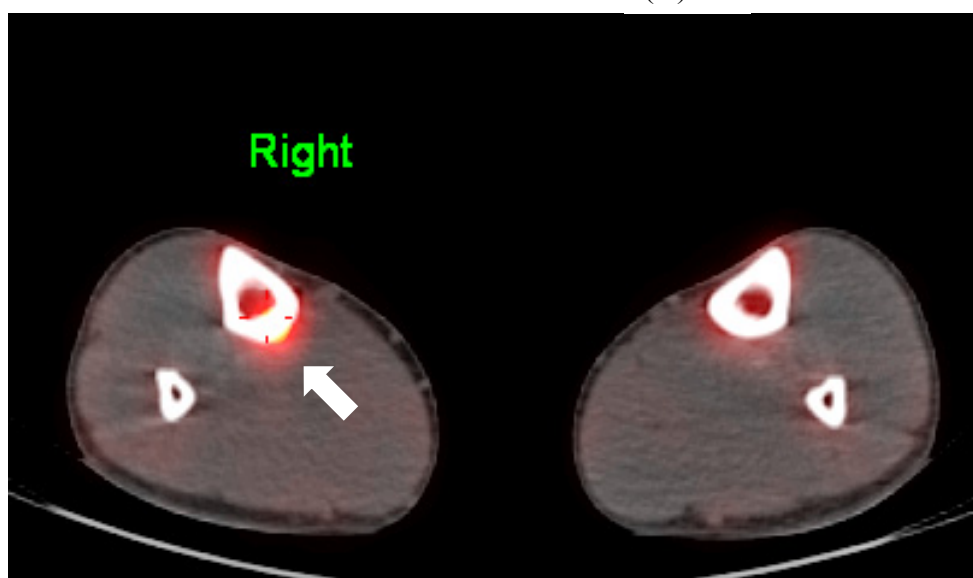
SPECT/CT (B): Shows increased uptake located in the central and posterior part of the cortex in the right tibia (arrow). CT was normal. The finding is consistent with a stress fracture.

Outcome

A fracture invisible on CT was diagnosed via SPECT. The patient was an avid runner, who would decrease his level of activity.



(A)



(B)

8.13. CASE No. K 13

Study type:	Rheumatology		
Clinical indication:	Pain Arthritis		
Keywords:	Psoriatic arthritis Bone infarction		
SPECT/CT system:	Philips Precedence 16 slice	Tracer:	^{99m}Tc -HDP
Uptake:	180 min	Dose:	759 MBq
Tube loading:	30 mAs	Tube voltage:	120 kVp

Short clinical history

A 60 year old female patient with pain in the shoulders, wrists and finger joints as well as both knees, primarily the left side. The patient has been previously diagnosed with psoriatic arthritis.

Findings

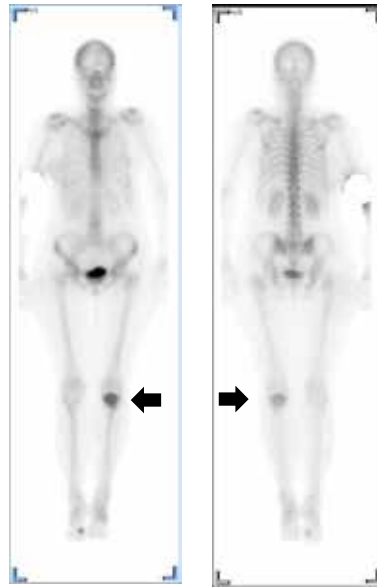
Planar bone scan (A): Shows high uptake in the left proximal tibia (arrows) not explained by arthritis.

SPECT/CT (B): Shows increased subperiosteal uptake in the left proximal tibia without significant radiological changes.

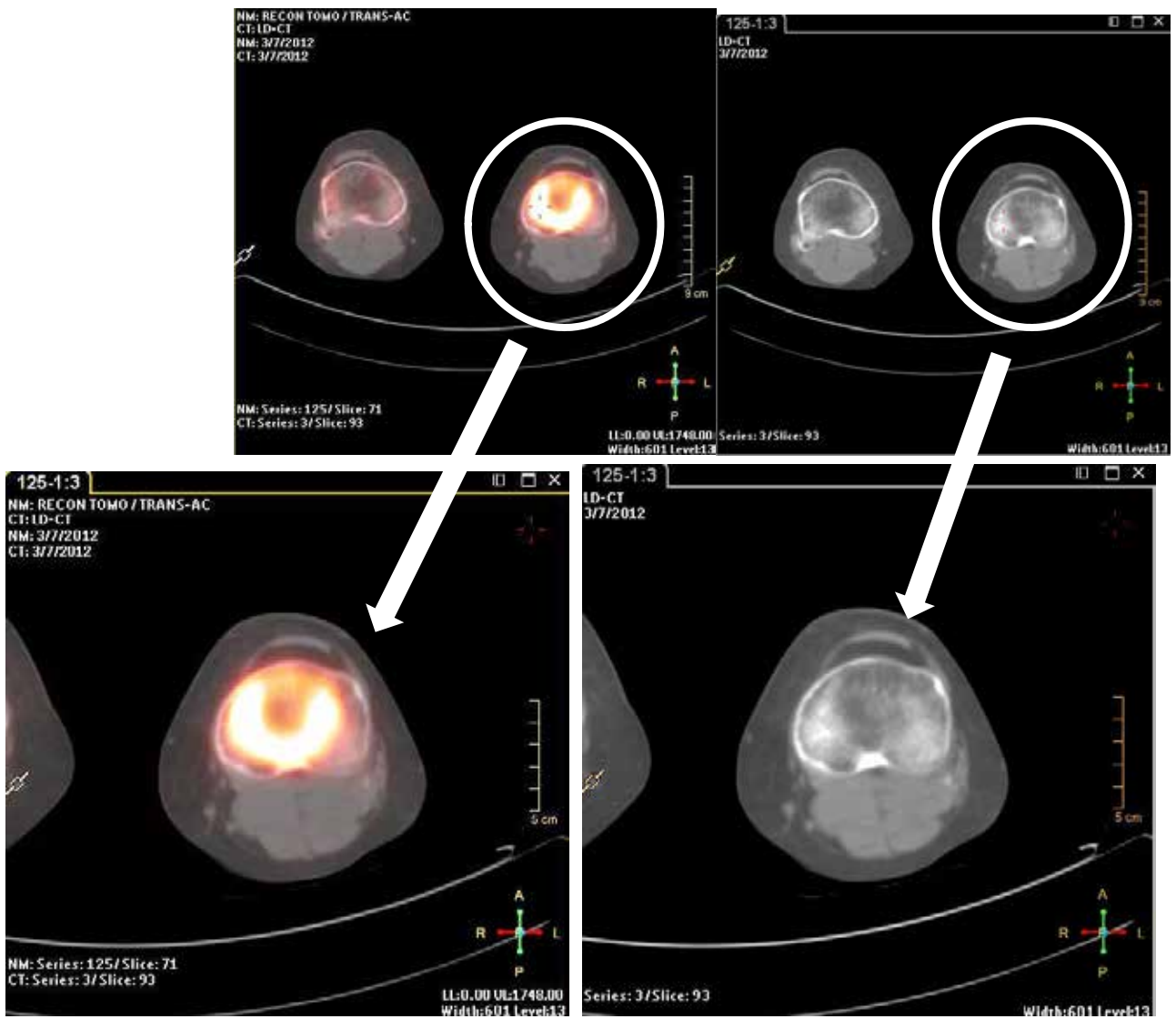
Outcome and teaching point

The MRI shows bone infarction in the left proximal tibia. No further action was taken, since the pain gradually disappeared.

Note SPECT/CT pointed out the abnormality and MRI was confirmatory.



(A)



(B)

8.14. CASE No. K 14

Study type:	Orthopaedic		
Clinical indication:	Pain in the left knee Multilocular bone cyst Osteomyelitis		
Keywords:	Bone cyst Fibrous dysplasia		
SPECT/CT system:	Philips BrightView XCT	Tracer:	^{99m}Tc -HDP
Uptake:	180 min	Dose:	713 MBq
Tube loading:	30 mAs	Tube voltage:	120 kVp

Short clinical history

A 40 year old female patient with pain in the left knee. X ray shows a multilocular bone cyst in the tibia (not shown). Infection was suspected.

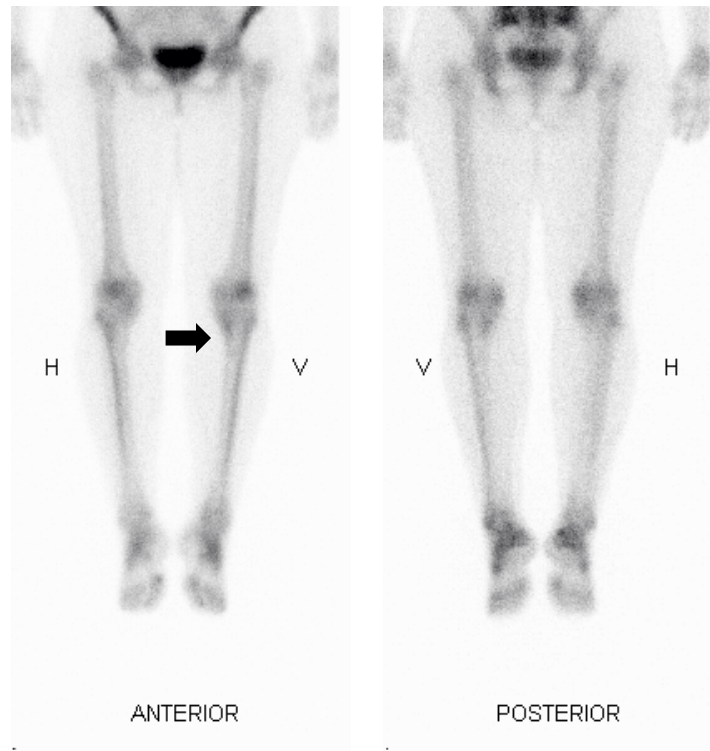
Findings

Bone scintigraphy (A): Shows moderate uptake in the left proximal tibia (arrow).

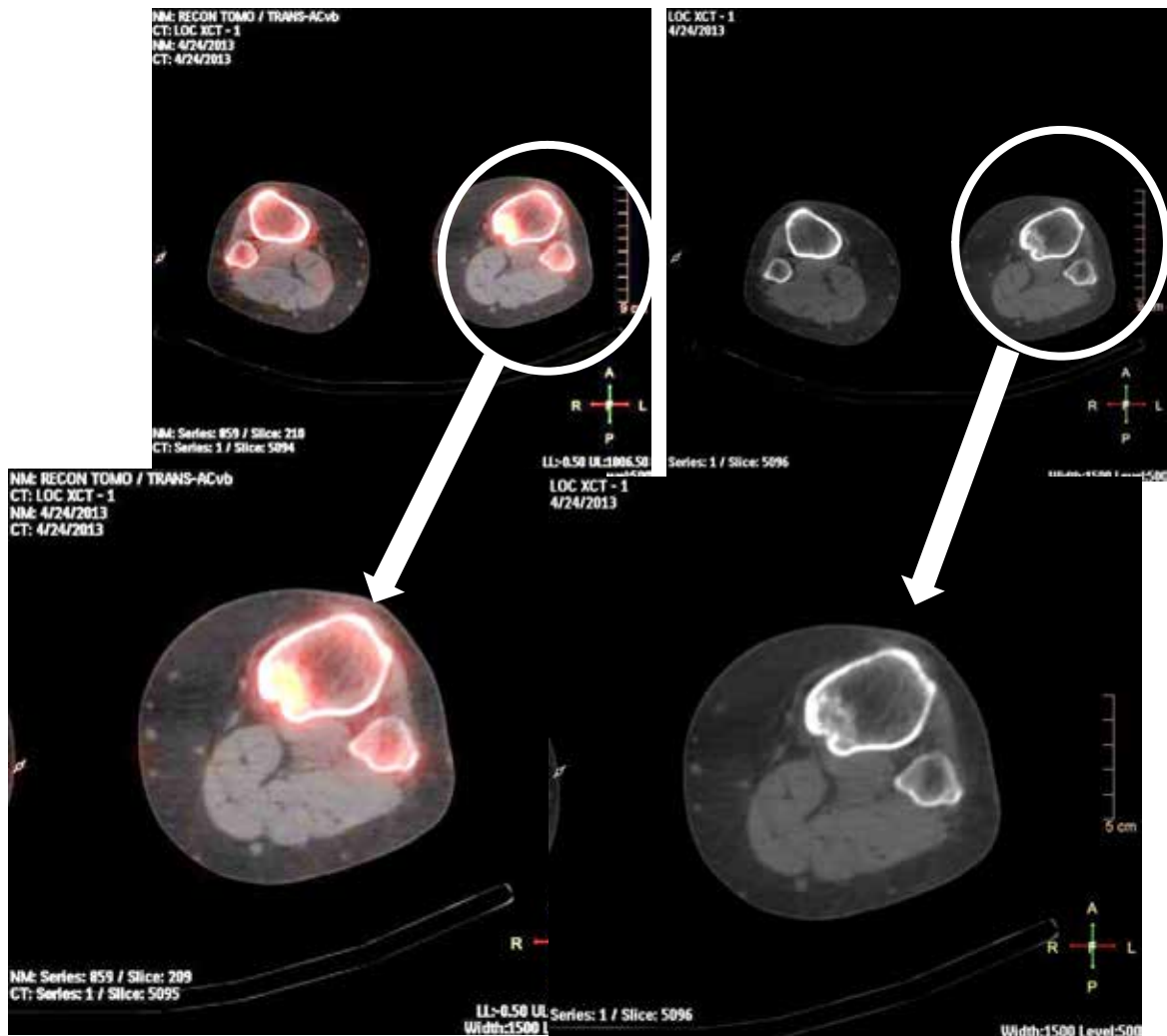
SPECT/CT (B): Allowed locating the uptake in the medulla of the left proximal tibia corresponding to a heterogeneous sclerotic map like structure on the CT (arrow).

Outcome

No antibiotic treatment was given, but a biopsy was performed at the exact location of the abnormal area. It revealed fibrous dysplasia.



(A)



(B)

8.15. CASE No. K 15

Study type:	Rheumatology		
Clinical indication:	Muscle and joint pain		
Keywords:	Enchondroma Benign tumour		
SPECT/CT system:	Philips BrightView XCT	Tracer:	^{99m}Tc -HDP
Uptake:	180 min	Dose:	713 MBq
Tube loading:	30 mAs	Tube voltage:	120 kVp

Short clinical history

A 40 year old female patient with diffuse muscle and joint pain.

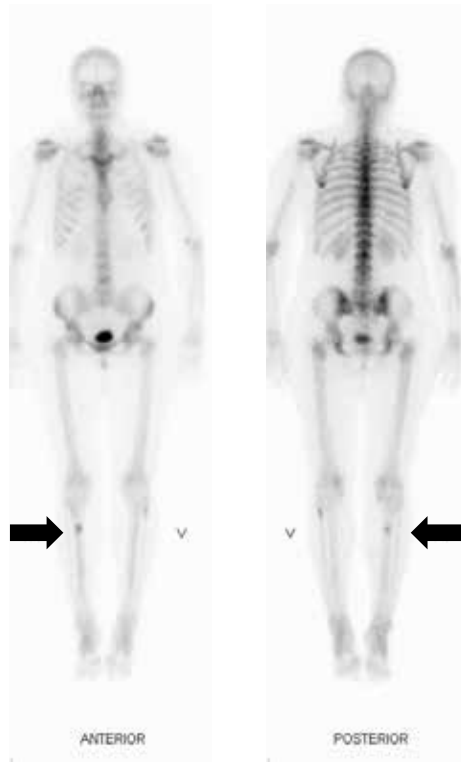
Findings

Planar bone scan (A): Shows high uptake in the right proximal tibia (arrow) and left fibula.

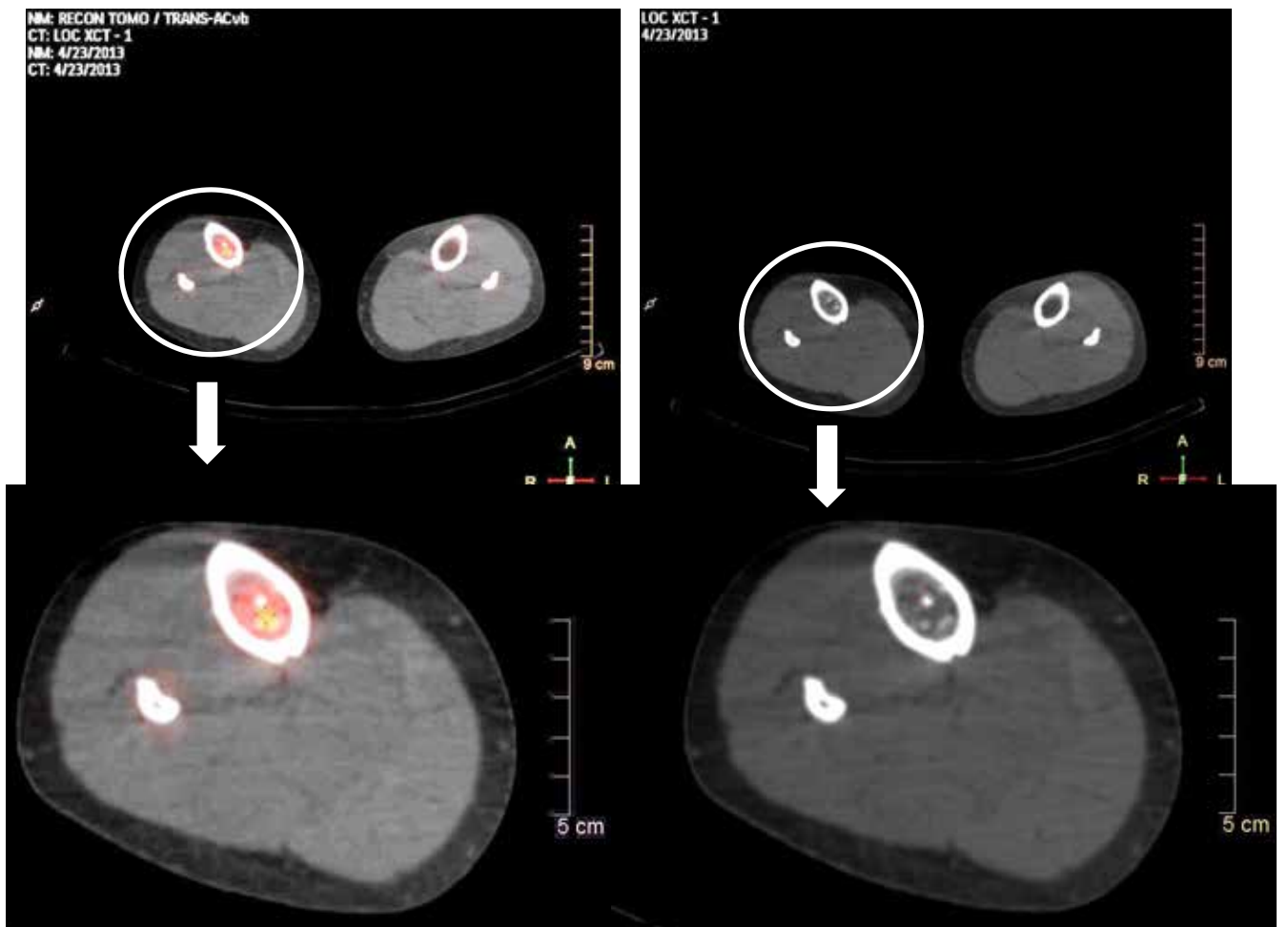
SPECT/CT (B): Shows that the high uptake is located in the bone marrow of the right proximal tibia (arrow) and the left proximal fibula (not shown). CT shows typical ring and arc calcifications. The findings are consistent with enchondroma.

Teaching point

The MRI confirmed the diagnosis of enchondroma.



(A)



(B)

8.16. CASE No. K 16

Study type:	Orthopaedics Degenerative		
Clinical indication:	Bilateral knee pain Post right knee arthroplasty		
Keywords:	Pain Arthroplasty		
SPECT/CT system:	General Electric Discovery 670	Tracer:	^{99m}Tc -DPD
Uptake:	180 min	Dose:	650 MBq
Tube loading:	120–400 mAs	Tube voltage:	120 kVp

Short clinical history

A 51 year old male patient with seronegative, erosive chronic polyarthritis. The patient had right-sided knee arthroplasty, and presented with continuous pain in both knees.

Findings

Planar bone scan (A, early and late phases): Shows significant uptake in both knees.

SPECT/CT (B): Shows uptake behind the right patella, obscured by the metal implant artefacts on CT consistent with right-sided patellar friction.

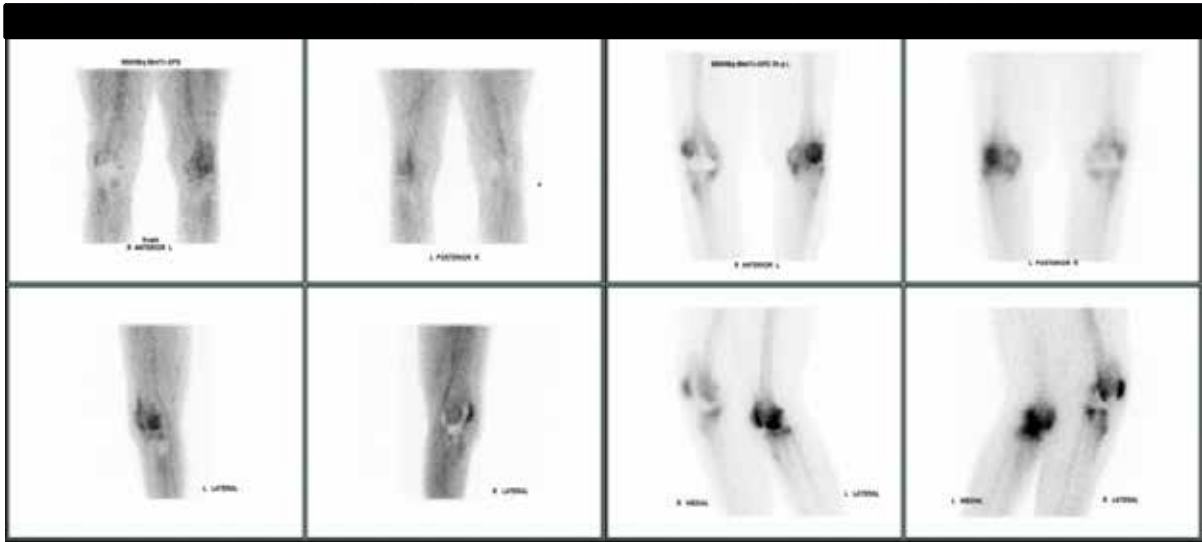
There is also increased uptake behind the left patella (small arrow), but here CT shows significant degenerative bone changes consistent with severe degenerative osteoarthritis.

In addition, the highest uptake is found in an osteochondral defect of the left distal femur (large arrow).

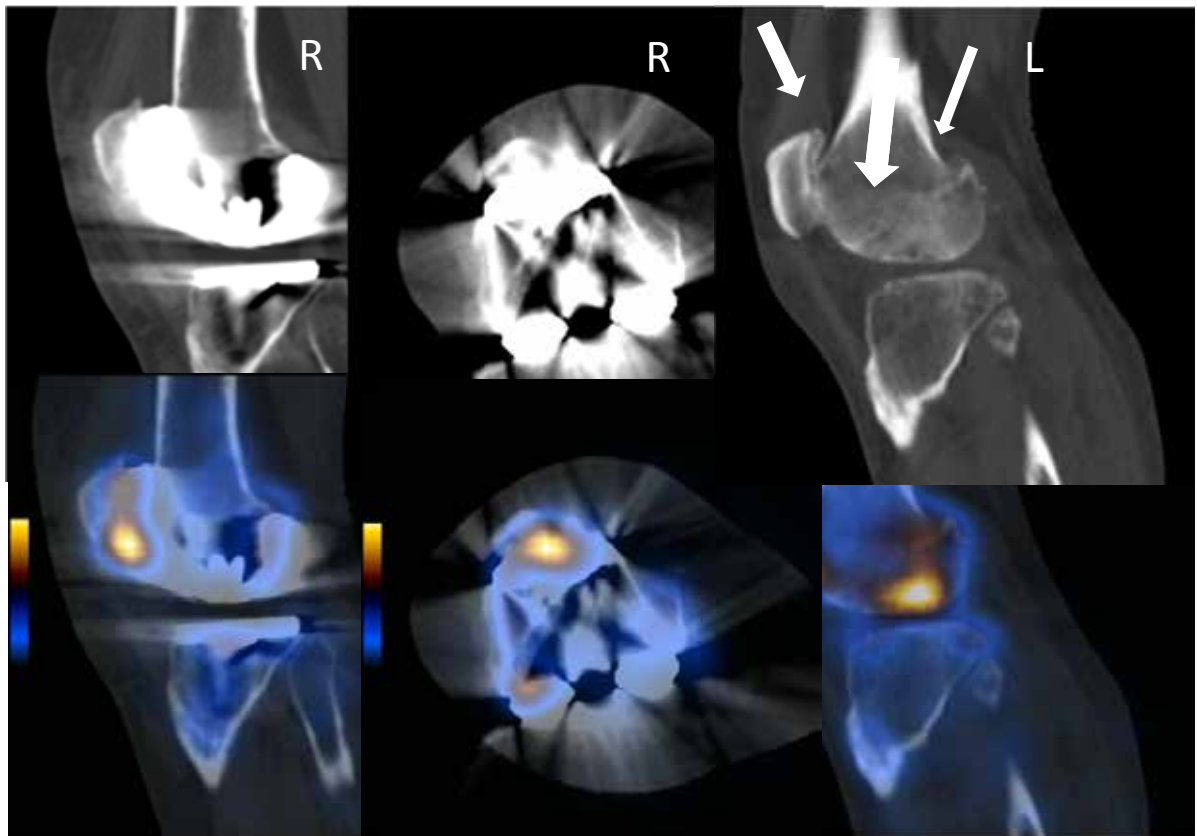
Outcome and teaching point

Conservative supportive treatment for patellar friction.

Note SPECT/CT highlights the cause of pain even in areas with metallic artefacts. Furthermore, the activity of osteochondral defect can be estimated. The MRI of the left knee was performed to evaluate the status of the osteochondrosis and the covering cartilage.



(A)



(B)

9. FEET

9.1. CASE No. F 1

Study type:	Orthopaedic		
Clinical indication:	Pain at the back of the heel		
Keywords:	Haglund's deformity		
SPECT/CT system:	Siemens Symbia T2	Tracer:	^{99m}Tc -DPD
Uptake:	180 min	Dose:	677 MBq
Tube loading:	120 mAs	Tube voltage:	80 kVp

Short clinical history

A 51 year old male patient with persistent pain at the back of the heel for 2 months.

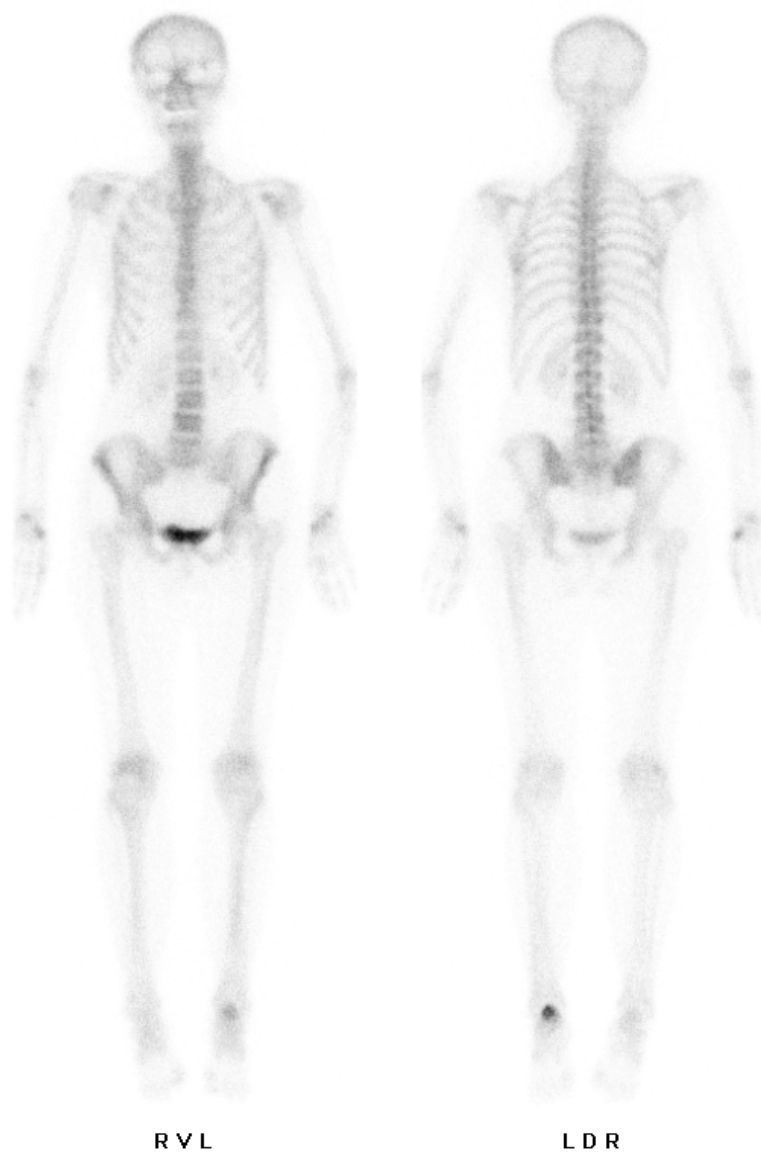Findings

Planar image (A): Shows intense uptake in the left calcaneal bone.

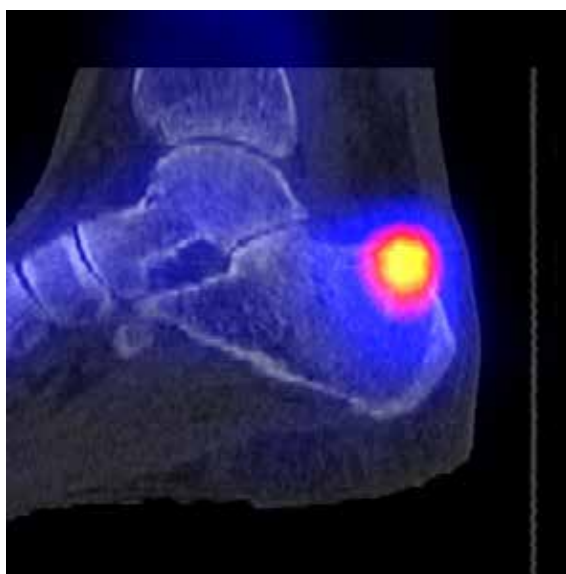
SPECT/CT (B): Shows a Haglund's deformity with pathologically elevated bone metabolism and signs of a bursitis.

Outcome

Conservative treatment including anti-inflammatory medications.



(A)



(B)

9.2. CASE No. F 2

Study type:	Orthopaedic		
Clinical indication:	Pain at the back of the left heel		
Keywords:	Calcaneal spur Plantar fasciitis		
SPECT/CT system:	Siemens Symbia T2	Tracer:	^{99m}Tc -DPD
Uptake:	180 min	Dose:	508 MBq
Tube loading:	120 mAs	Tube voltage:	80 kVp

Short clinical history

A 61 year old female patient with persistent pain at the back of the left heel for 2 weeks.

Findings

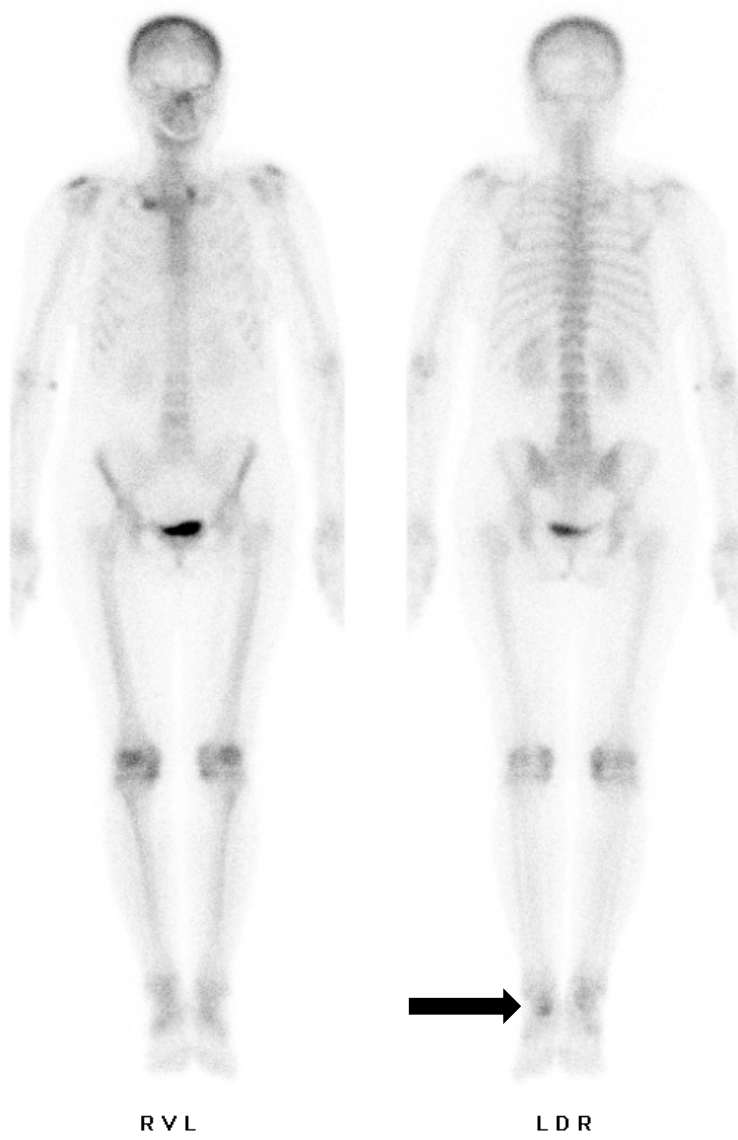
Planar image (A): Shows intense uptake in the posterior tuberosity of the left calcaneal bone (arrow). Furthermore, degenerative disease was seen in both knees, both acromioclavicular joints, and right sternoclavicular joint.

SPECT/CT (B): Shows focal uptake in an inferior calcaneal spur on the inferior aspect of the calcaneus representing a plantar fasciitis (long arrow). CT shows an additional posterior calcaneal spur (Haglund) without pathologically elevated bone metabolism (short arrow).

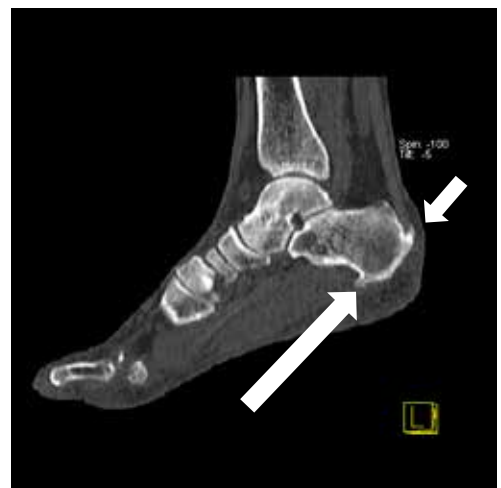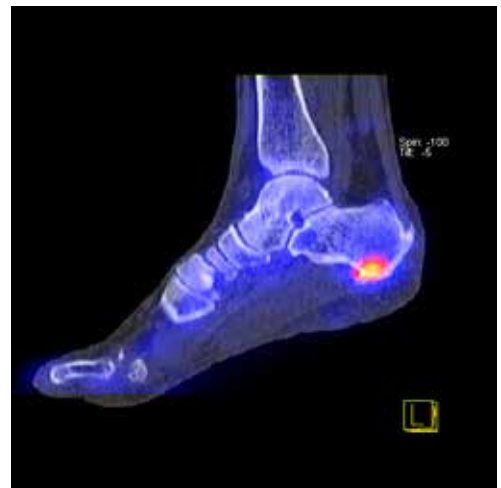Outcome and teaching point

Deep X ray therapy followed by conservative therapy.

Note SPECT/CT allows the differentiation between active and inactive spurs.



(A)



(B)

9.3. CASE No. F 3

Study type:	Orthopaedic		
Clinical indication:	Pain in the left foot		
Keywords:	Osteoarthritis		
SPECT/CT system:	Siemens Symbia T2	Tracer:	^{99m}Tc -DPD
Uptake:	180 min	Dose:	497 MBq
Tube loading:	120 mAs	Tube voltage:	80 kVp

Short clinical history

A 71 year old male patient with pain in the left foot for several years.

Findings

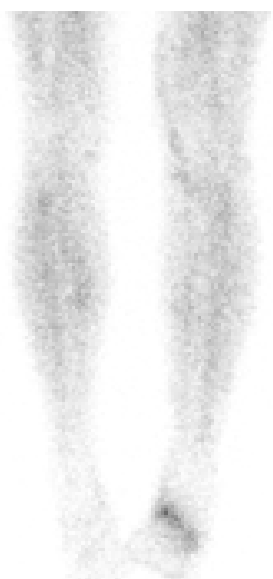
Planar image of blood pool (A): Shows an elongated uptake in the tarsometatarsal joint (Lisfranc joint) representing synovialitis.

Late planar image (B): Shows intense uptake in the tarsometatarsal joint (Lisfranc joint).

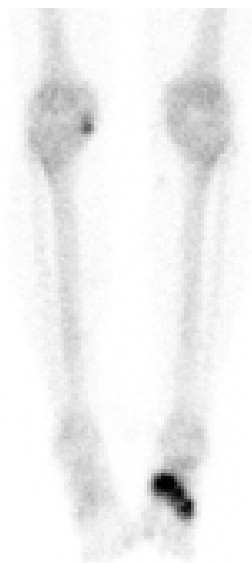
SPECT/CT (C): Shows massive degenerative changes within the tarsometatarsal joint (Lisfranc joint) and also in the left cuboideonavicular joint that shows severe degenerative changes (arrow).

Outcome

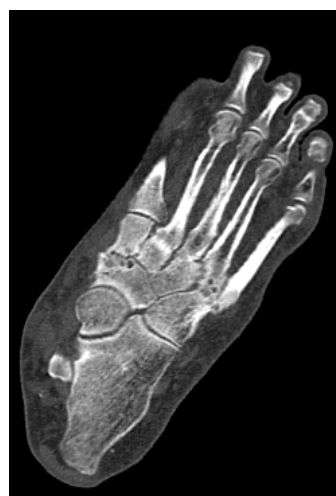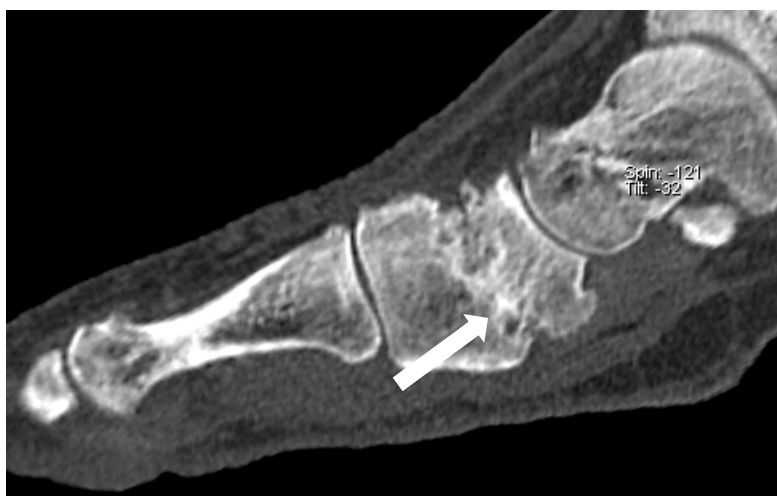
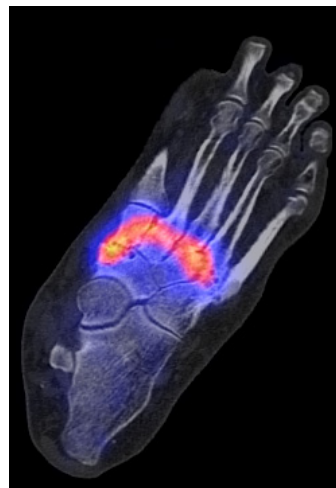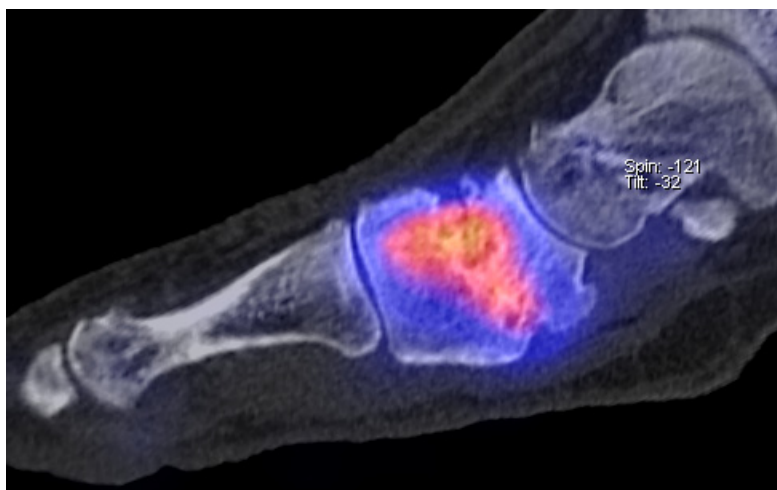
Radiosynoviorthesis of the 2nd, 3rd and 4th tarsometatarsal joints and conservative therapy including anti-inflammatory medications were administered.



(A)



(B)



(C)

9.4. CASE No. F 4

Study type:	Orthopaedic		
Clinical indication:	Pain in the right foot		
Keywords:	Osteoarthritis		
SPECT/CT system:	Siemens Symbia T2	Tracer:	^{99m}Tc -DPD
Uptake:	180 min	Dose:	521 MBq
Tube loading:	120 mAs	Tube voltage:	80 kVp

Short clinical history

An 85 year old female patient with pain in the right foot for several years.

Findings

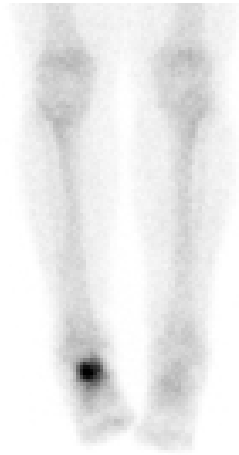
Late planar image (A): Shows intense uptake in the right tarsus.

SPECT/CT (B): Shows significant osteoarthritic changes within the talocalcaneonavicular joint (arrows).

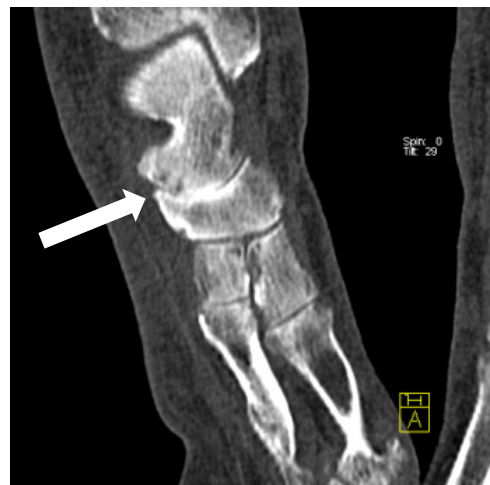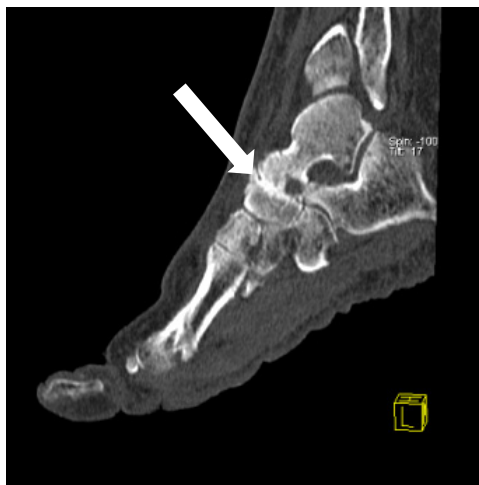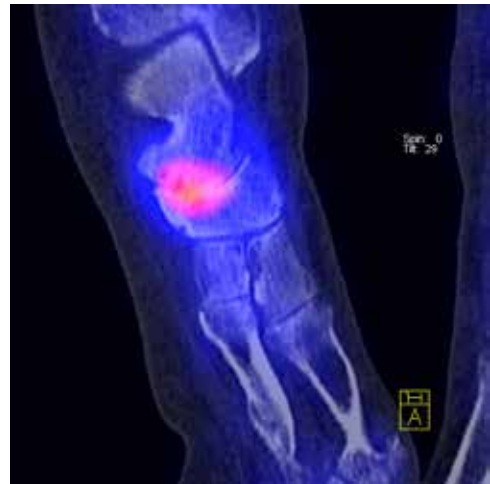
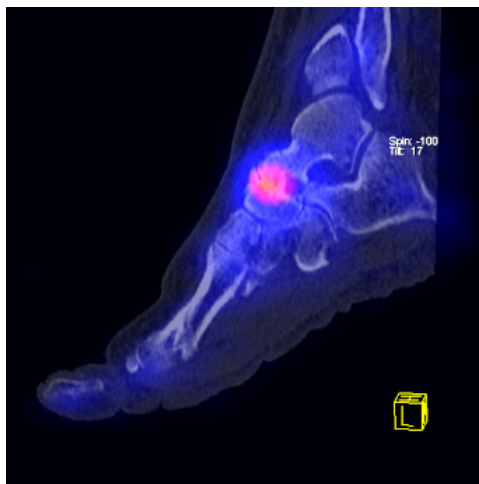
Outcome and teaching point

Conservative therapy.

Note SPECT/CT allows for the exact localization of the active osteoarthritic joints.



(A)



(B)

9.5. CASE No. F 5

Study type:	Orthopaedic		
Clinical indication:	Pain in the left foot		
Keywords:	Fracture		
SPECT/CT system:	Siemens Symbia T2	Tracer:	^{99m}Tc -DPD
Uptake:	180 min	Dose:	483 MBq
Tube loading:	120 mAs	Tube voltage:	80 kVp

Short clinical history

A 56 year old female patient with pain in the left foot following exercise (Nordic walking).

Findings


Late planar image (A): Shows intense uptake in the 2nd metatarsal bone.

SPECT/CT (B): Shows cortical uptake in the distal 2nd metatarsal bone with thickening of the corticalis (arrows). This is consistent with a stress fracture with cortical reaction (i.e. a relatively old lesion).

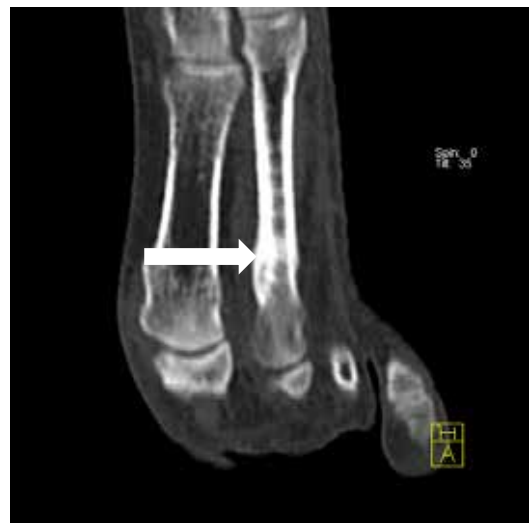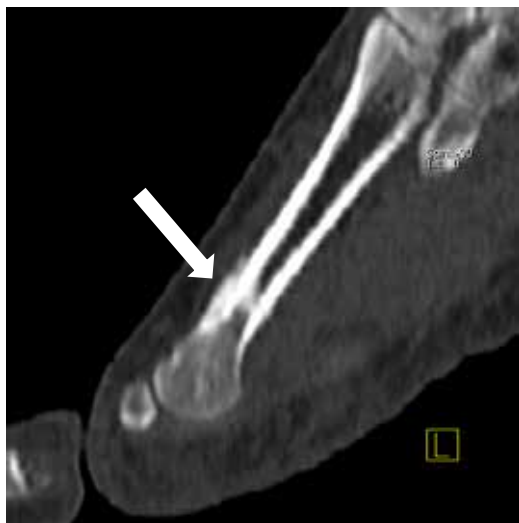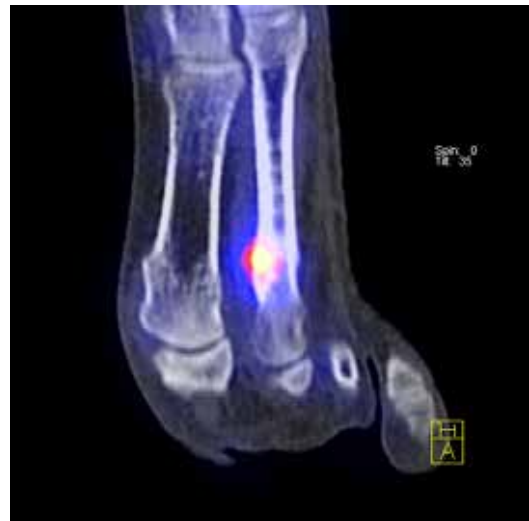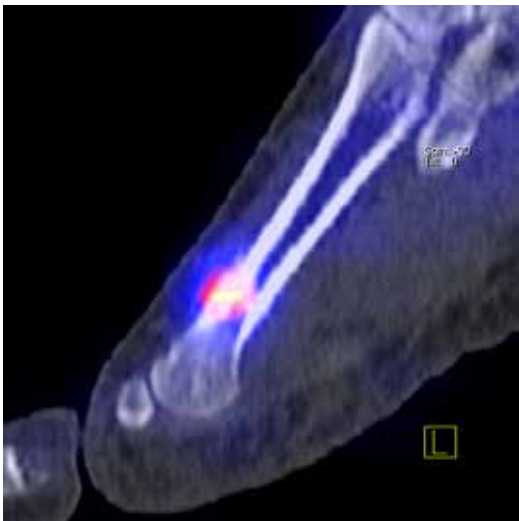
Outcome and teaching point

Conservative therapy.

Note CT in SPECT/CT provides additional information about the age of the fracture.



(A)



(B)

9.6. CASE No. F 6

Study type:	Orthopaedic		
Clinical indication:	Pain in the right foot		
Keywords:	Fracture		
SPECT/CT system:	Siemens Symbia T2	Tracer:	^{99m}Tc -DPD
Uptake:	180 min	Dose:	498 MBq
Tube loading:	120 mAs	Tube voltage:	80 kVp

Short clinical history

A 66 year old female patient with pain in the right foot following hiking holidays.

Findings

Planar image (A): Shows intense uptake in the 1st metatarsal bone or 1st metatarsophalangeal joint in the right foot.


SPECT/CT (B): Shows cortical uptake in the distal 1st metatarsal bone in the right foot with only slightly increased density of the bone marrow on CT (arrows) representing a recent stress fracture.

There are also mild degenerative changes in the distal tarsal area.

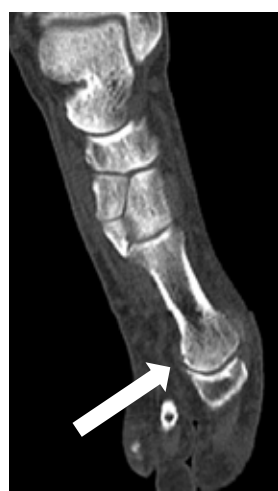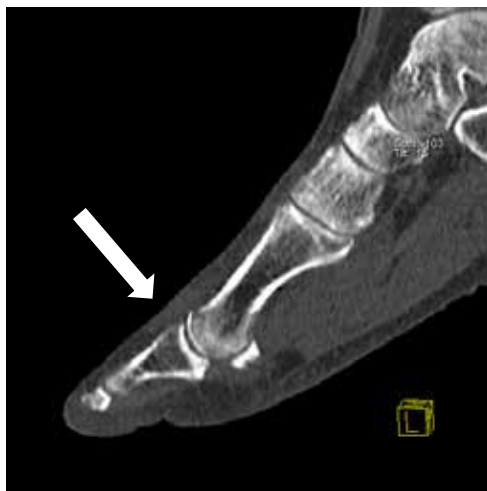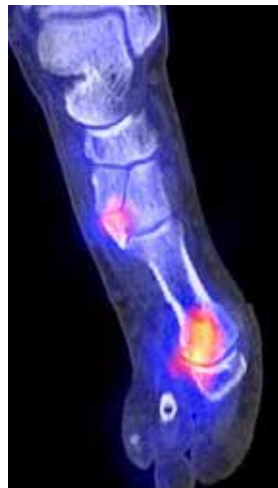
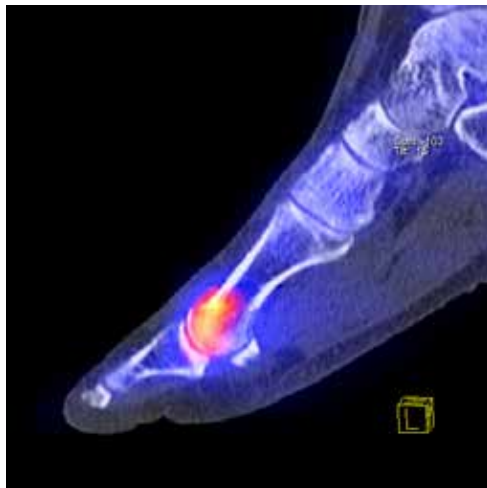Outcome and teaching point

Conservative therapy.

Note SPECT/CT allows the diagnosis of a stress fracture and rules out osteoarthritis of the adjacent joint.



(A)



(B)

9.7. CASE No. F 7

Study type:	Orthopaedic		
Clinical indication:	Pain in the right ankle Suspected rheumatoid arthritis		
Keywords:	Osteoarthritis		
SPECT/CT system:	Siemens Symbia T2	Tracer:	^{99m}Tc -DPD
Uptake:	180 min	Dose:	508 MBq
Tube loading:	120 mAs	Tube voltage:	80 kVp

Short clinical history

A 59 year old female patient with pain in the right ankle. Suspected rheumatoid arthritis.

Findings


Late planar image (A): Shows intense uptake in the talocrural region.

SPECT/CT (B): Shows cortical uptake in the talocrural joint and the inferior tibiofibular joint with moderate osteoarthritic changes in CT (arrows).

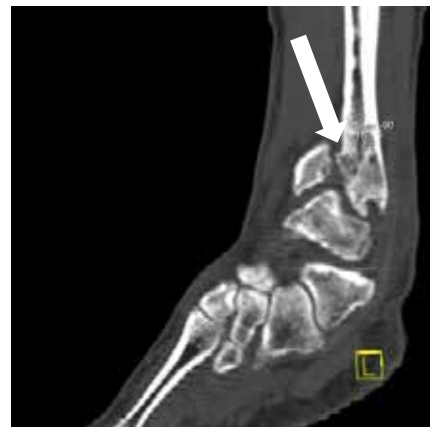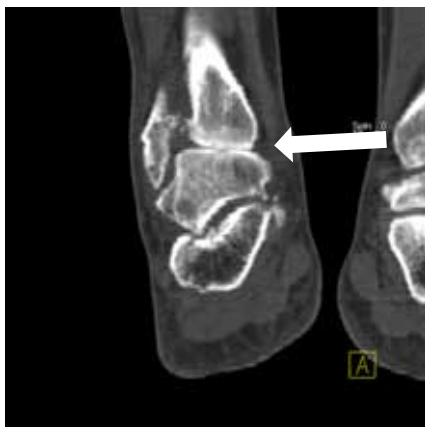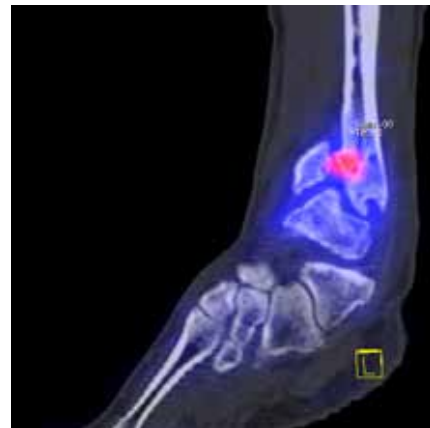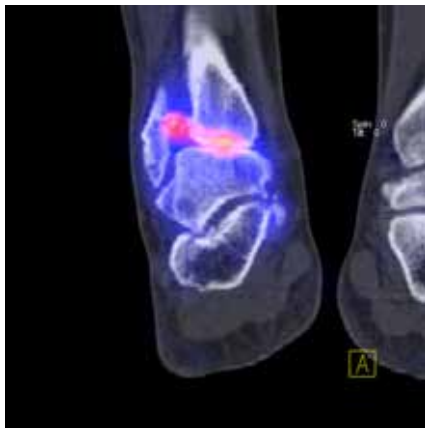Outcome and teaching point

Conservative therapy.

Note SPECT/CT allows localization of the osteoarthritic changes in two different joints, which would not be possible in planar imaging.



(A)



(B)

9.8. CASE No. F 8

Study type:	Orthopaedic		
Clinical indication:	Pain in the left tarsus		
Keywords:	Osteoarthritis		
SPECT/CT system:	Siemens Symbia T2	Tracer:	^{99m}Tc -DPD
Uptake:	180 min	Dose:	514 MBq
Tube loading:	120 mAs	Tube voltage:	80 kVp

Short clinical history

An 82 year old female patient with new onset of pain in the left tarsus.

Findings

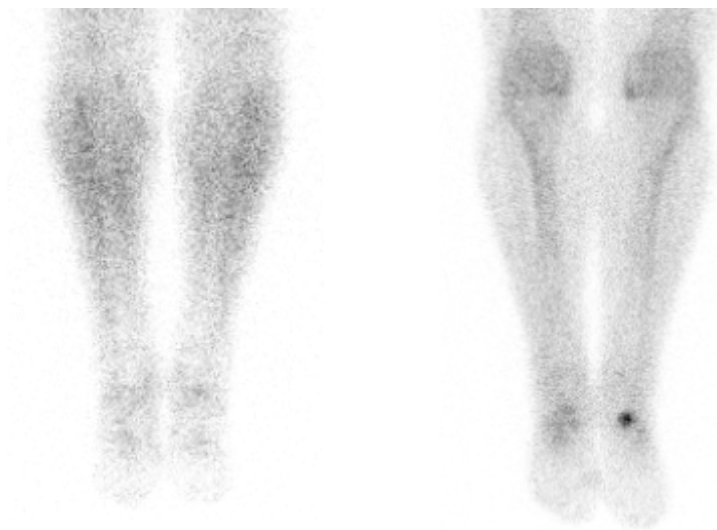
Planar images of blood pool (A): Shows focal uptake in the left tarsus representing synovitis.

Planar image of mineralization (B): Shows intense uptake in the left tarsus (arrow).

SPECT/CT (C): Shows intense uptake in the talonavicular joint primarily affecting the navicular bone (arrows). The CT shows cystic lesions and signs of degeneration. These findings are consistent with activated osteoarthritis of the talonavicular joint.

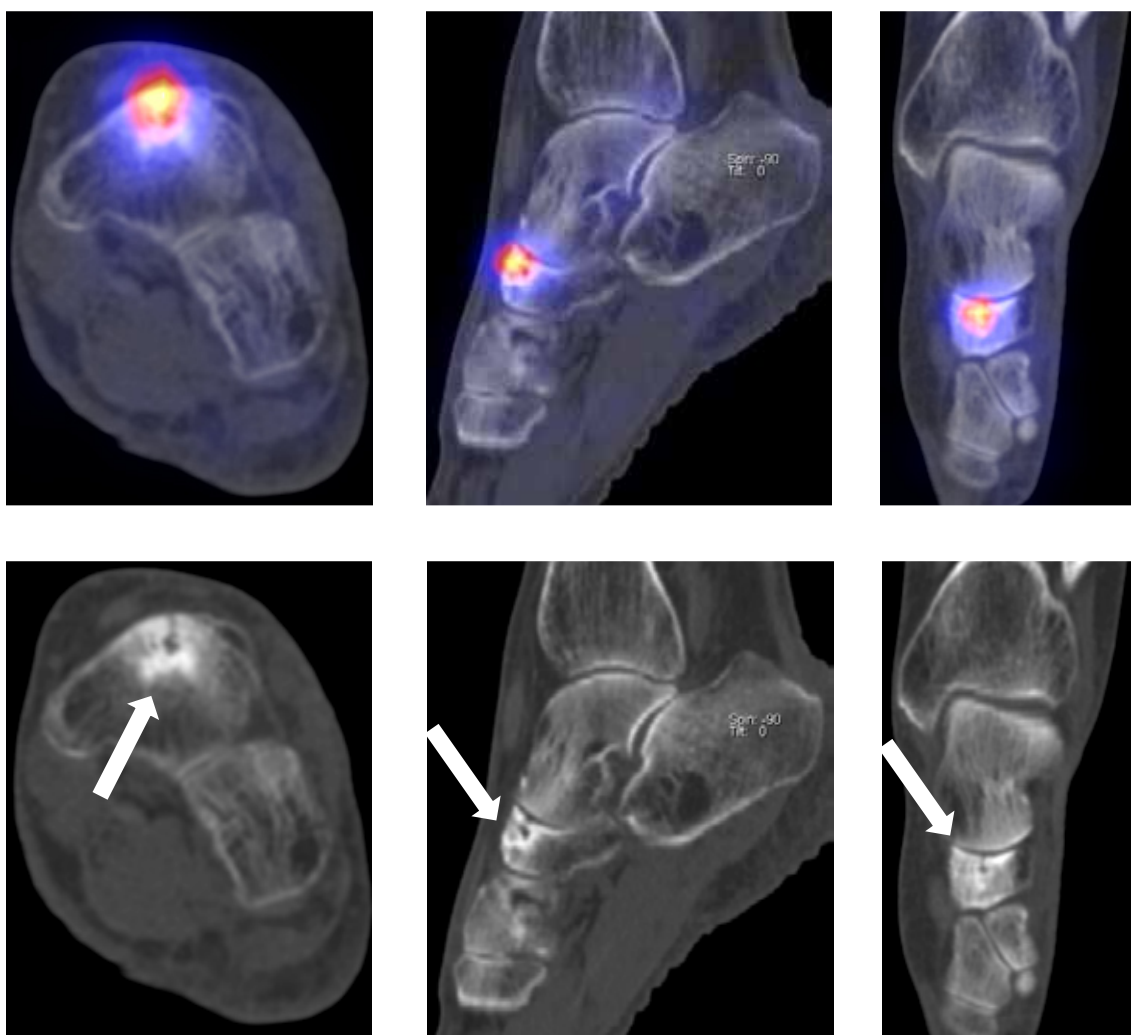
Teaching point

Note SPECT/CT allows for the exact anatomical localization and assessment of the extent of the disease.



(A)

(B)



(C)

9.9. CASE No. F 9

Study type:	Orthopaedic Degenerative		
Clinical indication:	Pain in the feet		
Keywords:	Osteoarthritis		
SPECT/CT system:	Philips Precedence 16 slice	Tracer:	^{99m}Tc -HDP
Uptake:	120 min	Dose:	666 MBq
Tube loading:	120 mAs	Tube voltage:	120 kVp

Short clinical history

A 53 year old female patient with bilateral pain in the metatarsal bones.

Findings

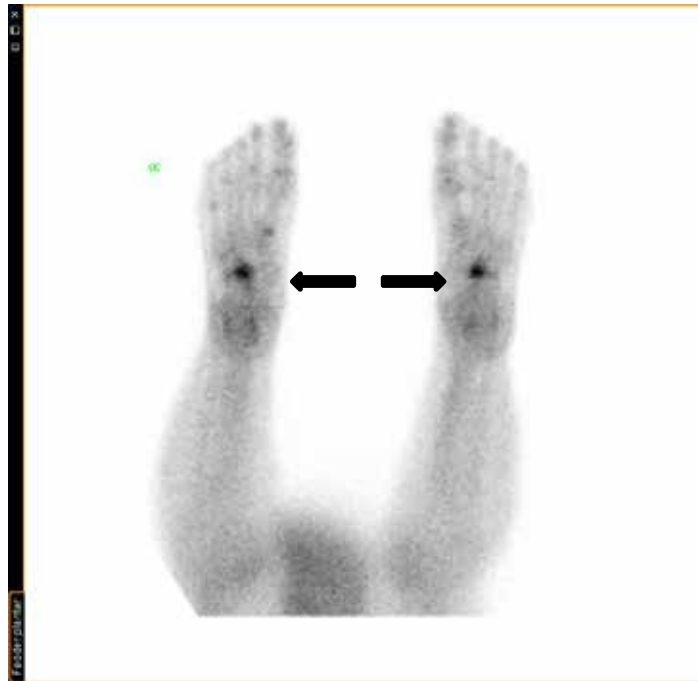Planar bone scan (A): Shows isolated foci centrally in the metatarsal bones (arrows).

SPECT/CT (B): Reveals increased focal uptake in the cuboidal bones near the calcaneus with subchondral lytic cysts, representing degenerative changes (arrows).

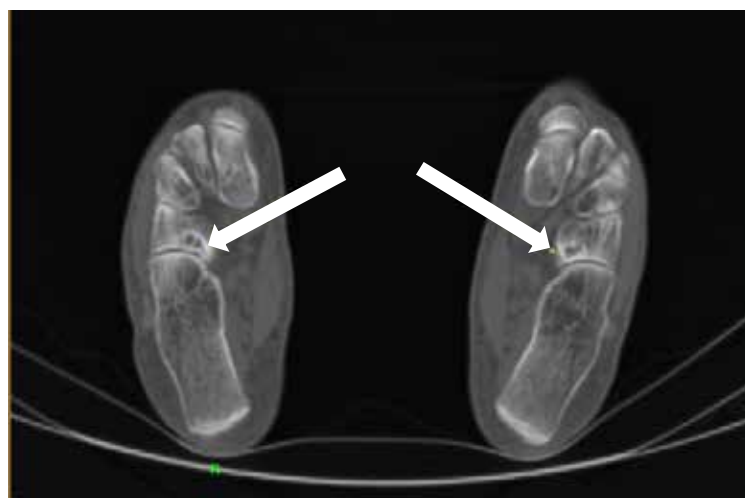
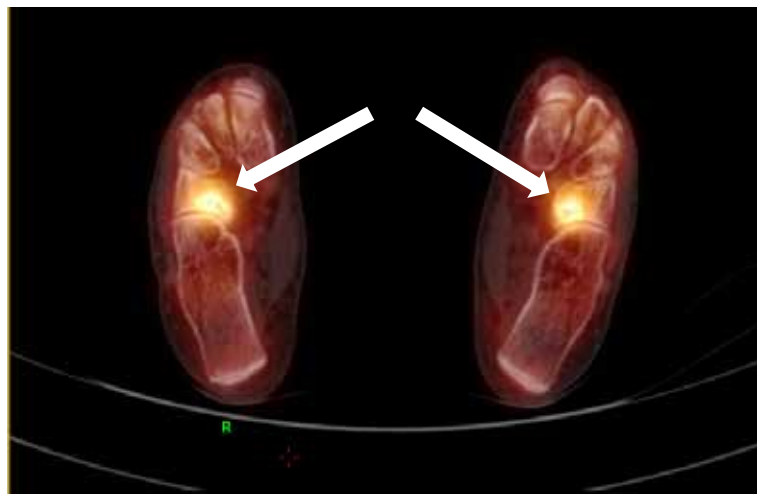
Outcome and teaching point

Owing to chronic pain, the patient was offered orthopaedic shoes.

Note SPECT/CT provided precise diagnosis of osteoarthritis in articulation calcaneocuboidea.



(A)



(B)

9.10. CASE No. F 10

Study type:	Orthopaedic Traumatology		
Clinical indication:	Swollen ankle		
Keywords:	Arthrodesis Infection Loosening Osteomyelitis		
SPECT/CT system:	Philips Precedence 16 slice	Tracer:	^{99m}Tc -HDP
Uptake:	120 min	Dose:	690 MBq
Tube loading:	120 mAs	Tube voltage:	120 kVp

Short clinical history

An 88 year old female patient with a successful osteodesis in the left ankle 12 years earlier. After a recent trauma, the ankle became swollen and loosened, and infection was suspected.

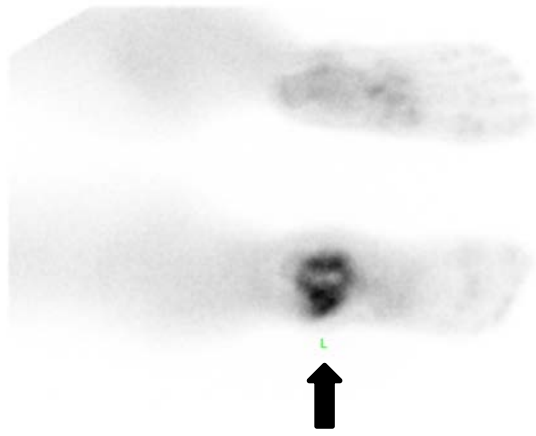
Findings

Planar bone scan (A): Shows hotspots in the left heel (arrow).

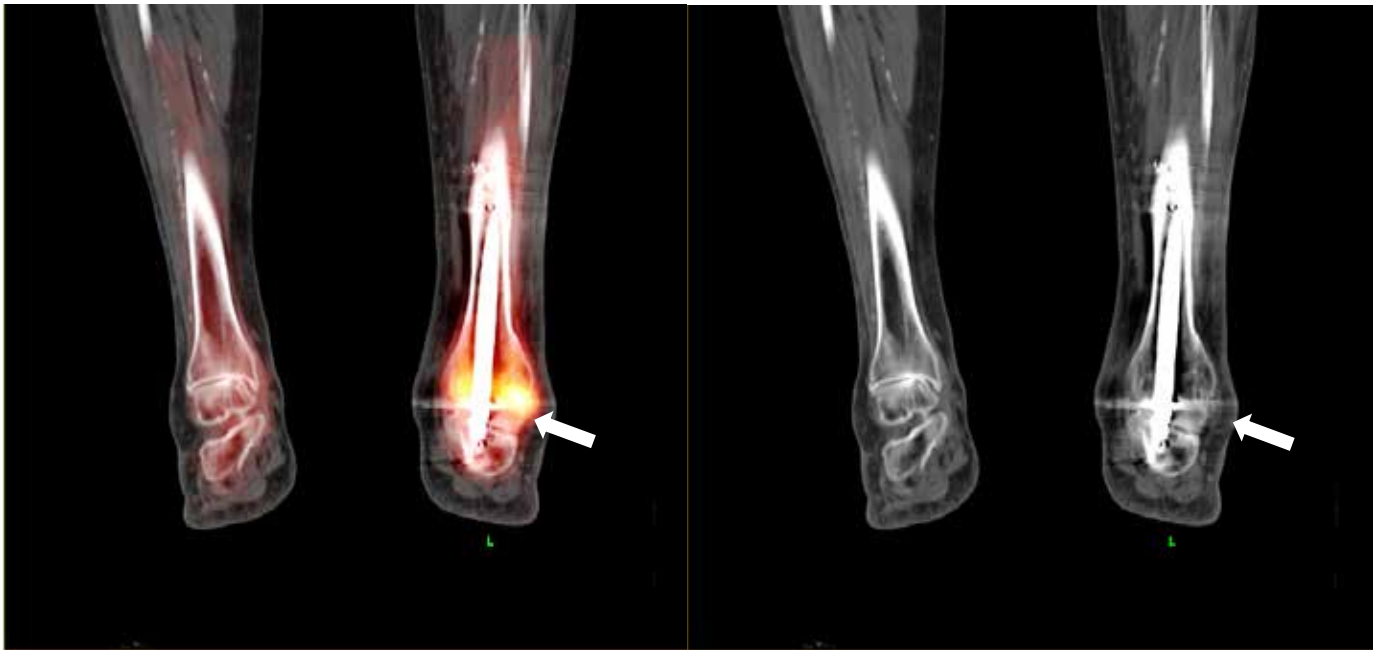SPECT/CT (B): Shows increased uptake at the level of the medial and lateral malleolus. CT shows a minor opacity next to the arthrodesis nail in the calcaneus where there was increased focal uptake (arrows). These findings suggest infection rather than loosening.

Outcome

Leucocyte scintigraphy confirmed infection in one arthrodesis nail. CRP was slightly elevated.



(A)



(B)

9.11. CASE No. F 11

Study type:	Orthopaedic Traumatology		
Clinical indication:	Foot pain		
Keywords:	Osteoarthritis		
SPECT/CT system:	Philips Precedence 16 slice	Tracer:	^{99m}Tc -HDP
Uptake:	120 min	Dose:	638 MBq
Tube loading:	120 mAs	Tube voltage:	120 kVp

Short clinical history

A 58 year old female patient with trauma to the left foot 1 month earlier. Since then, the patient has persistent pain. Stress fracture of the 2nd and 3rd metatarsal bones was suspected, but X ray was normal.

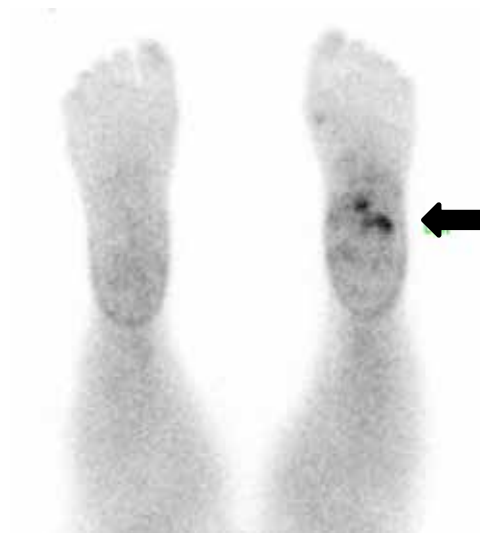Findings

Planar bone scan (A): Shows increased bone metabolism in the joint between the left calcaneus and the cuboid bone and increased bone metabolism in the joint between the talus and the navicular bone.

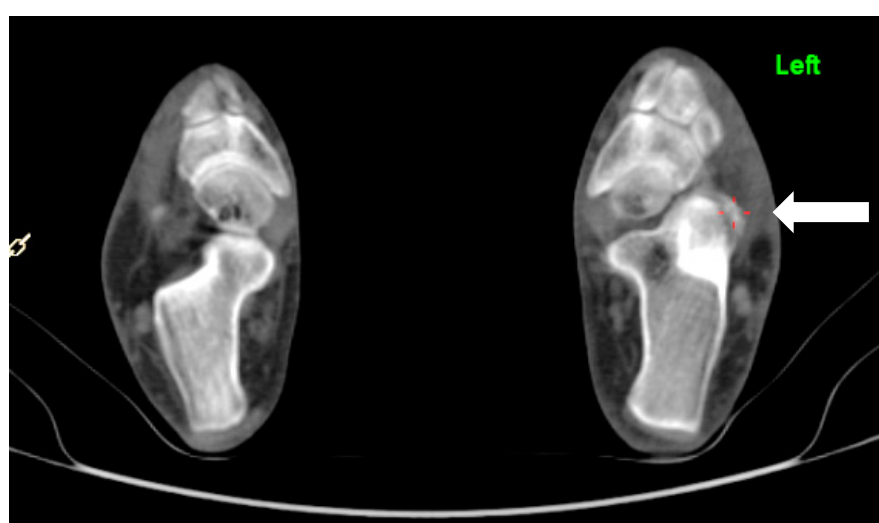
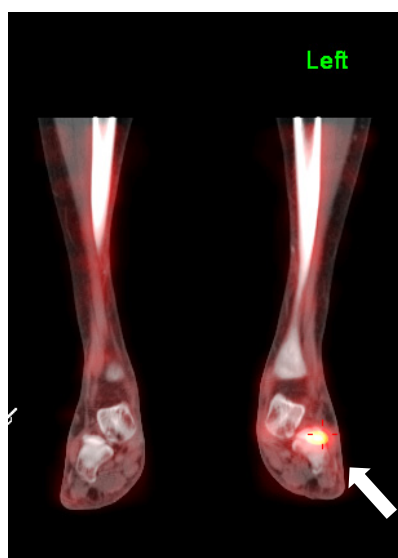
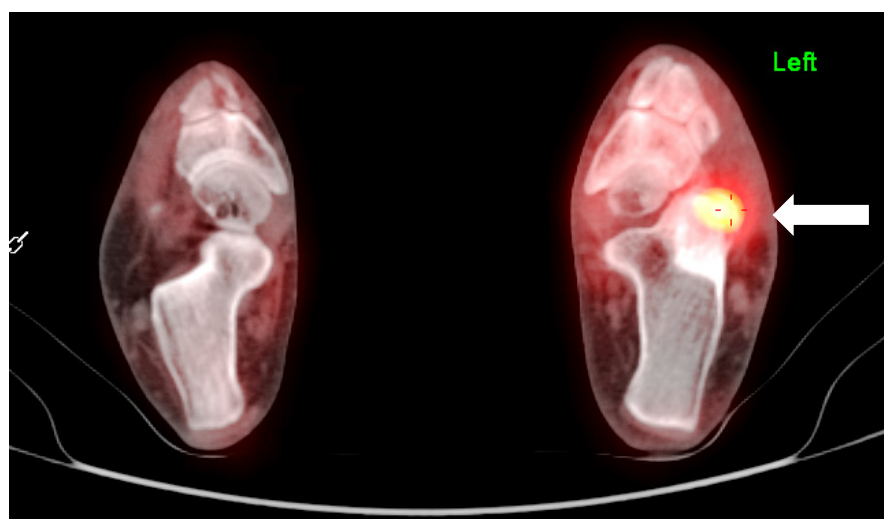
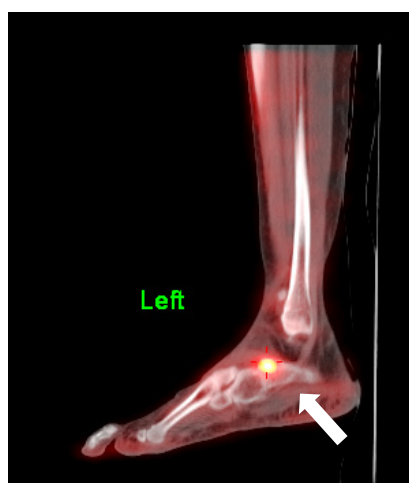
SPECT/CT (B): Shows that uptake corresponds to a process seen on CT, which is a shell formed structure in the left calcaneus near the articulation to the cuboid bone, thought to be either an avulsion or ossification of the calcaneocuboid ligament (arrows). There is no sign of stress fracture.

Teaching point

Note SPECT/CT gave the final diagnosis and the suspicion of fracture was refuted. The condition was due to degenerative changes, and therefore there was no need for extra tests or additional treatment.



(A)



(B)

9.12. CASE No. F 12

Study type:	Orthopaedic Traumatology		
Clinical indication:	Post-traumatic pain in the foot		
Keywords:	Subchondral lesion		
SPECT/CT system:	Philips Precedence 16 slice	Tracer:	^{99m}Tc -HDP
Uptake:	180 min	Dose:	752 MBq
Tube loading:	30 mAs	Tube voltage:	120 kVp

Short clinical history

A 25 year old male patient and professional athlete with pain in the right talonavicular joint after torsional trauma 3 months earlier.

Findings

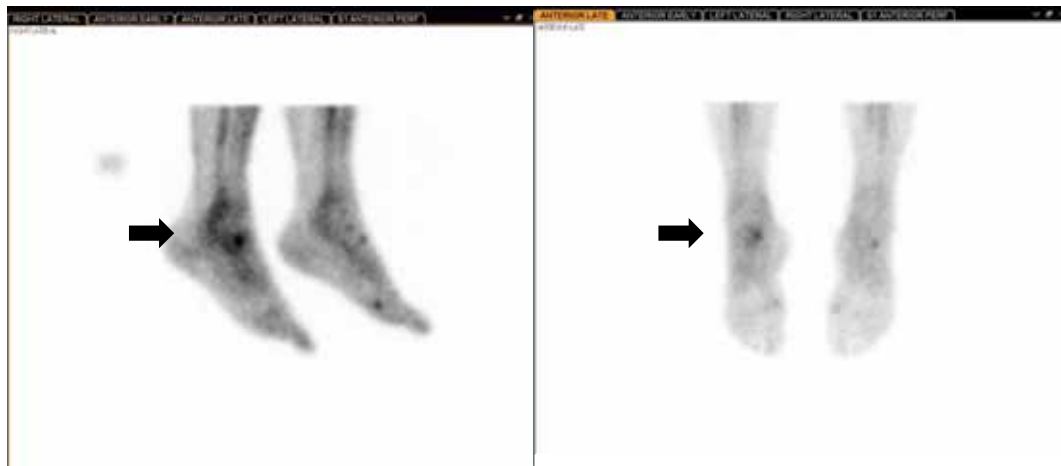
Three phase bone scan (A, B): Shows high focal uptake in the right talus (late phase, B) and increased flow (early phase, A) in the right ankle.

SPECT/CT (C): Confirms that the high uptake was located in a small area without evident traumatic lesion in the right talus close to the talonavicular joint.

Outcome and teaching point

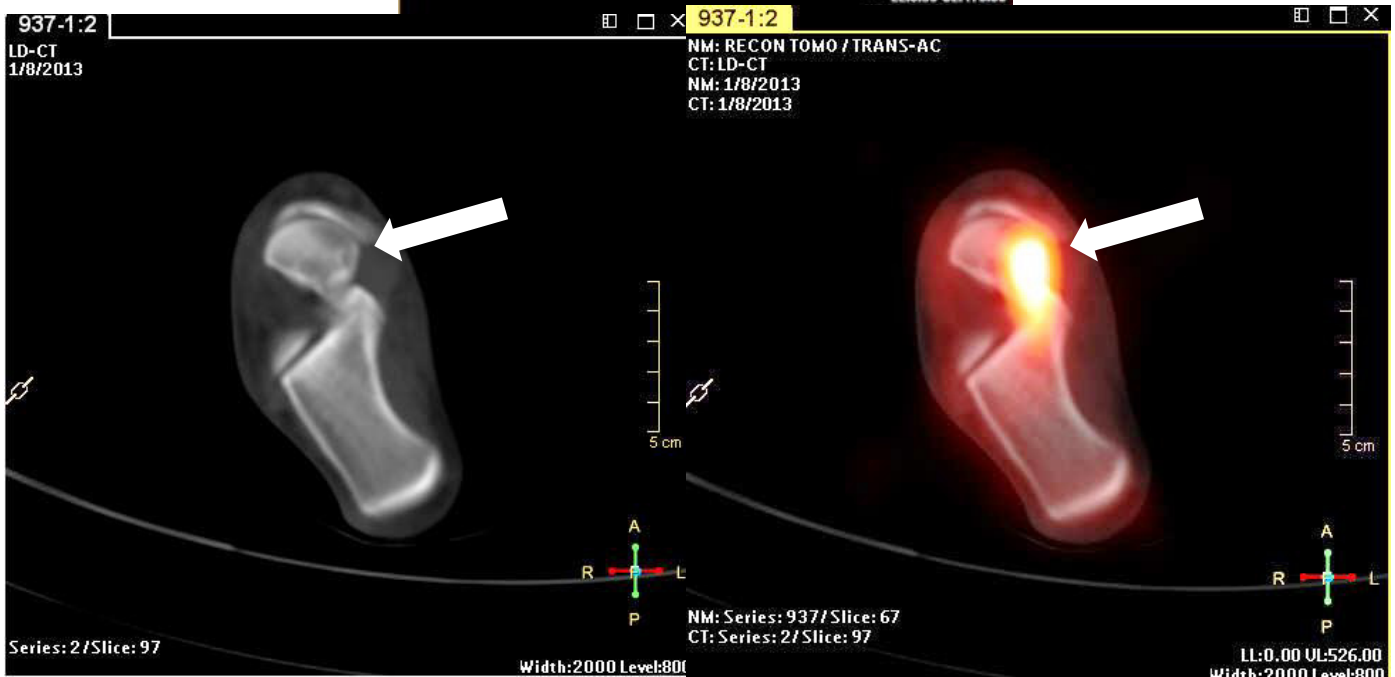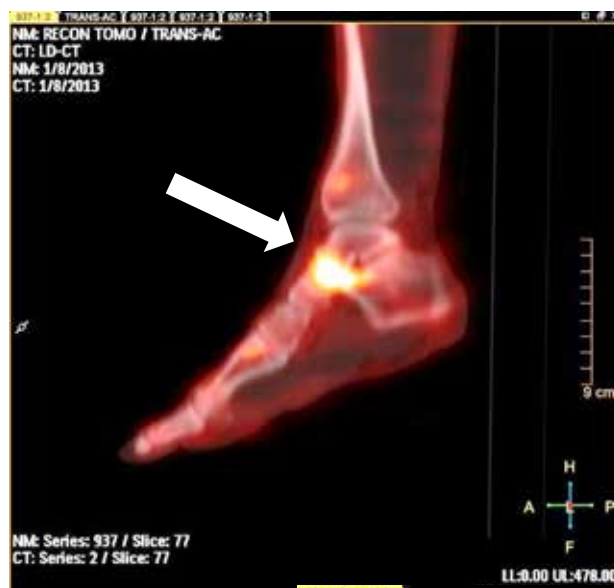MRI shows that the talar focus was a subchondral lesion. The patient was capable of continuing his career as an athlete provided that the right foot was bandaged before training.

SPECT/CT provided precise location and size of injury.



(A)

(B)



(C)

9.13. CASE No. F 13

Study type:	Rheumatology		
Clinical indication:	Tarsal pain		
Keywords:	Inflammatory arthropathy		
SPECT/CT system:	Siemens Symbia T6	Tracer:	^{99m}Tc -DPD
Uptake:	240 min	Dose:	750 MBq
Tube loading:	53 mAs	Tube voltage:	130 kVp

Short clinical history

A 79 year old female patient with right mid-tarsal pain. The pain had been getting worse over the last 3 months. There was no history of trauma and the X ray was negative.

Findings

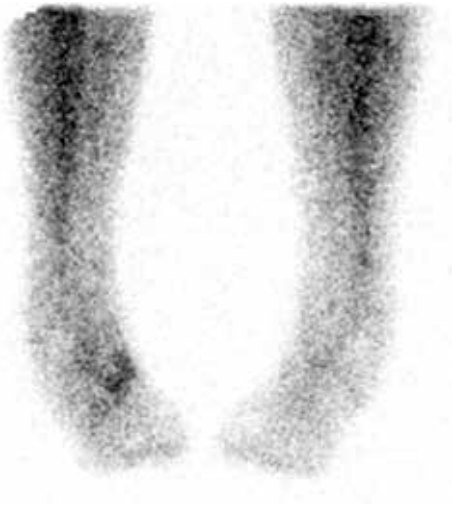Blood pool planar image (A): Shows increased activity in the medial aspect of the mid foot.

Late planar image (B): Shows increased uptake in the corresponding area of the Lisfranc.

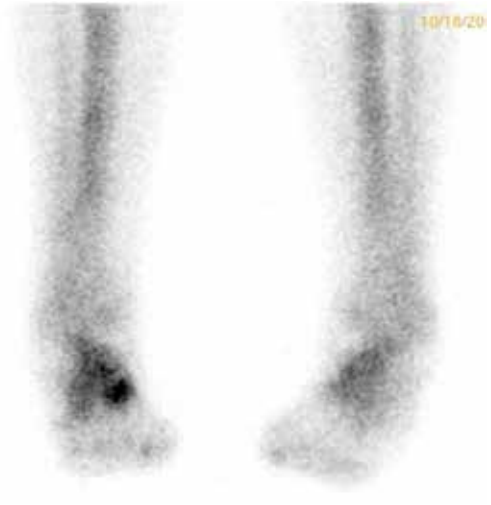SPECT/CT (C): Shows focus of increased uptake in the first cuneometatarsal joint. The CT shows slight degenerative changes (arrow) and severe osteoporosis, consistent with an inflammatory arthropathy at an initial stage.

Teaching point

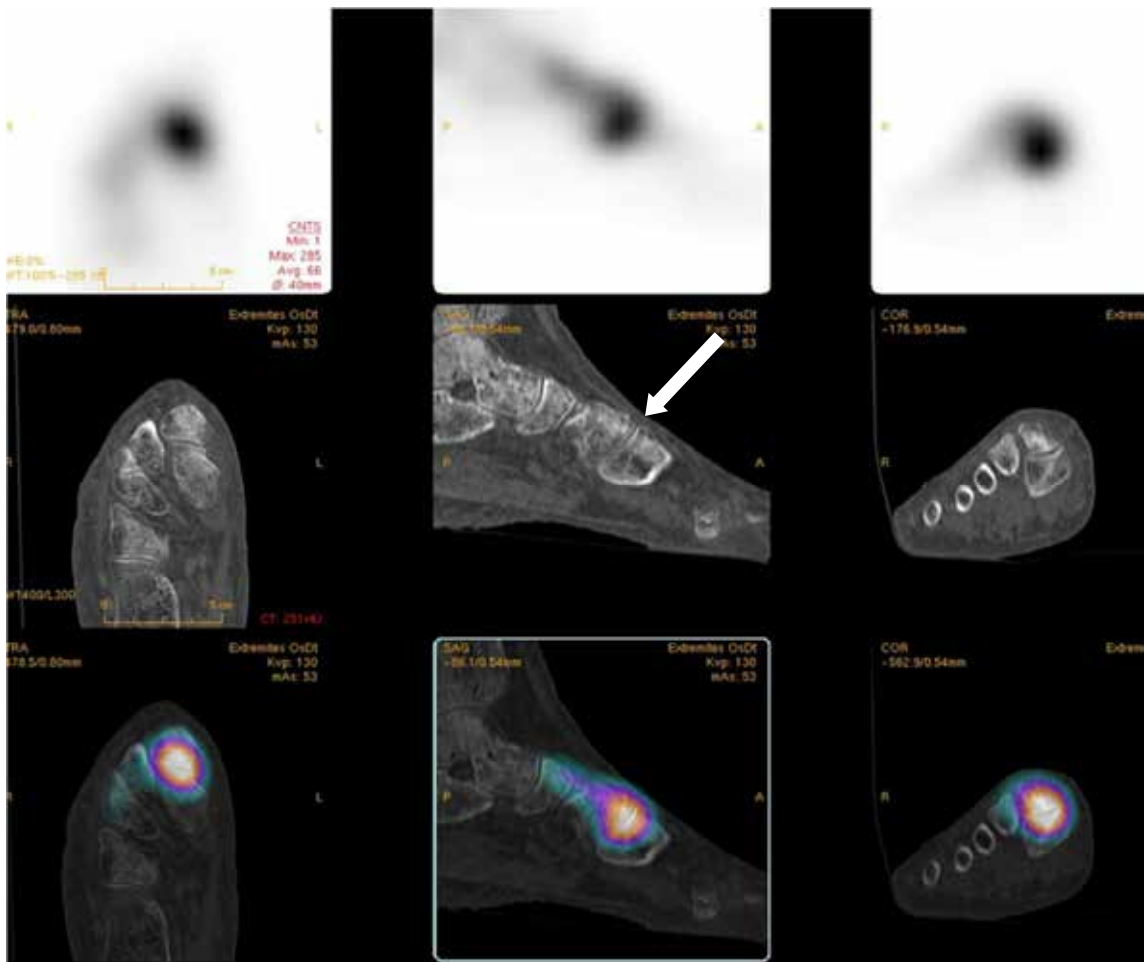
In inflammatory arthropathy, metabolic changes are observed earlier than morphologic changes.



(A)



(B)



(C)

9.14. CASE No. F 14

Study type:	Traumatology Infection		
Clinical indication:	Non-union Suspected infection Viability of bone graft		
Keywords:	Bone graft Fracture		
SPECT/CT system:	General Electric Discovery 670	Tracer:	^{99m}Tc -DPD
Uptake:	180 min	Dose:	676 MBq
Tube loading:	120–400 mAs	Tube voltage:	120 kVp

Short clinical history

A 50 year old male patient with history of a multifragment fracture in the left ankle. The patient had undergone arthrodesis, additional cement and removal of metal 3 years earlier. At that time, there was still non-union of the fracture and pain.

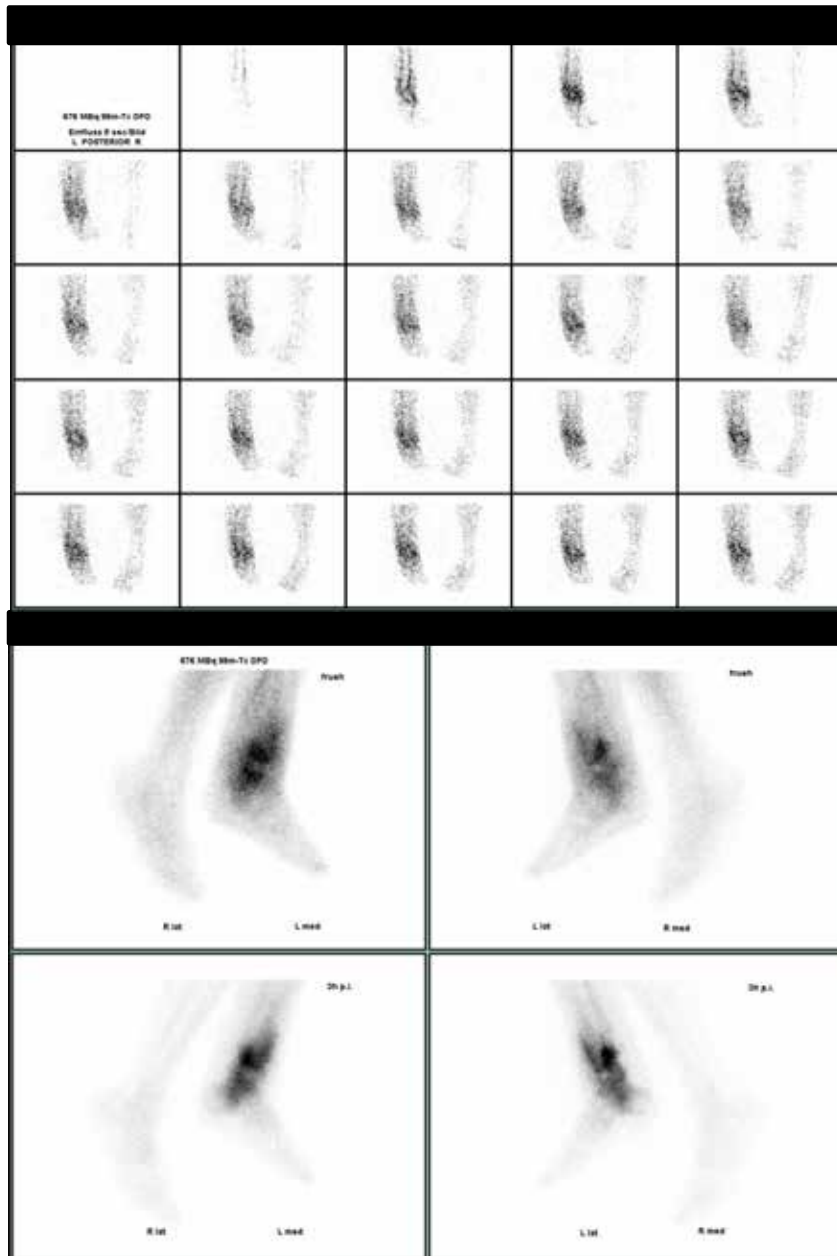
Findings

Planar bone scan (A): Shows diffusely elevated tracer uptake in all phases (flow, blood pool and late phase) in the left lower tibia, ankle and calcaneus, suggestive for infection.

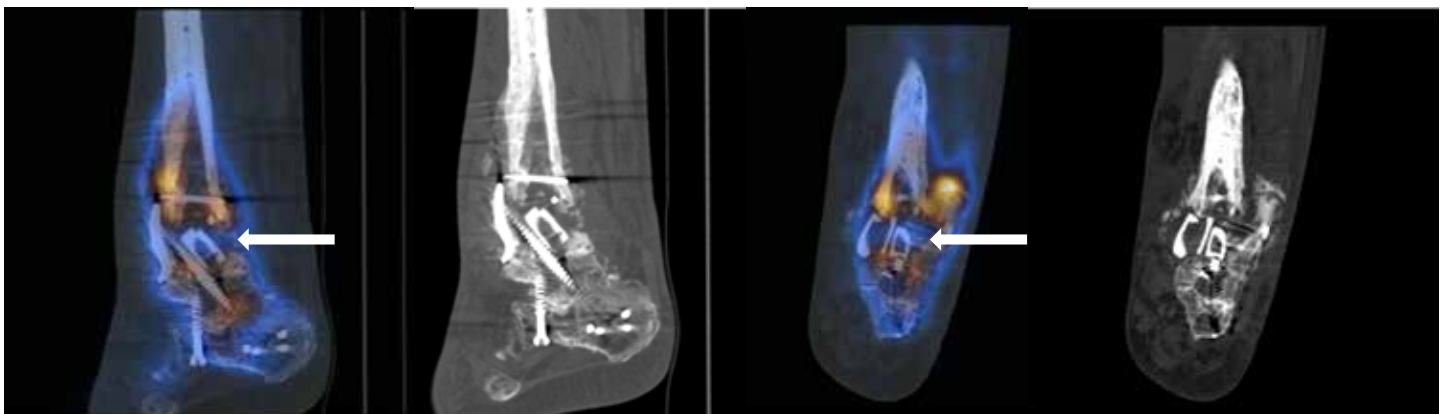SPECT/CT (B): Also shows the non-vital bone graft inserted in the extensively destroyed ankle. No uptake is noted in this graft (arrows).

Teaching point

SPECT/CT can identify viability of bone grafts in surgically altered areas and complex post-surgical situations.



(A)



(B)

9.15. CASE No. F 15

Study type: Infection

Clinical indication: Suspicion of septic osteitis

Keywords: Osteomyelitis

SPECT/CT system: Siemens Symbia T6

Tracer: ^{99m}Tc -DPD

Uptake: 240 min

Dose: 787 MBq

Tube loading: 75 mAs

Tube voltage: 130 kVp

Short clinical history

A 57 year old male patient with morbid obesity/lymphoedema. The patient presented major bedsores in the left foot. Septic osteitis was suspected.

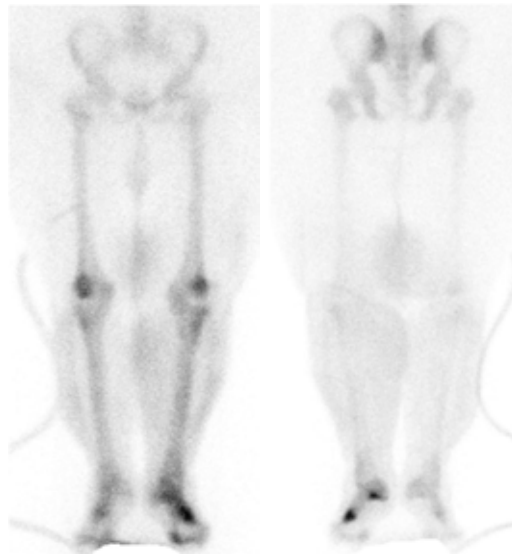
Findings

Planar, late phase (A: anterior, B: posterior): Shows foci of increased uptake in the left talar area and in the lateral aspect of the metatarsal area.

SPECT/CT (C): The foci correspond to areas of bone resorption in the calcaneal tuberosity and at the basis of the 5th metatarsal bone (arrows), which also appears to be fragmented, consistent with osteomyelitis.

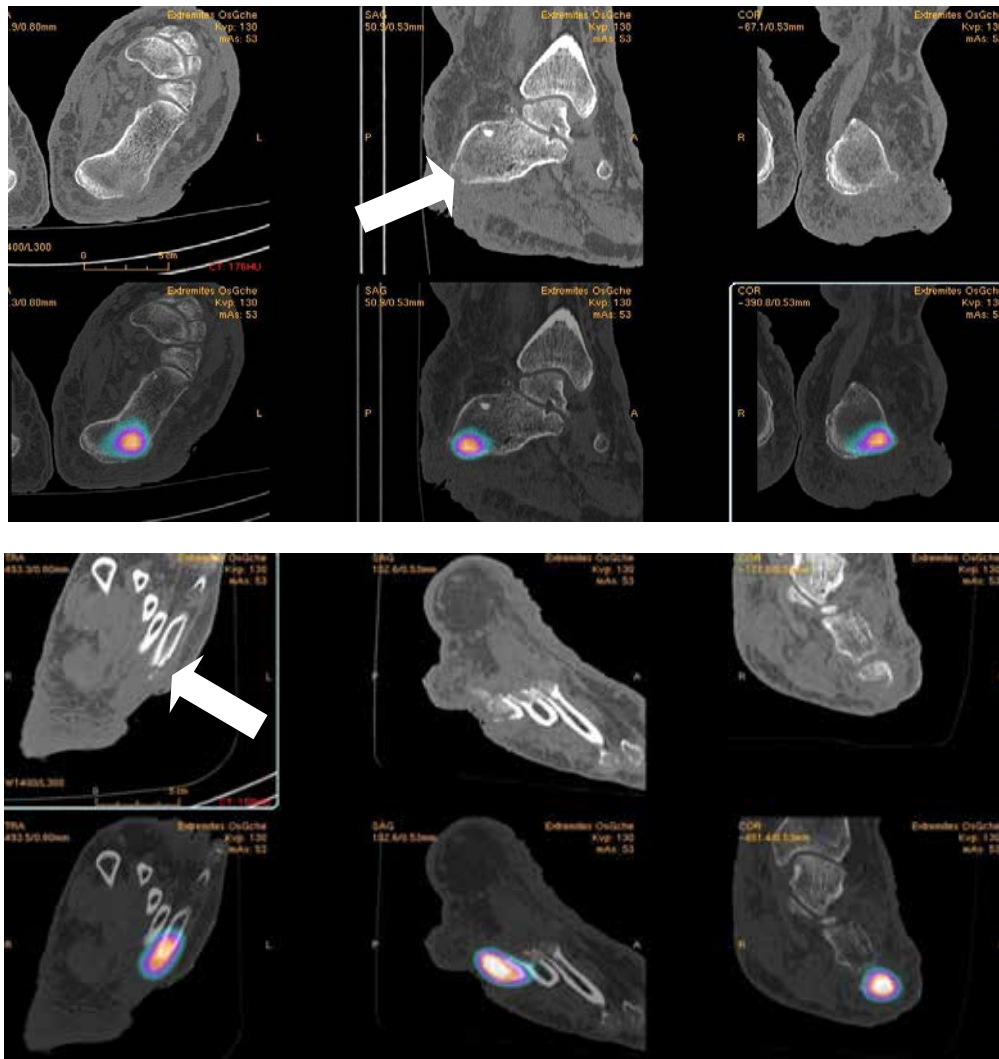
Teaching point

CT is important to characterize the bone lesions and to accurately identify osteomyelitis.



(A)

(B)



(C)

9.16. CASE No. F 16

Study type:	Orthopaedic		
Clinical indication:	Suspicion of diabetic osteoarthropathy		
Keywords:	Charcot foot		
SPECT/CT system:	Siemens Symbia T6	Tracer:	^{99m}Tc -DPD
Uptake:	240 min	Dose:	700 MBq
Tube loading:	66 mAs	Tube voltage:	130 kVp

Short clinical history

A 71 year old male patient with longstanding history of type II diabetes. In addition, the patient had developed peripheral arterial disease.

Findings

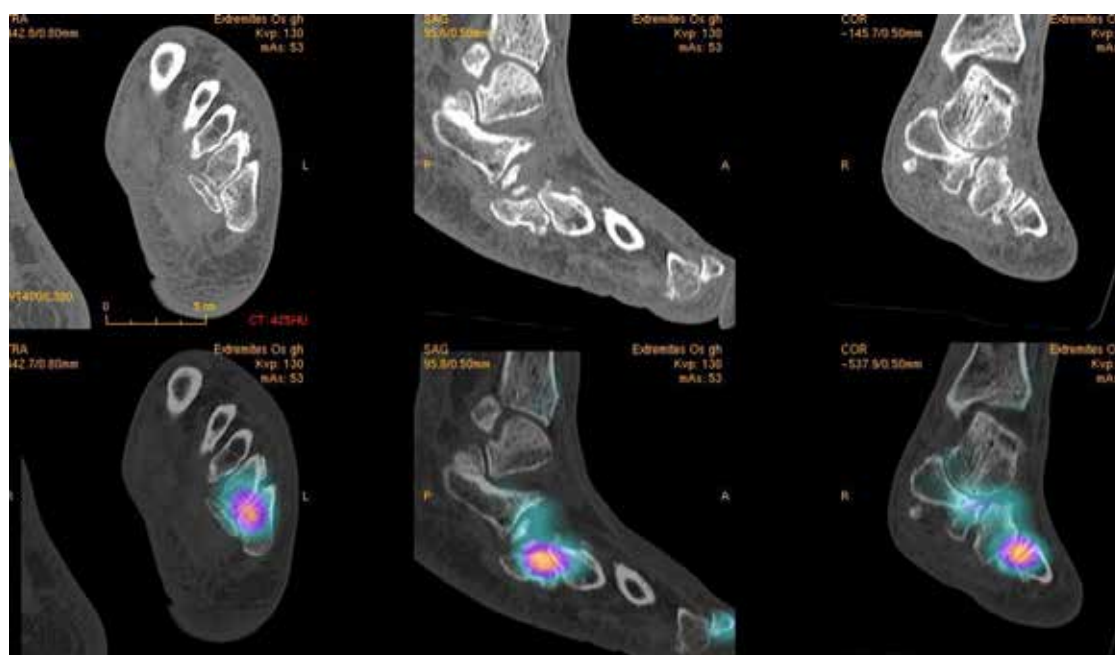
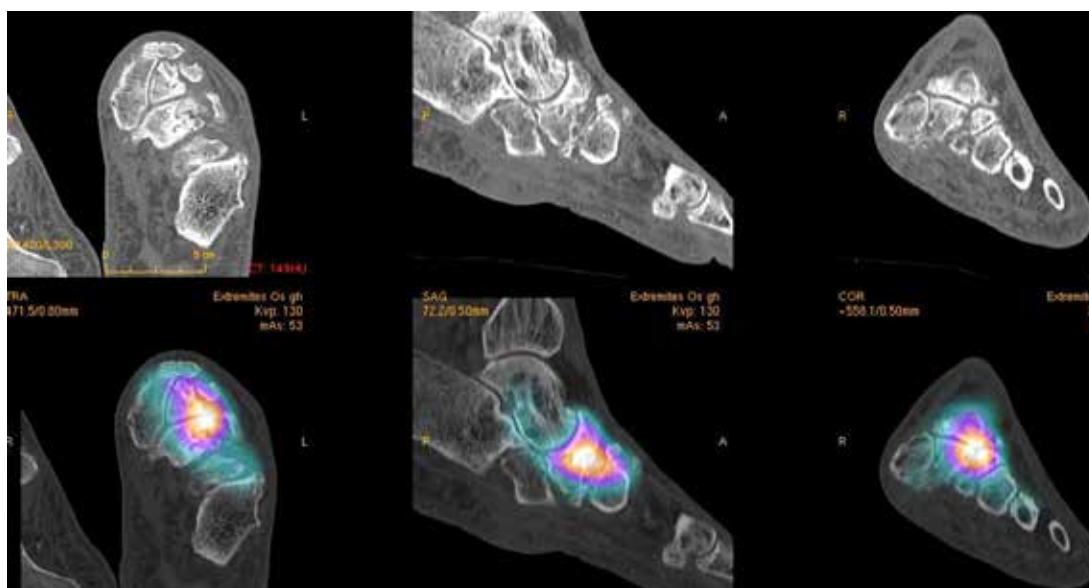
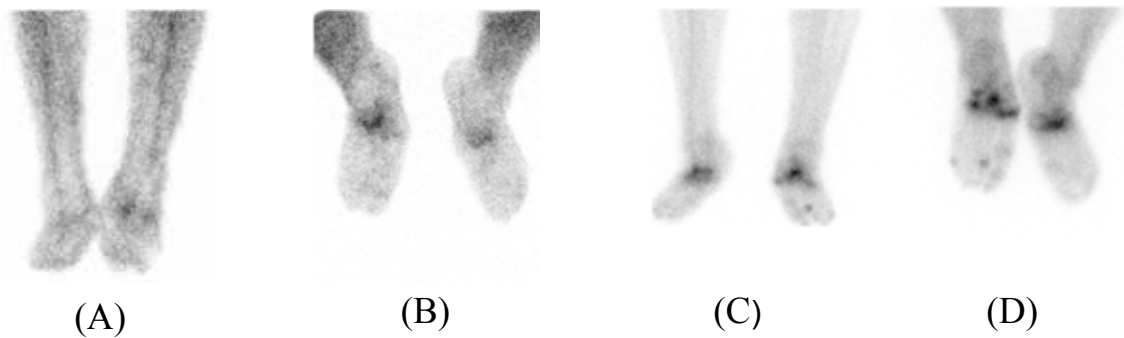
Blood pool planar (A, B: anterior and plantar views): Shows increased uptake of the mid-tarsal area, bilaterally (L > R).

Delayed planar images (C, D: anterior and plantar views): Show increased bone remodelling in the corresponding areas.

SPECT/CT (E, F): Show that the areas of increased uptake correspond to extensively destructive osteoarthropathy, consistent with Charcot foot.

Teaching point

This case illustrates the typical pattern of morphologic and metabolic changes present in Charcot foot.



9.17. CASE No. F 17

Study type:	Infection		
Clinical indication:	Suspicion of osteomyelitis		
Keywords:	Osteomyelitis		
SPECT/CT system:	Siemens Symbia T6	Tracer:	^{99m}Tc -DPD
Uptake:	240 min	Dose:	800 MBq
Tube loading:	76 mAs	Tube voltage:	130 kVp

Short clinical history

A 77 year old male patient with plantar ulcer in the left foot. The patient had pain in the 5th toe. There was no history of diabetes.

Findings

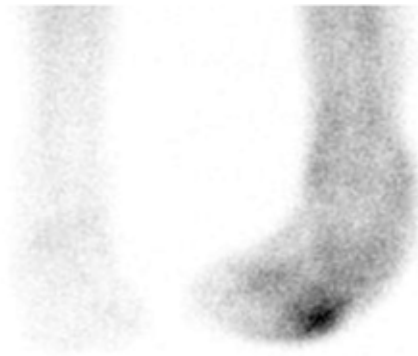Planar blood pool (A) and late images (B): Show highly increased activity in the left ankle and foot and more importantly on the lateral aspect of the distal foot.

SPECT/CT (C): Shows highly increased uptake at the distal extremity of the 5th metatarsal bone, which appears in contact with the ulcer. There is also an extensive periosteal reaction.

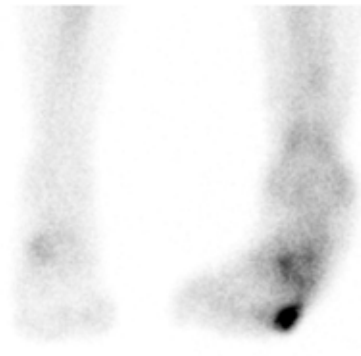
The findings are consistent with osteomyelitis.

Teaching point

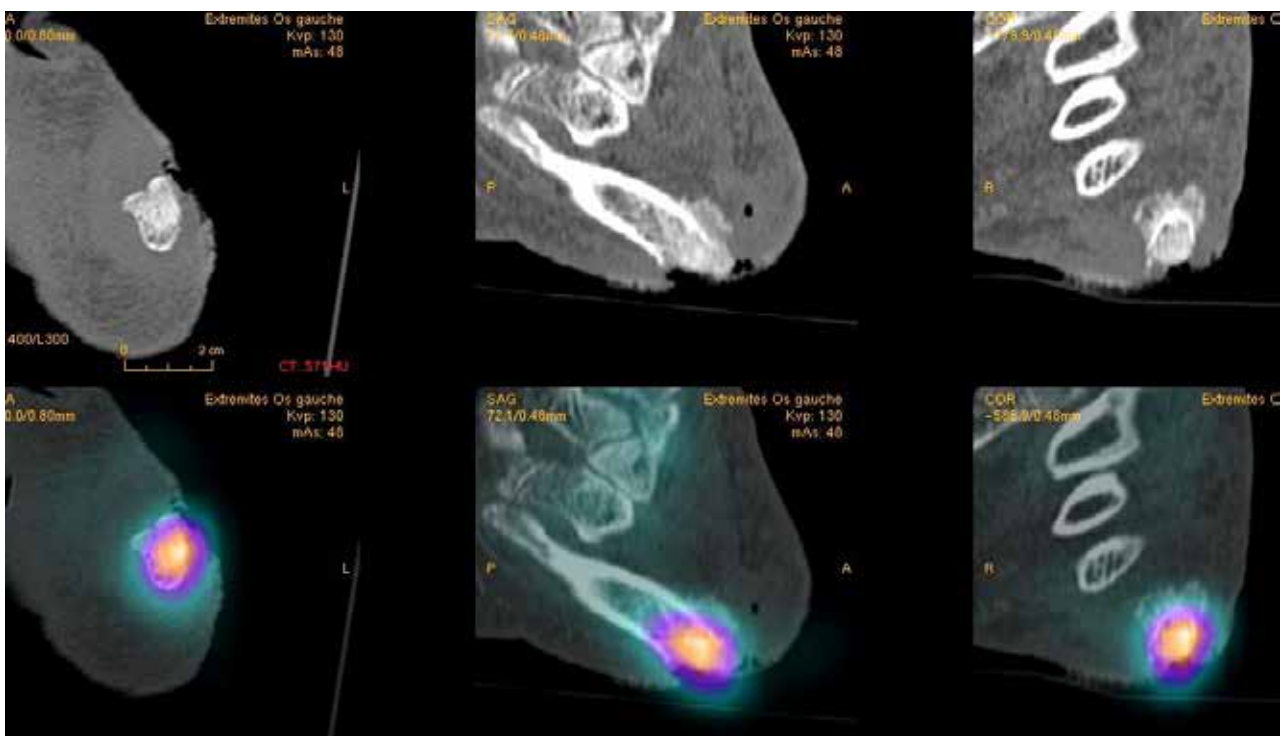
CT and SPECT combine for a precise assessment of the extent of the disease. The metabolic study is important to demonstrate that the infection is still active.



(A)



(B)



(C)

10. METASTATIC DISEASE

10.1. CASE No. MD 1

Study type:	Oncology		
Clinical indication:	Cancer follow-up		
Keywords:	Metastasis		
SPECT/CT system:	Siemens Symbia T6	Tracer:	^{99m}Tc -DPD
Uptake:	240 min	Dose:	750 MBq
Tube loading:	112 mAs	Tube voltage:	130 kVp

Short clinical history

A 69 year old female patient with breast cancer. The patient had surgery 3 years earlier and was at the time undergoing hormone therapy. She came for a routine follow-up.

Findings

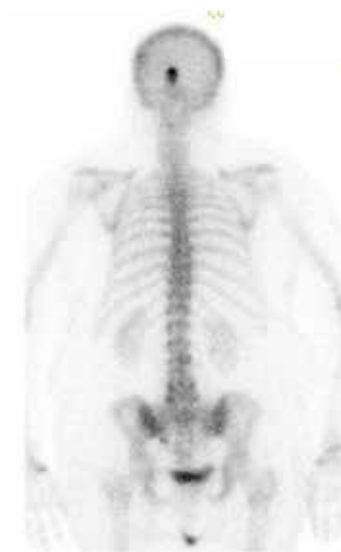Whole body image (A): Shows solitary focus of increased uptake in the mid occipital area.

SPECT/CT (B): Shows osteolytic bone metastases.

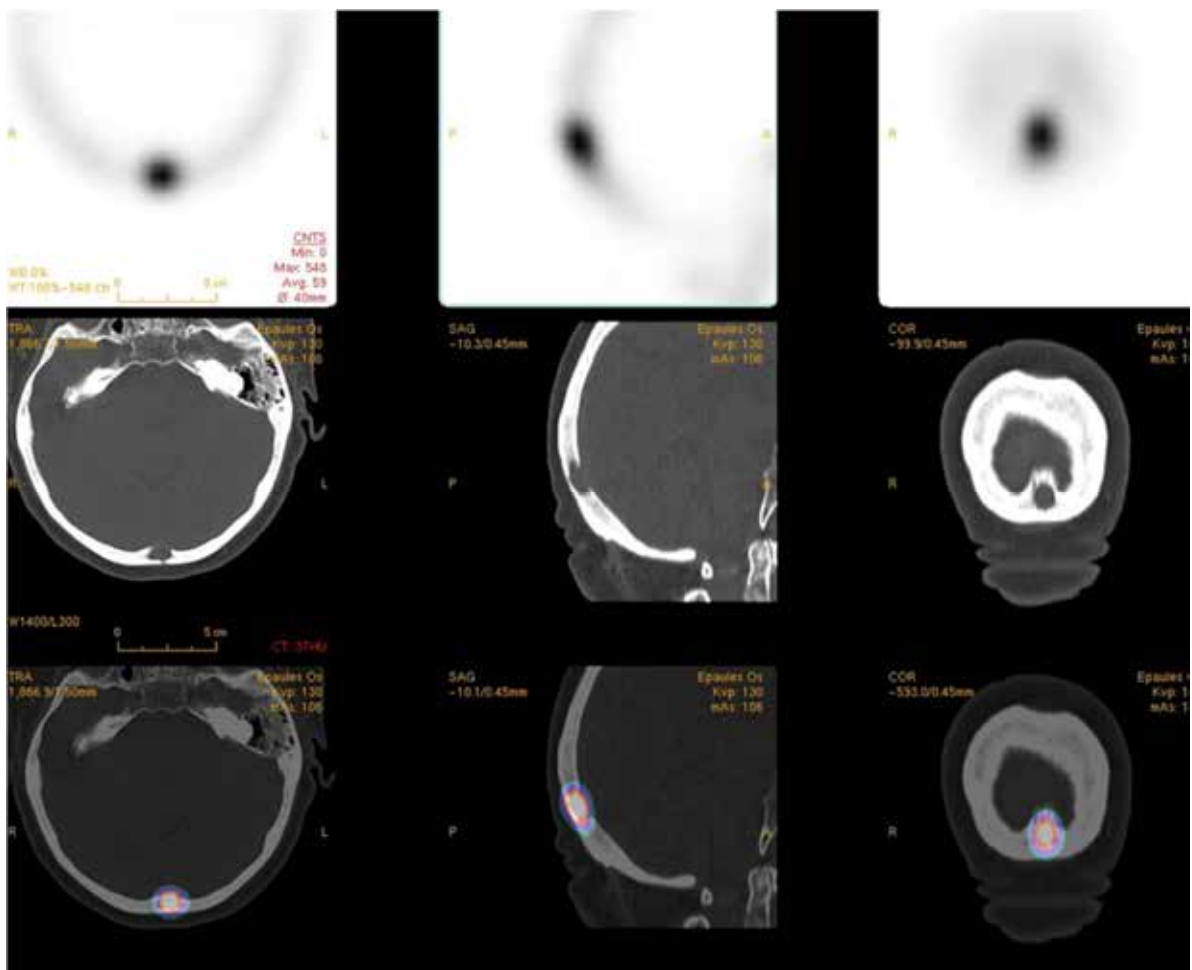
Outcome and teaching point

The patient underwent chemotherapy.

SPECT/CT showed an atypical appearance for osteolytic metastases, which most often do not appear as hot spots on bone scintigraphy.



(A)



(B)

10.2. CASE No. MD 2

Study type:	Oncology		
Clinical indication:	Recurrence of cancer		
Keywords:	Metastasis		
SPECT/CT system:	Siemens Symbia T6	Tracer:	^{99m}Tc -DPD
Uptake:	240 min	Dose:	730 MBq
Tube loading:	161 mAs	Tube voltage:	130 kVp

Short clinical history

An 81 year old male patient with history of prostate cancer. The patient had rapidly increasing levels of PSA.

Findings

Whole body image (A, B): Shows low renal uptake and highly heterogeneous uptake of the spine, ribs, pelvis and femurs.

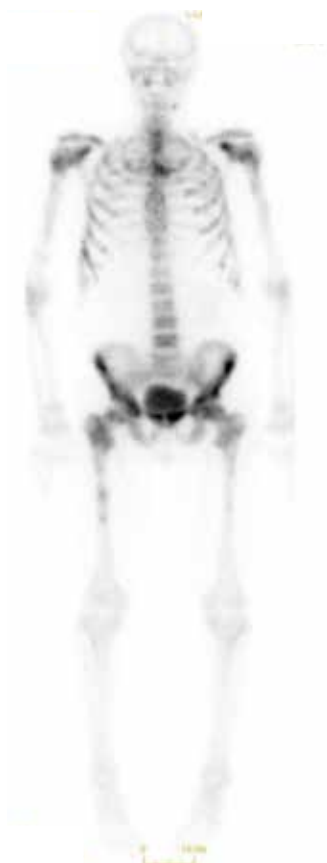MIP image (C): Shows patchy uptake, with osteoblastic lesions.

SPECT/CT (D, E): Shows patchy uptake, with osteoblastic lesions.

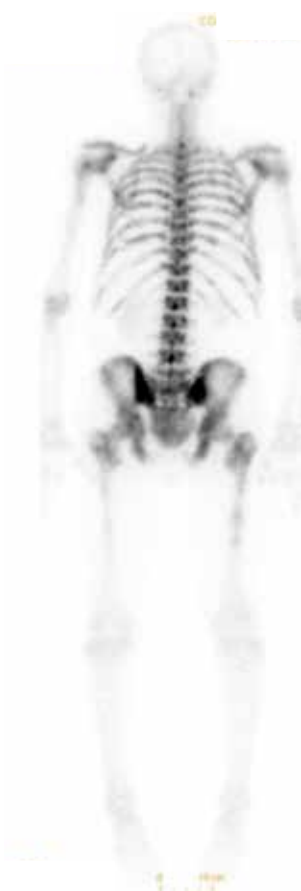Outcome and teaching point

The patient underwent chemotherapy.

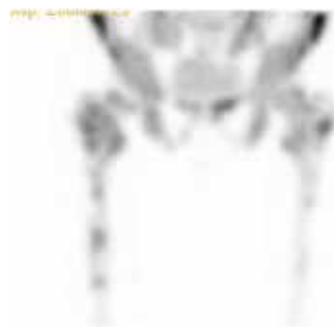Even though metastases are clearly identified on the planar images, SPECT/CT greatly improves the sensitivity and allows the characterization of the types of metastasis.



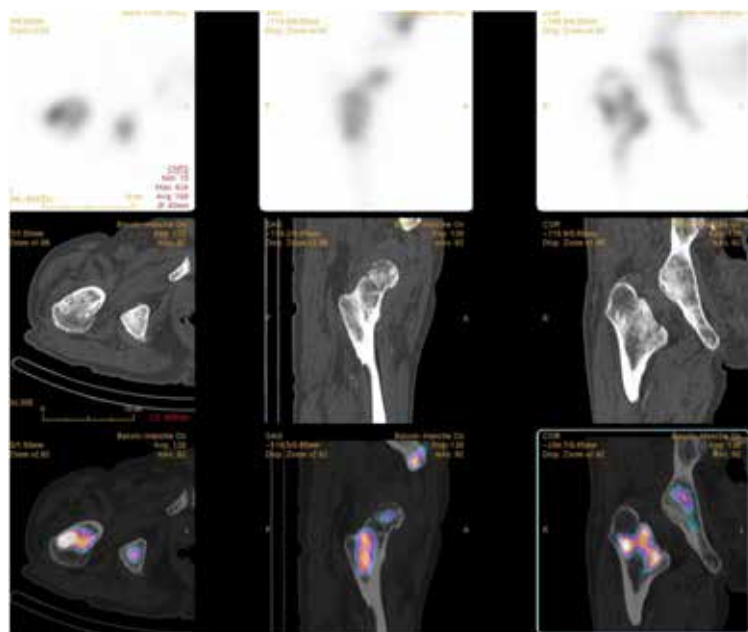
(A)



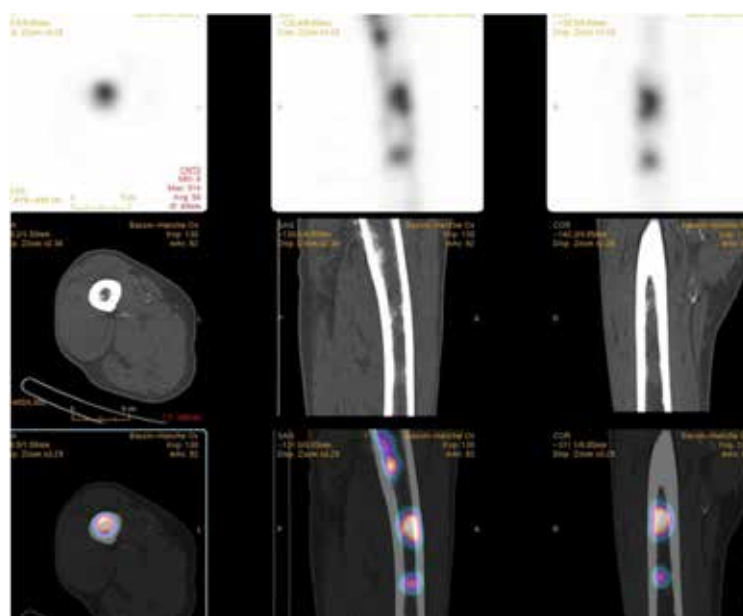
(B)



(C)



(D)



(E)

10.3. CASE No. MD 3

Study type:	Oncology		
Clinical indication:	Cancer staging		
Keywords:	Metastasis		
SPECT/CT system:	Siemens Symbia T6	Tracer:	^{99m}Tc -DPD
Uptake:	240 min	Dose:	758 MBq
Tube loading:	143 mAs	Tube voltage:	130 kVp

Short clinical history

A 42 year old male patient with carcinoma of the bladder; initial staging. The patient had no complaints.

Findings

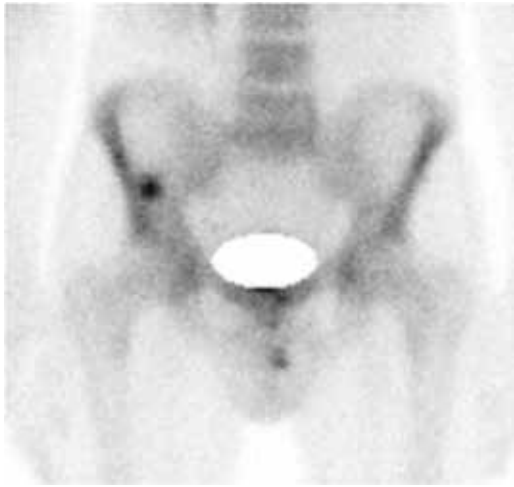
Planar images (A, B): Show focus of increased uptake in the right iliac bone.

SPECT/CT (C): Shows no definite osteoblastic or lytic changes, but a slightly heterogeneous bone structure (arrow), consistent with a metastasis.

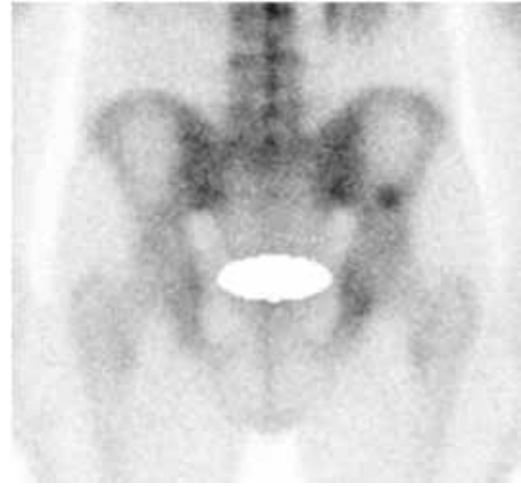
Outcome and teaching point

The metastasis was confirmed with MRI, and chemotherapy was started.

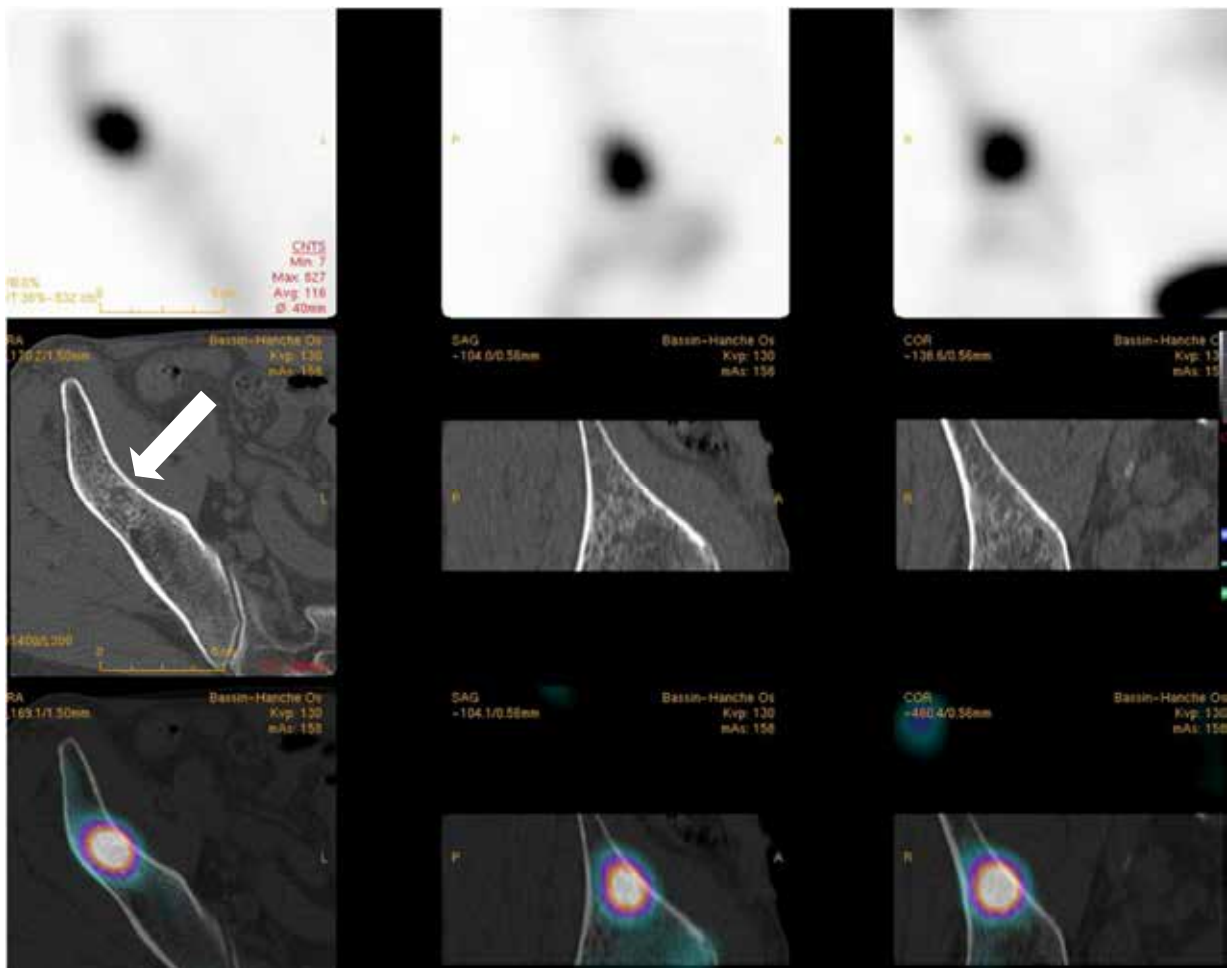
This case confirms the very high sensitivity of SPECT in the detection of bone metastases.



(A)



(B)



(C)

10.4. CASE No. MD 4

Study type:	Oncology		
Clinical indication:	Prostate cancer Restaging Rising PSA		
Keywords:	Metastasis		
SPECT/CT system:	Siemens Symbia T2	Tracer:	^{99m}Tc -DPD
Uptake:	180 min	Dose:	667 MBq
Tube loading:	120 mAs	Tube voltage:	80 kVp

Short clinical history

An 83 year old male patient with a history of prostate cancer. The patient was undergoing consecutive hormonal therapy. SPECT/CT was requested for restaging purposes.

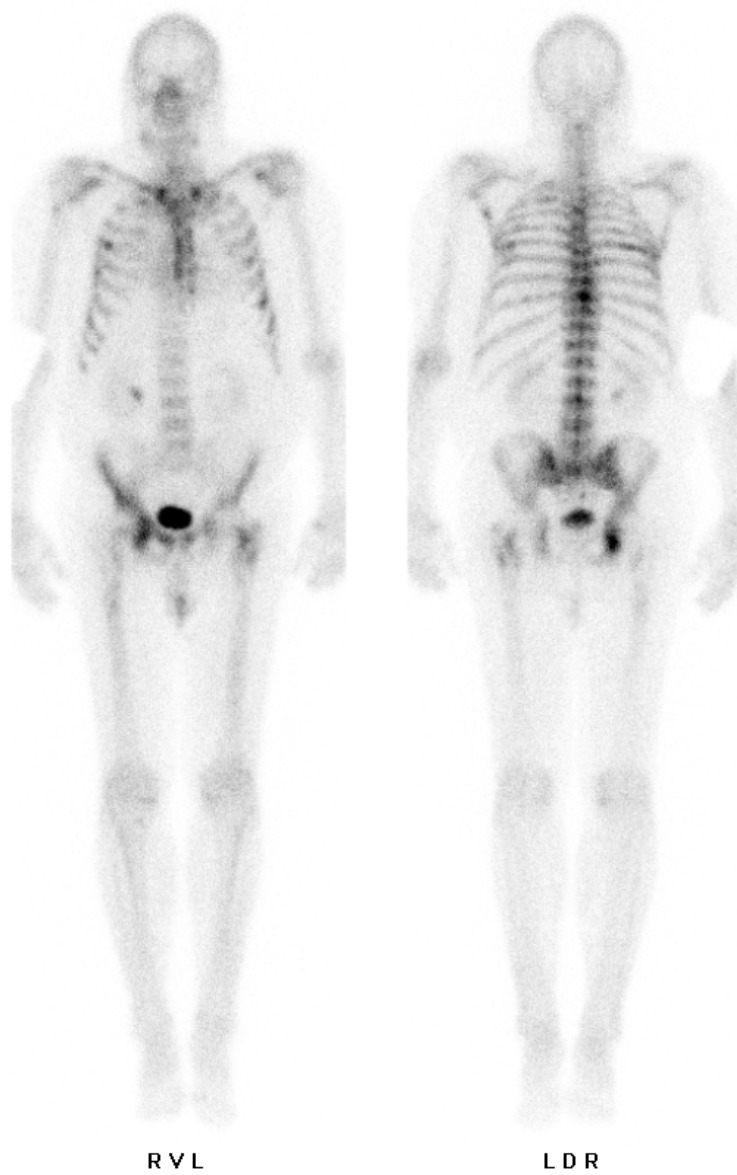
Findings

Planar image (A): Shows focal uptake in the vertebral spine, ribs and pelvis and both femora. In addition, the image shows degenerative uptake in both knees.

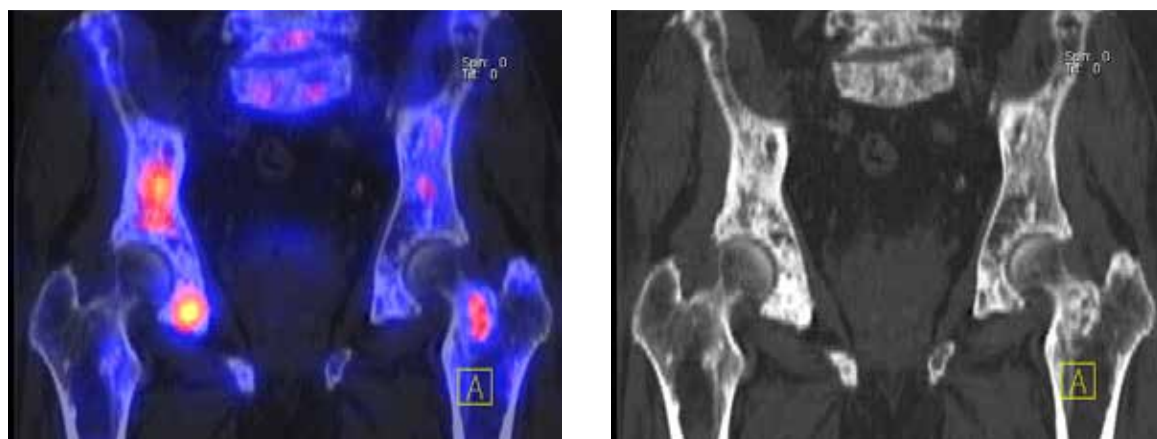
SPECT/CT (B): Shows significant focal uptake in the predominantly osteoblastic metastases in the os ilium, lumbar vertebrae and femora.

Outcome

Hormonal therapy was continued.



(A)



(B)

10.5. CASE No. MD 5

Study type:	Oncology		
Clinical indication:	Renal cell carcinoma Restaging		
Keywords:	Metastasis		
SPECT/CT system:	Siemens Symbia T2	Tracer:	^{99m} Tc-DPD
Uptake:	180 min	Dose:	651 MBq
Tube loading:	120 mAs	Tube voltage:	80 kVp

Short clinical history

A 76 year old female patient with history of renal cell carcinoma. Restaging is being performed following a pathologic fracture of the right humerus.

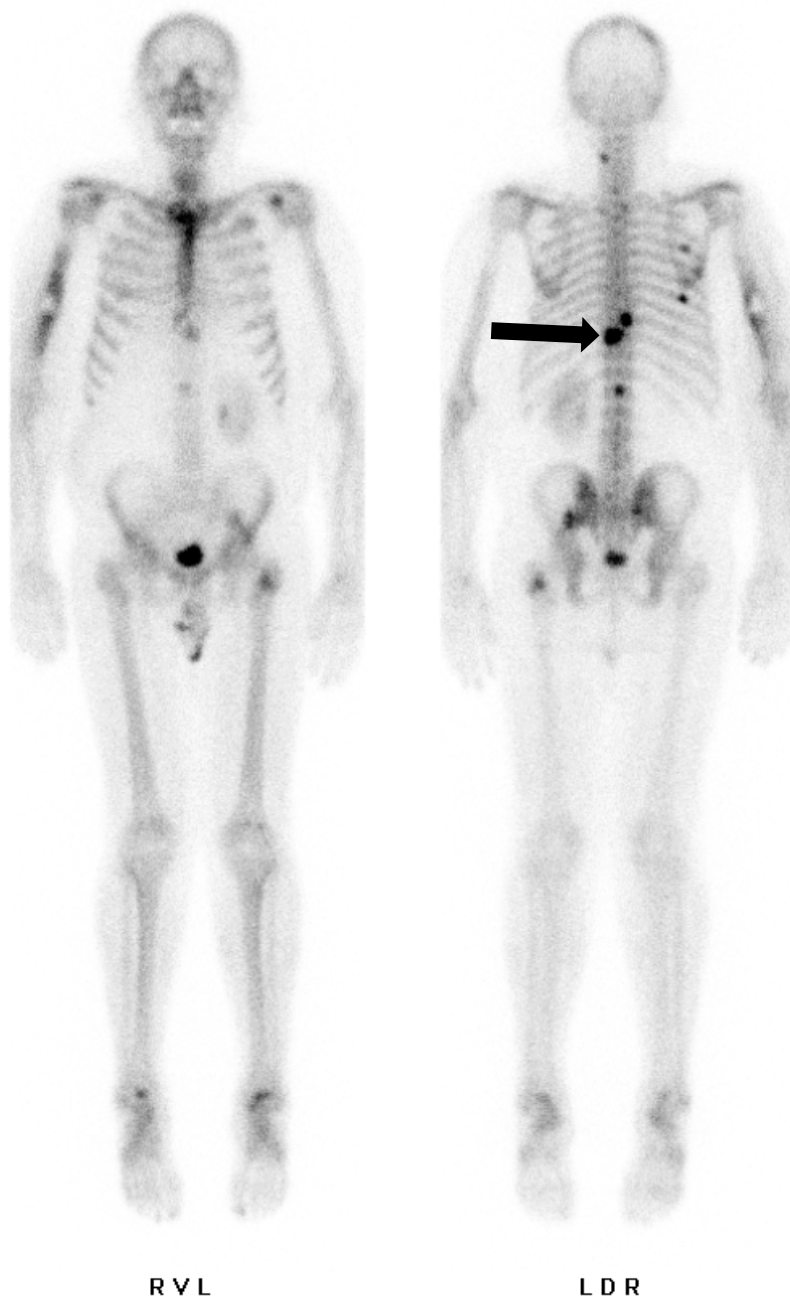
Findings

Planar image (A): Shows photopaenia in the right humerus (pathologic fracture with osteolysis) and multiple foci in the 3rd and 6th ribs, 7th and 8th thoracic vertebrae (arrow), in the 1st lumbar vertebra and the left ilium.

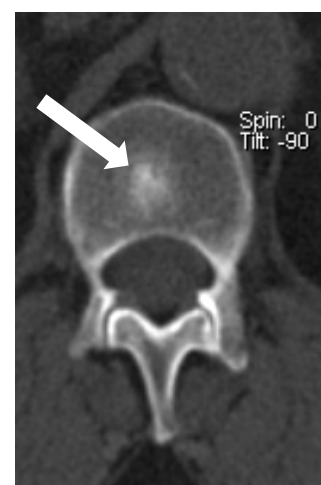
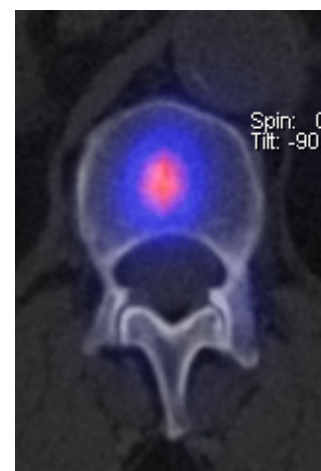
SPECT/CT (B): Shows focal tracer uptake within the vertebral body in the sclerotic lesions (arrow), typical for osteosclerotic metastases.

Outcome

The patient underwent chemotherapy.



(A)



(B)

10.6. CASE No. MD 6

Study type:	Oncology		
Clinical indication:	Restaging Breast cancer		
Keywords:	Metastasis		
SPECT/CT system:	Siemens Symbia T2	Tracer:	^{99m}Tc -DPD
Uptake:	180 min	Dose:	648 MBq
Tube loading:	120 mAs	Tube voltage:	80 kVp

Short clinical history

A 69 year old female patient with history of breast cancer treated with surgery and combined radiochemotherapy. Restaging due to thoracic pain.

Findings

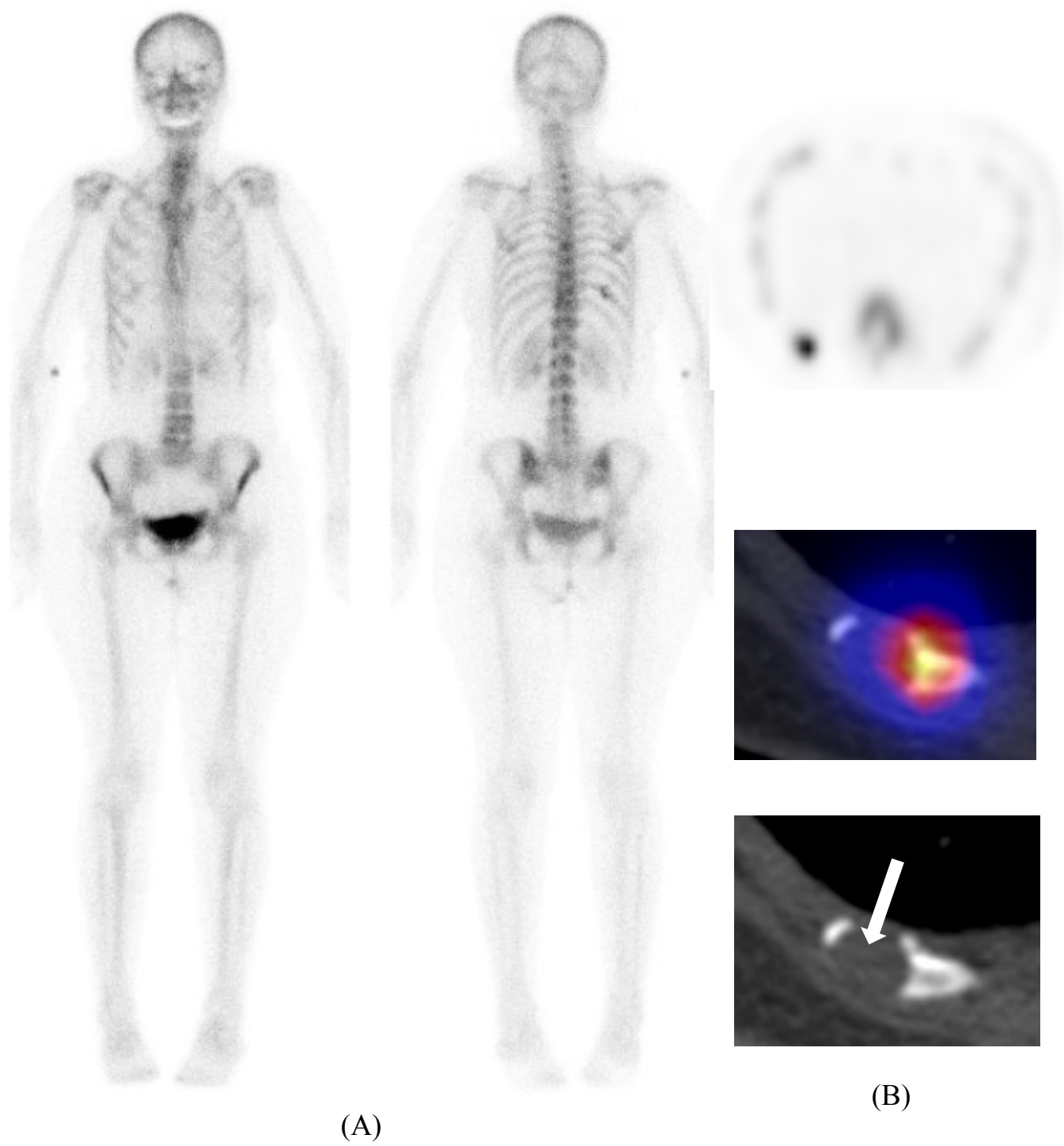
Planar images (A): Show new focal uptake in the right 9th dorsal rib. Furthermore, whole body scintigraphy shows mild polyarthrosis and scoliosis.

SPECT/CT (B): Shows osteolysis (arrow) with hyperreactive margin. The lesion represents a pathologic fracture due to an isolated osseous metastasis.

Outcome and teaching point

The patient underwent external radiotherapy.

Note SPECT/CT allows the diagnosis of an isolated metastasis that cannot be differentiated from a fracture or other benign process in planar imaging alone.



10.7. CASE No. MD 7

Study type:	Oncology		
Clinical indication:	Restaging Breast cancer		
Keywords:	Metastasis		
SPECT/CT system:	Siemens Symbia T2	Tracer:	^{99m}Tc -DPD
Uptake:	180 min	Dose:	657 MBq
Tube loading:	120 mAs	Tube voltage:	80 kVp

Short clinical history

A 48 year old female patient with history of breast cancer and treated with surgery. The patient refused neoadjuvant therapy. SPECT/CT was requested for restaging purposes.

Findings

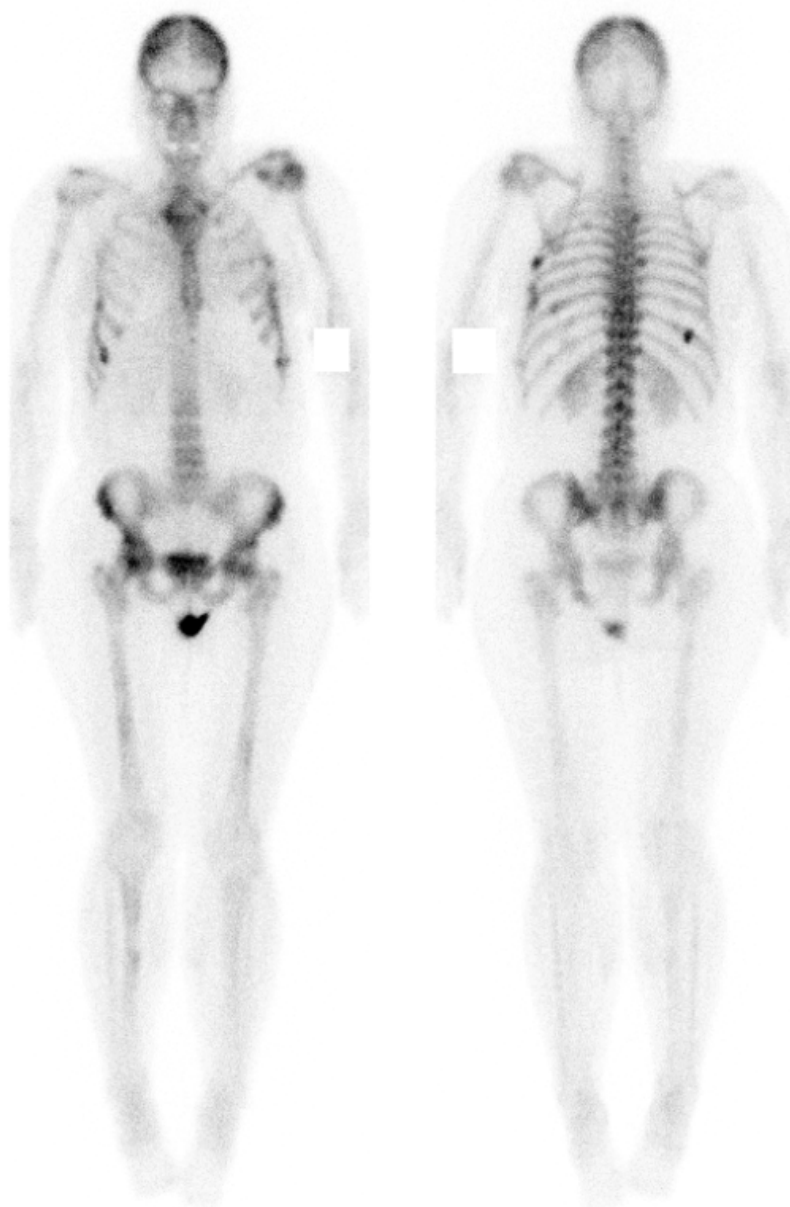
Planar image (A): Shows lesions with pathologic uptake in the ribs and vertebral spine. There are signs of bone marrow disease in both femora and tibiae.

SPECT/CT (B, C): Shows some lesions with pathologic bone metabolism (B) and other lesions without (C, arrows). The latter correspond to osteolytic metastases.

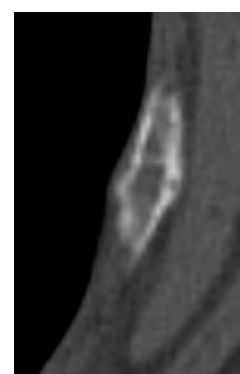
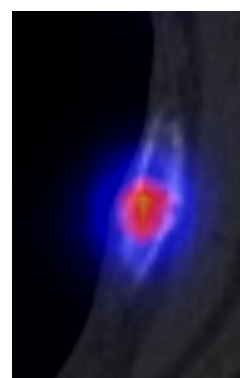
Outcome and teaching point

The patient underwent chemotherapy.

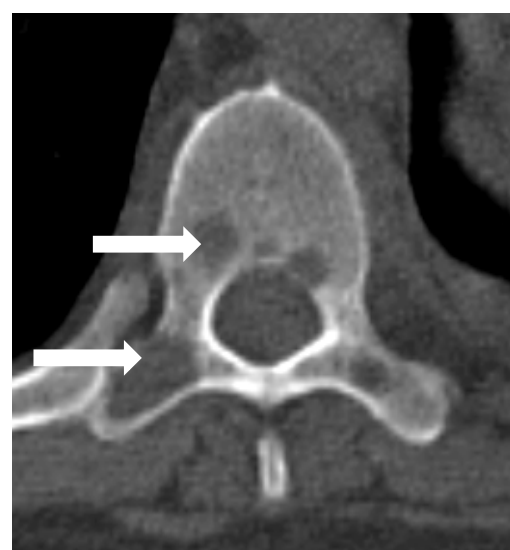
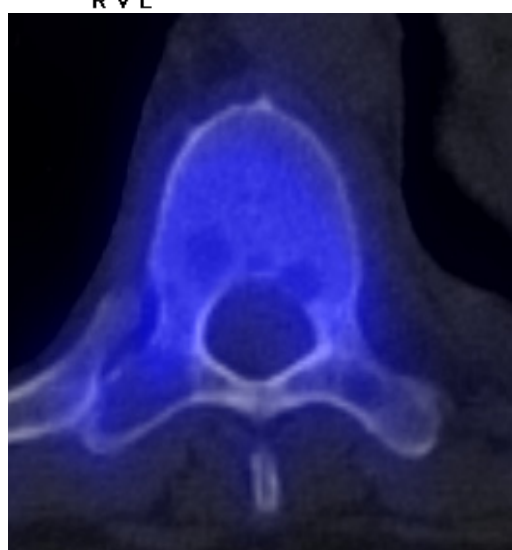
Note the typical pattern of a patient with osteolytic metastases.



(A)



(B)



(C)

10.8. CASE No. MD 8

Study type:	Oncology		
Clinical indication:	Restaging Non-small cell lung cancer		
Keywords:	Metastasis		
SPECT/CT system:	Siemens Symbia T2	Tracer:	^{99m}Tc -DPD
Uptake:	180 min	Dose:	657 MBq
Tube loading:	120 mAs	Tube voltage:	80 kVp

Short clinical history

A 76 year old female patient with history of non-small cell lung cancer who was treated with surgery and adjuvant chemotherapy. SPECT/CT was requested for restaging purposes.

Findings

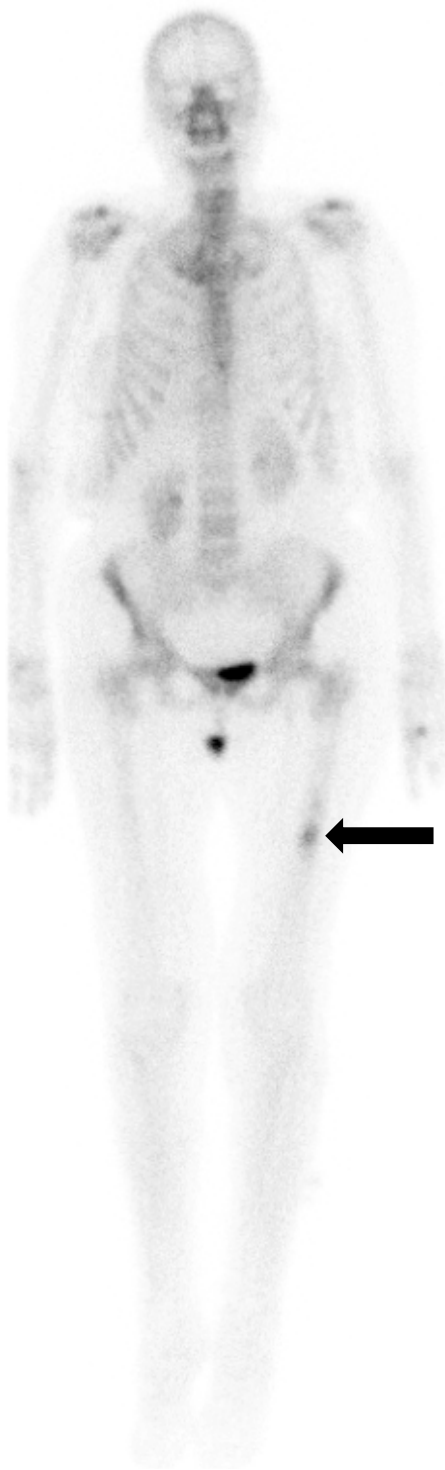Planar image (A): Shows an isolated lesion in the left femur (arrow).

SPECT/CT (B): Shows an isolated osseous metastasis with thinning of the corticalis (arrow) and bone marrow replacement.

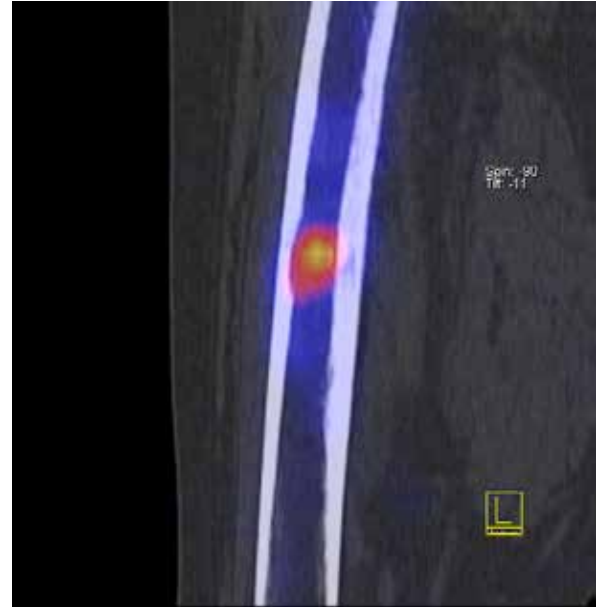
Outcome and teaching point

The patient underwent external radiotherapy.

Note SPECT/CT allows the specific characterization of lesions, especially in oncologic patients.



(A)



(B)

10.9. CASE No. MD 9

Study type:	Oncology		
Clinical indication:	High grade prostate carcinoma Staging		
Keywords:	Metastasis Tendinopathy		
SPECT/CT system:	General Electric Discovery 670	Tracer:	^{99m}Tc -DPD
Uptake:	180 min	Dose:	650 MBq
Tube loading:	120–400 mAs	Tube voltage:	120 kVp

Short clinical history

A 55 year old male patient with prostate cancer; initial staging.

Findings

Planar bone scan (A): Shows degenerative lesions in the cervical spine and a suspicious lesion in the left trochanter minor, which could also represent insertion tendinopathy.

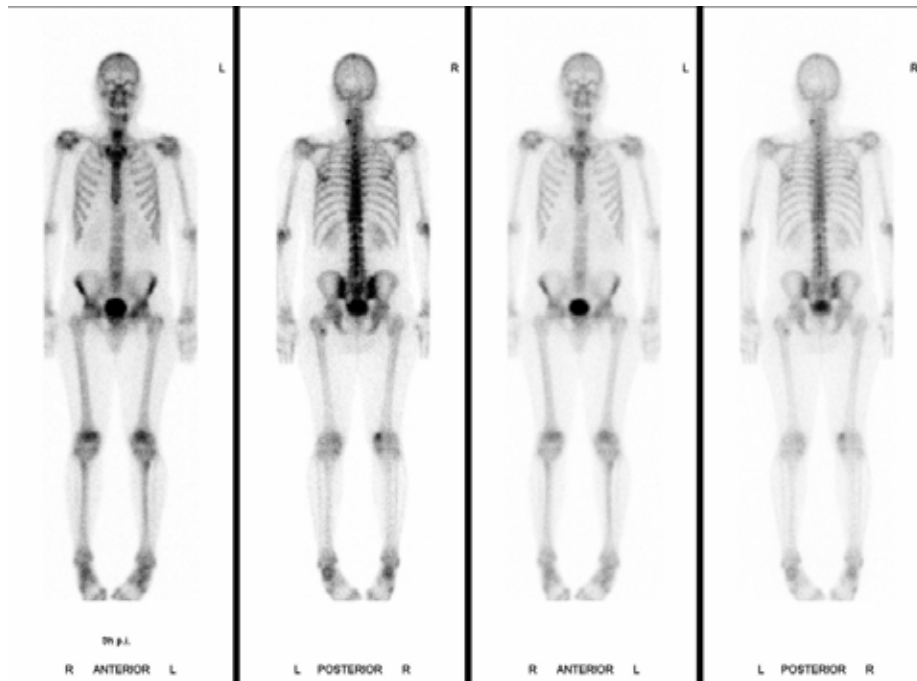
SPECT/CT (B): Shows significant focal uptake in a sclerotic lesion in the left trochanter minor (a, arrow), indicative for a bone metastasis. In addition, there is focal uptake at the trochanter major without a suspicious morphologic correlate (b, arrow), indicative for insertion tendinopathy.

The metastasis is retrospectively detectable (arrow, not reported in MR) on the prostate MRI (C, arrow).

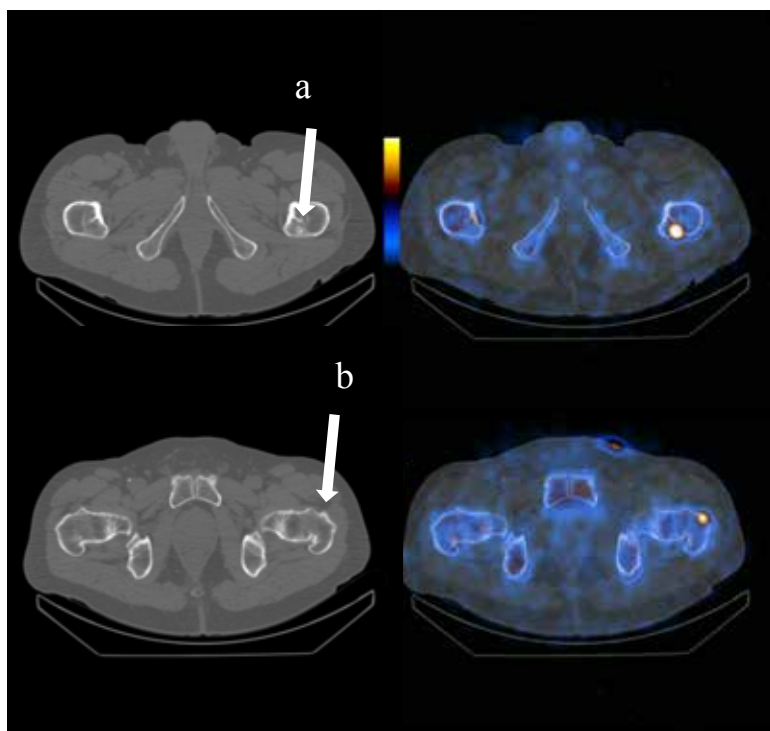
Outcome and teaching point

Resection of the primary tumour, extended adjuvant chemotherapy and radiotherapy of the bone metastases.

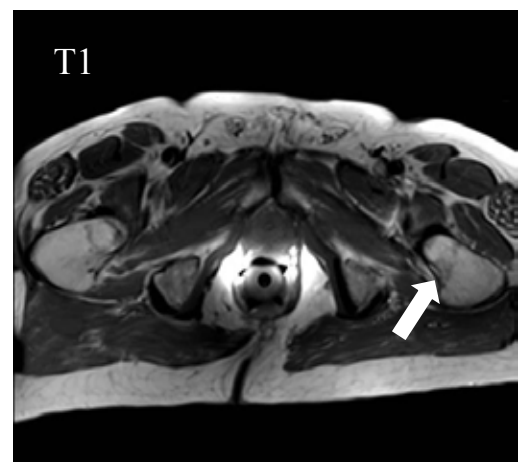
Note SPECT/CT is able to detect bone metastases partly overlooked in MRI.



(A)



(B)



(C)

10.10. CASE No. MD 10

Study type:	Oncology		
Clinical indication:	High grade prostate carcinoma Staging		
Keywords:	Bone metastasis Fracture		
SPECT/CT system:	General Electric Discovery 670	Tracer:	^{99m}Tc -DPD
Uptake:	180 min	Dose:	650 MBq
Tube loading:	120–400 mAs	Tube voltage:	120 kVp

Short clinical history

A 70 year old male patient with high grade prostate cancer (Gleason 9). The patient had transurethral resection of the prostate. There was no recent history of any significant trauma to the pelvis.

Findings

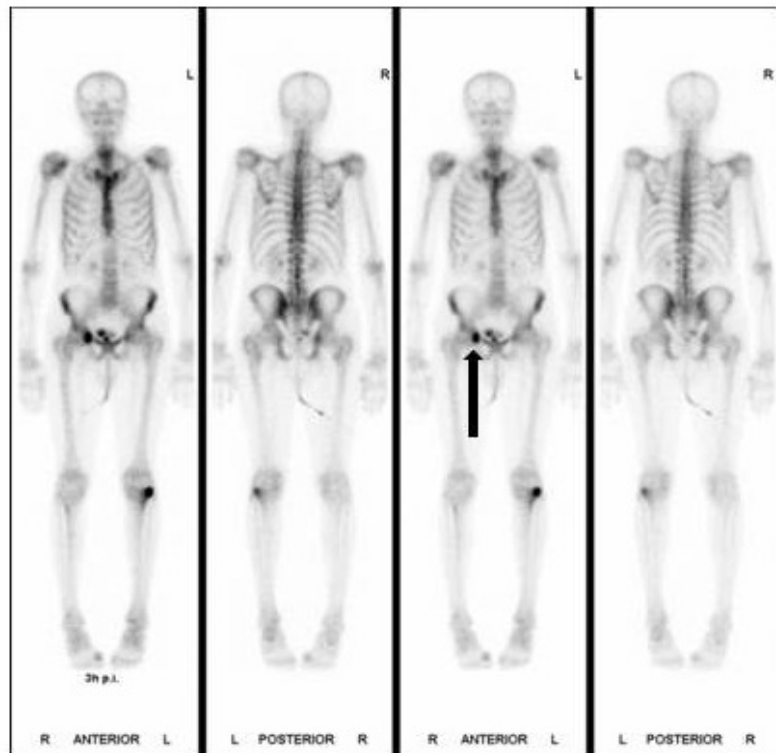
Planar bone scan (A): Shows focal uptake in the right superior pubic bone/anterior acetabulum (arrow) and degenerative uptake in the lateral compartment of the left knee.

SPECT/CT (B): Shows significant focal uptake in the right superior pubic bone/anterior acetabulum. On CT, there is a fracture line detectable as well as a partly sclerotic, partly lytic bone lesion — indicative of metastases with a pathological, non-dislocated fracture.

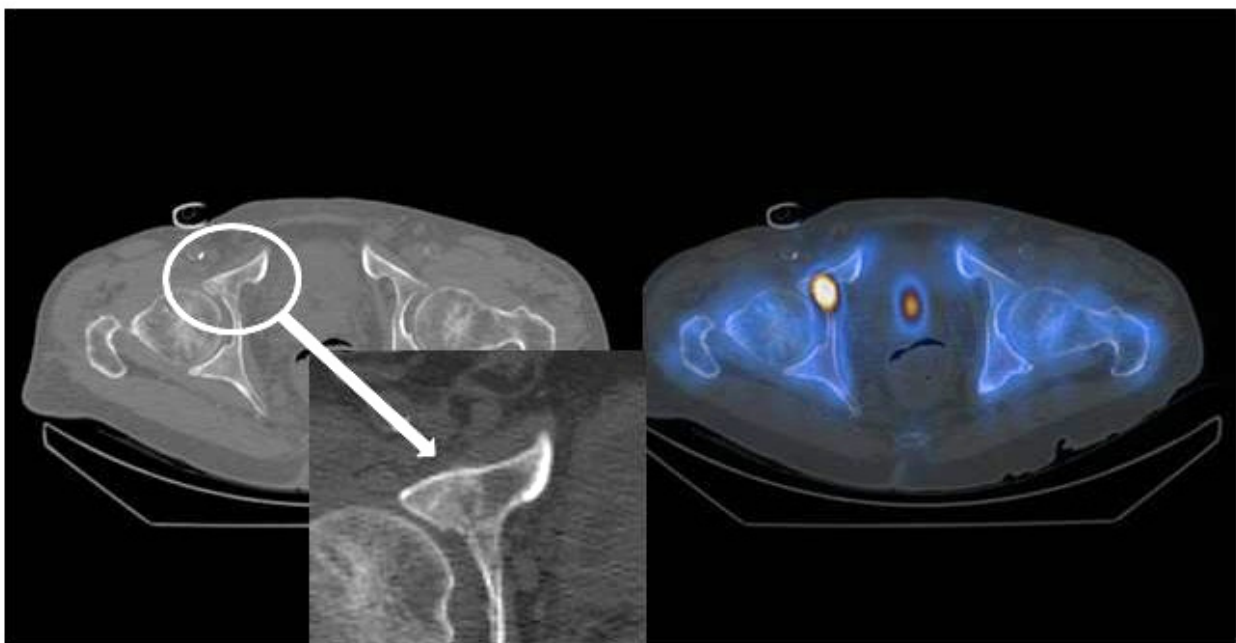
Outcome and teaching point

Staging CT thorax and abdomen during follow-up shows pathologic lymphadenopathy in the retroperitoneum. Conservative treatment of the non-dislocated fracture and consecutive hormonal therapy.

Note SPECT/CT was able to differentiate between a fracture and a pathologic fracture.



(A)



(B)

11. PAEDIATRICS

11.1. CASE No. PAED 1

Study type:	Oncology		
Clinical indication:	Leg pain Suspected relapse		
Keywords:	Langerhans cell histiocytosis Stress fracture		
SPECT/CT system:	Philips Precedence 16 slice	Tracer:	^{99m}Tc -HDP
Uptake:	180 min	Dose:	379 MBq
Tube loading:	18 mAs	Tube voltage:	140 kVp

Short clinical history

An 11 year old male patient with pain in the leg. The patient had been diagnosed with Langerhans cell histiocytosis in the sternum 2 years earlier and was treated with chemotherapy. Recurrence was suspected.

Findings

Planar bone scan done 2 years earlier (A): Shows focal uptake in the sternum (arrow).

Planar bone scan present (B): Shows focal uptake in the left distal fibula (arrow).

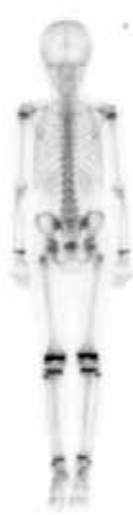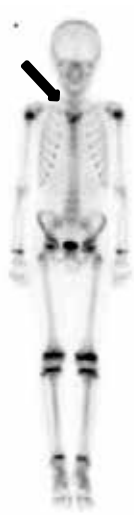SPECT/CT (C): Shows focal uptake in the left distal fibula with diffuse cortical thickening on CT, which could represent a stress fracture.

Outcome

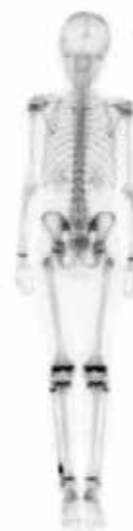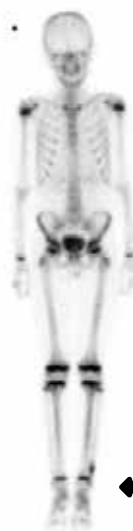Tumour relapse was ruled out and a stress fracture was diagnosed. MRI and CT were compatible with a stress fracture. The pain disappeared after not playing football for a few months.

Two years earlier

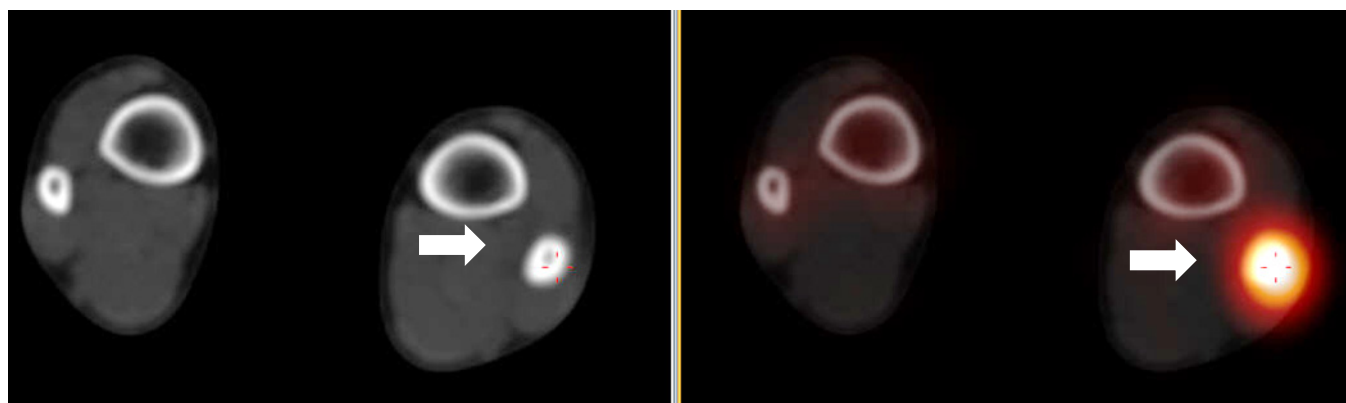
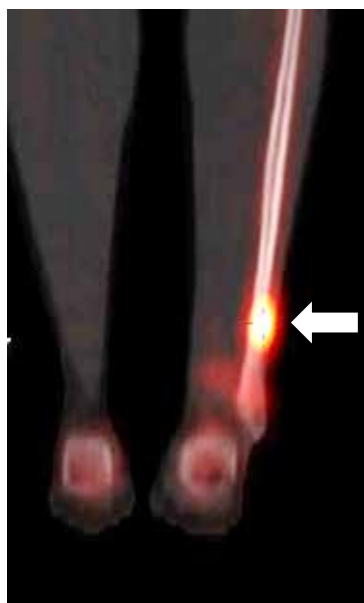Present



(A)



(B)



(C)

11.2. CASE No. PAED 2

Study type:	Traumatology		
Clinical indication:	Hip pain		
Keywords:	Arthritis Stress fracture Trauma		
SPECT/CT system:	Philips Precedence 16 slice	Tracer:	^{99m}Tc -HDP
Uptake:	180 min	Dose:	377 MBq
Tube loading:	15 mAs	Tube voltage:	140 kVp

Short clinical history

A 10 year old male patient with left-sided hip pain for 4 days. The patient had a slight fever. Suspected sacroiliitis.

Findings

X ray (A): Shows that hips were both negative (shown with scrotal lead protector and ultrasound; not shown).

Planar bone scan (B): Shows focal uptake in the left pubic bone in the ramus inferior.

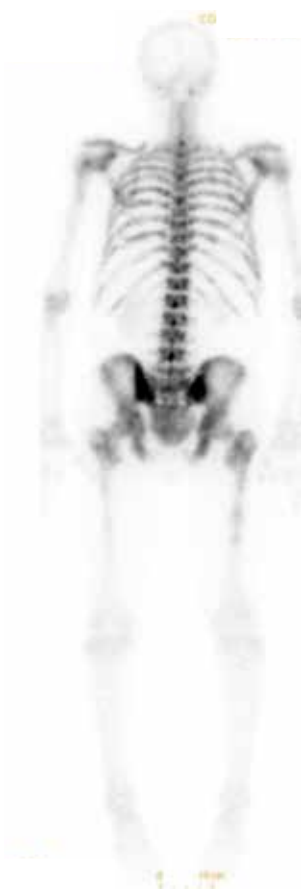SPECT/CT (C): Shows focal uptake located in the left ramus inferior and medial part of the superior pubic bones corresponding to a fracture seen on CT.

Outcome

The fracture was diagnosed by SPECT/CT, but had been overlooked on X ray with the lead protector. MRI was compatible with the fracture in the ramus inferior and incomplete fracture in the ramus superior. Owing to bacteraemia, antibiotics were given. The pain disappeared after not playing sport (football and handball) for a few months.



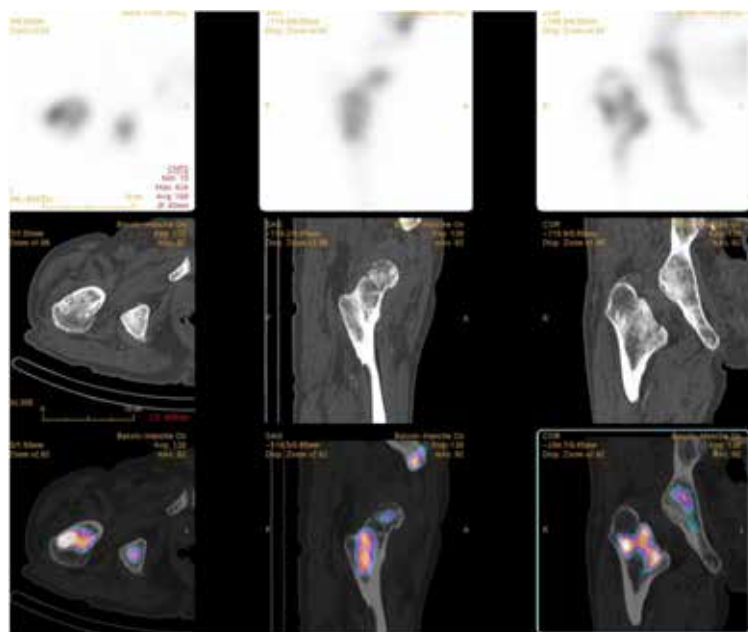
(A)



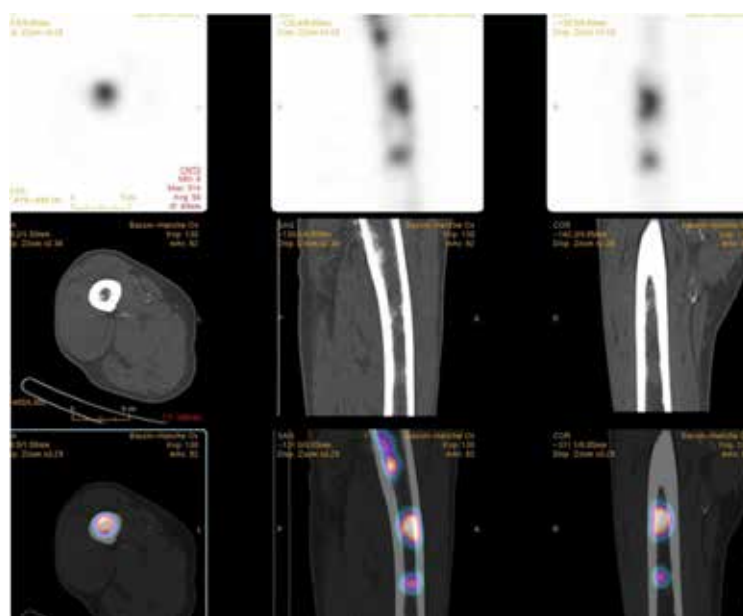
(B)



(C)



(D)



(E)

11.3. CASE No. PAED 3

Study type:	Infection Traumatology		
Clinical indication:	Pain in the right foot		
Keywords:	Osteomyelitis		
SPECT/CT system:	Philips Precedence 16 slice	Tracer:	^{99m}Tc -HDP
Uptake:	180 min	Dose:	282 MBq
Tube loading:	18 mAs	Tube voltage:	140 kVp

Short clinical history

An 18 month old female patient with pain in the right foot for 10 days. The patient could not stand. X ray and ultrasound of the foot were normal. There was no trauma. The patient had raised CRP. Suspected osteomyelitis.

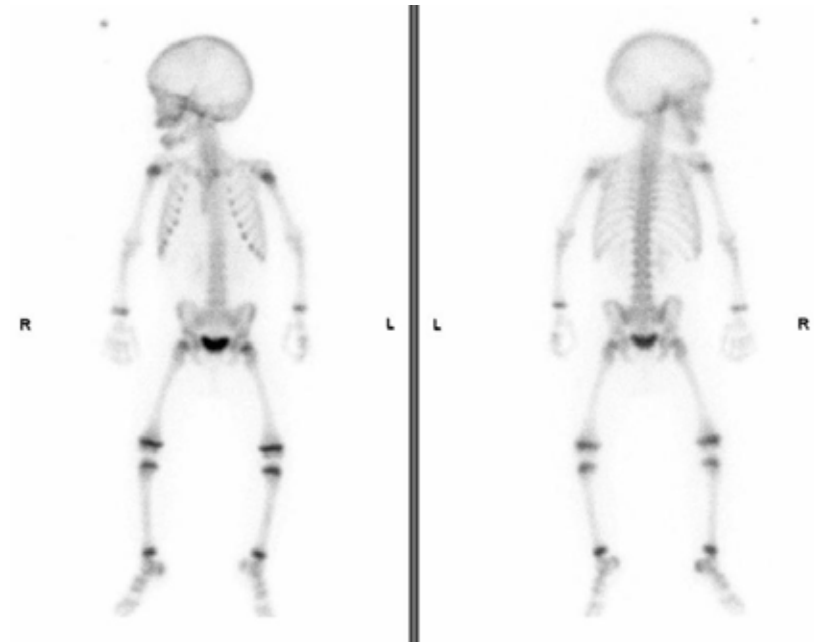
Findings

Planar bone scan (A): Shows a weak focus in the right calcaneus.

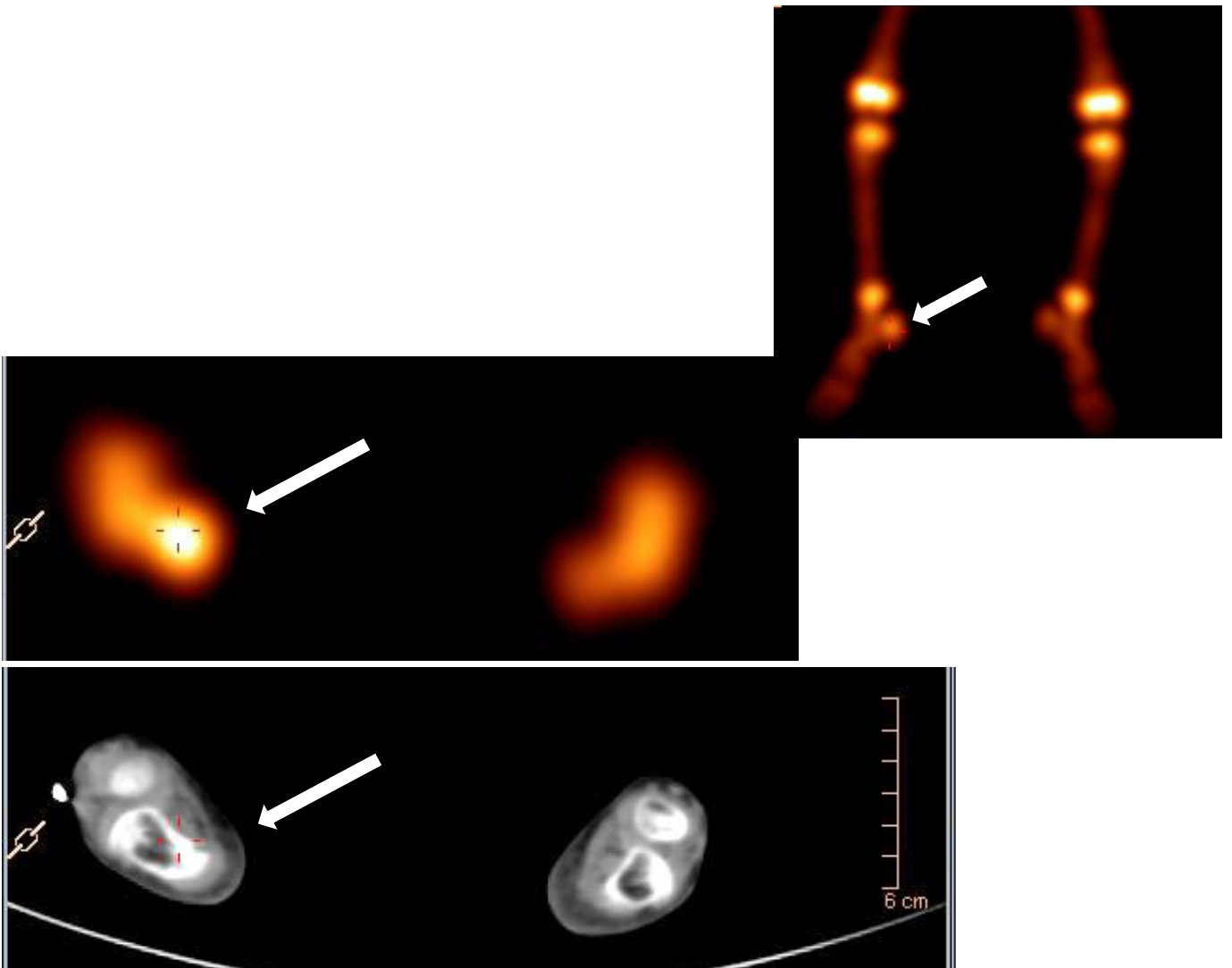
SPECT/CT (B): Shows focal uptake in the right calcaneus and a cortical defect on CT compatible with osteomyelitis.

Outcome

The patient was diagnosed with osteomyelitis and treated with antibiotics. The pain disappeared and CRP was normalized.



(A)



(B)

11.4. CASE No. PAED 4

Study type:	Oncology		
Clinical indication:	Leg pain Suspected tumour		
Keywords:	Osteomyelitis Langerhans cell histiocytosis		
SPECT/CT system:	Philips Precedence 16 slice	Tracer:	^{99m}Tc -HDP
Uptake:	180 min	Dose:	243 MBq
Tube loading:	17 mAs	Tube voltage:	140 kVp

Short clinical history

A 3 year old female patient with pain in the left leg for 1 month. MRI had shown what could be a tumour or osteomyelitis.

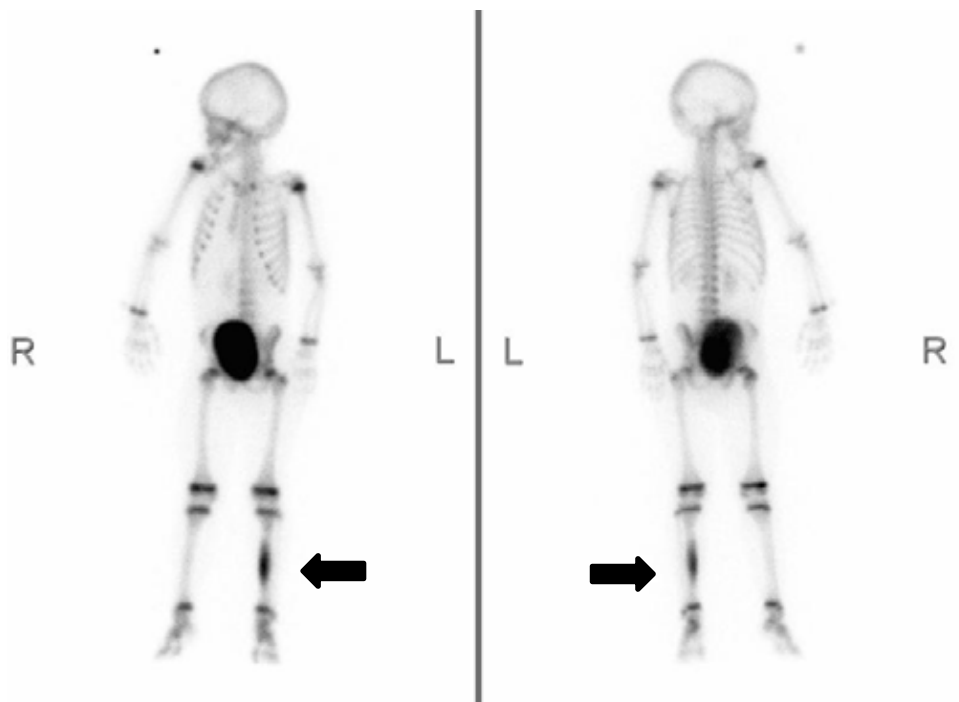
Findings

Planar bone scan (A): Shows focal uptake in the left tibia.

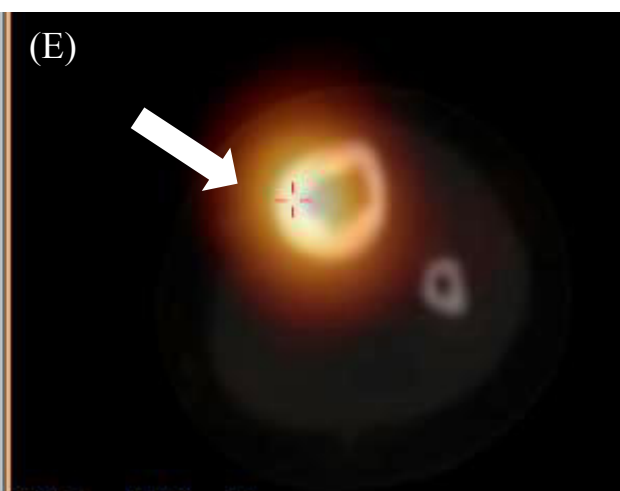
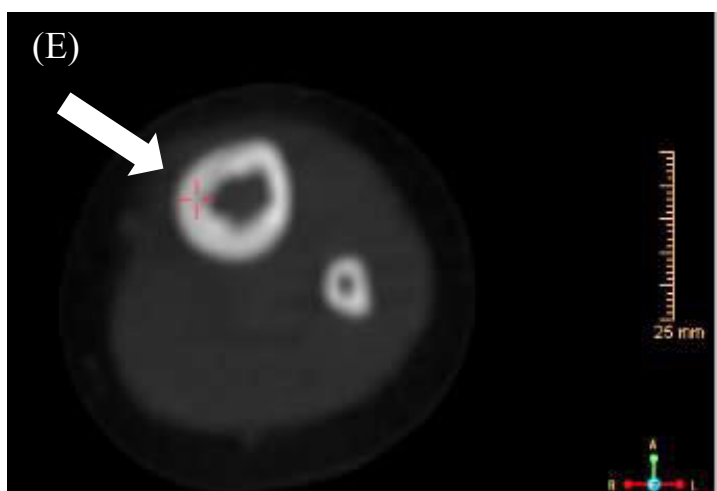

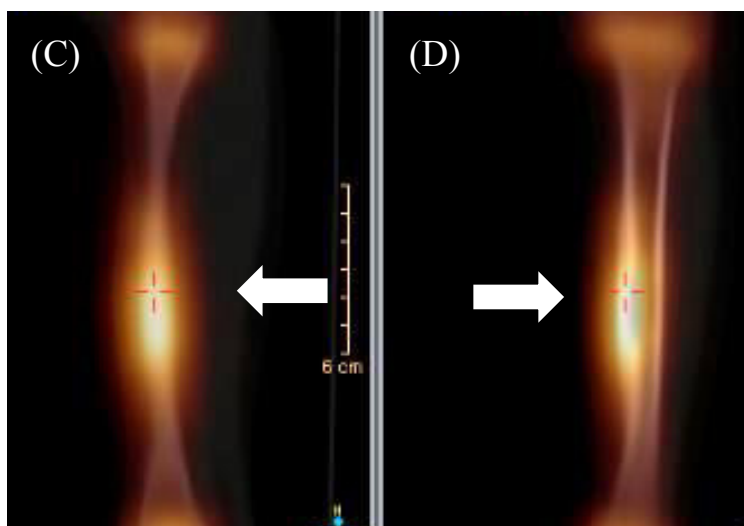
SPECT/CT (B): Shows increased focal uptake in the left tibia diaphysis corresponding to a sclerotic cortical process on CT compatible with both osteomyelitis and tumour (C: sagittal, D: coronal, E: axial slices).

Outcome

SPECT/CT showed unifocal lesions, so radical surgical treatment was given. Biopsy confirmed Langerhans cell histiocytosis and the tumour was resected.



(A)



(B)

11.5. CASE No. PAED 5

Study type:	Oncology		
Clinical indication:	Leg tumour Pre-operative, probe guided biopsy		
Keywords:	Fibrous dysplasia Tumour		
SPECT/CT system:	Philips Precedence 16 slice	Tracer:	^{99m}Tc -HDP
Uptake:	180 min	Dose:	316 MBq
Tube loading:	17 mAs	Tube voltage:	140 kVp

Short clinical history

A 6 year old female patient with pain in the left leg. The MRI suggested non-ossifying fibroma; however, the biopsy was inconclusive. Scintigraphy for pre-operative, probe guided re-biopsy was ordered.

Findings

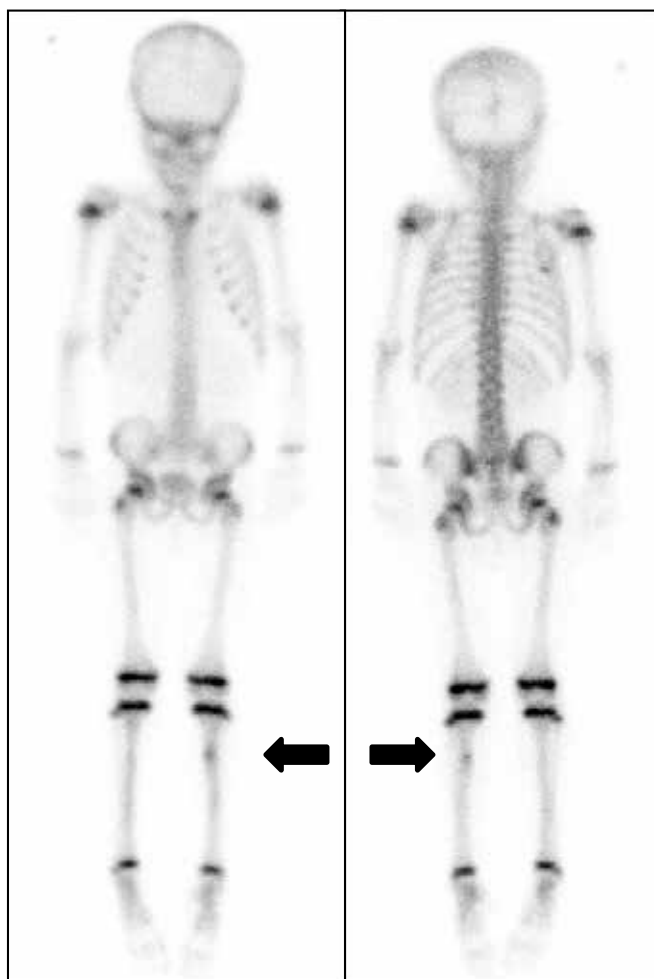
Planar bone scan (A): Shows focal uptake in the left tibia.

SPECT/CT (B): Shows increased and distinct focal uptake medially in the left tibia located 7.5 cm distal from the knee joint.

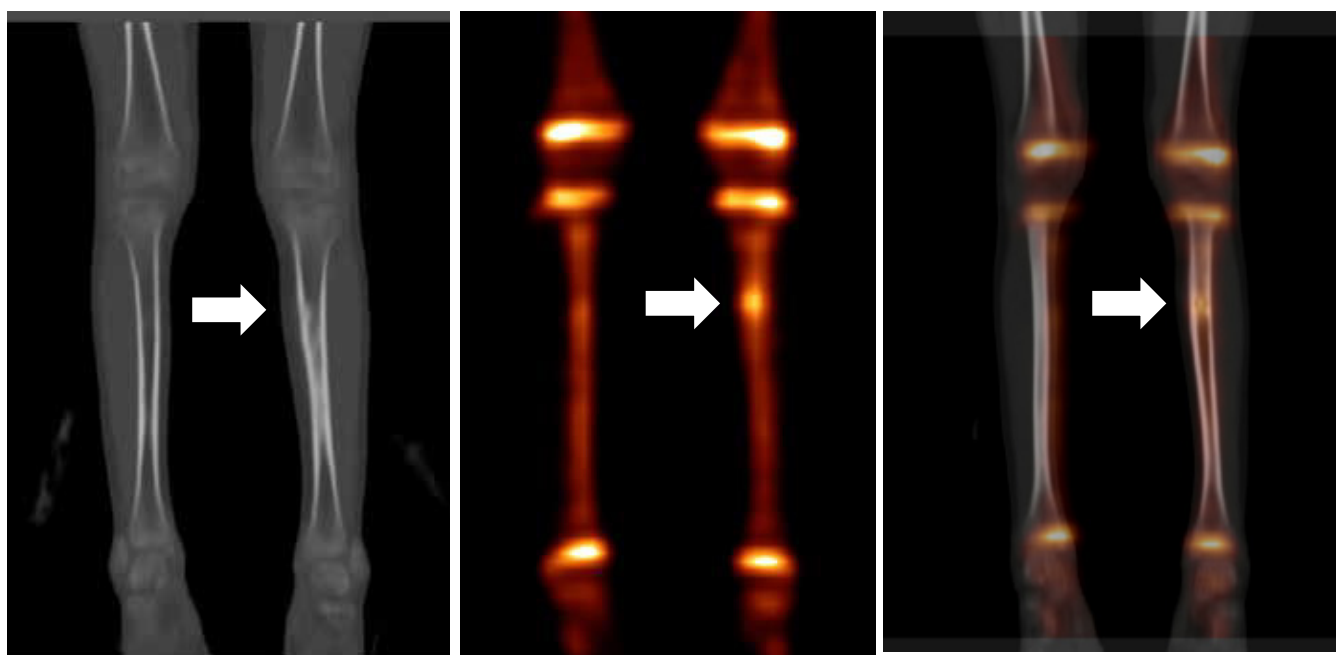
On CT there were corresponding osteolytic processes that can be seen in the area.

Outcome

SPECT/CT guided a successful re-biopsy and hence a diagnosis was obtained. Biopsy shows fibrous dysplasia. Pain had regressed at clinical follow-up.



(A)



(B)

11.6. CASE No. PAED 6

Study type:	Traumatology		
Clinical indication:	Pain in ankle		
Keywords:	Arthritis Degenerative changes Soft tissue calcification		
SPECT/CT system:	Philips Precedence 16 slice	Tracer:	^{99m}Tc -HDP
Uptake:	180 min	Dose:	364 MBq
Tube loading:	70 mAs	Tube voltage:	120 kVp

Short clinical history

A 9 year old male patient with an older trauma to the left ankle. At the time, the patient complained of continuous pain.

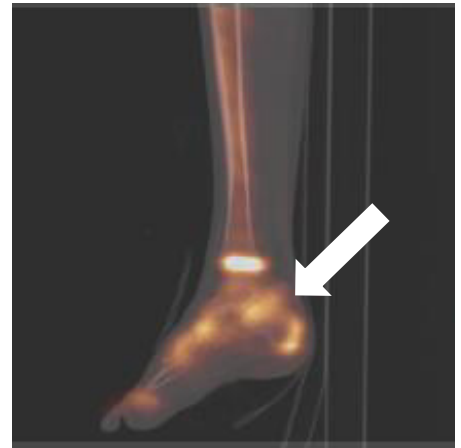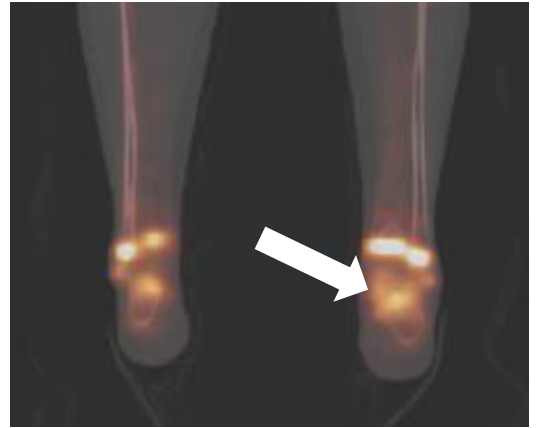
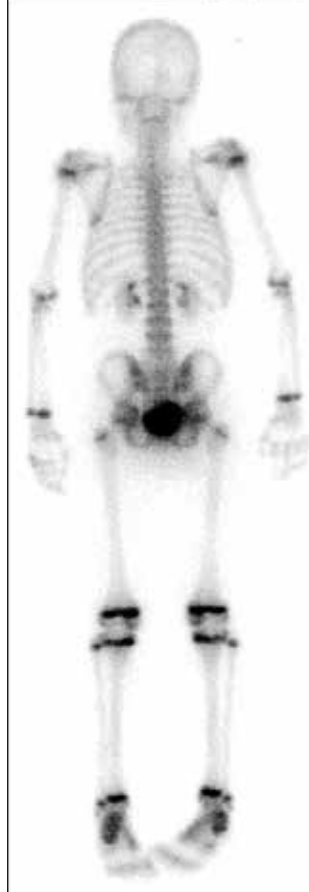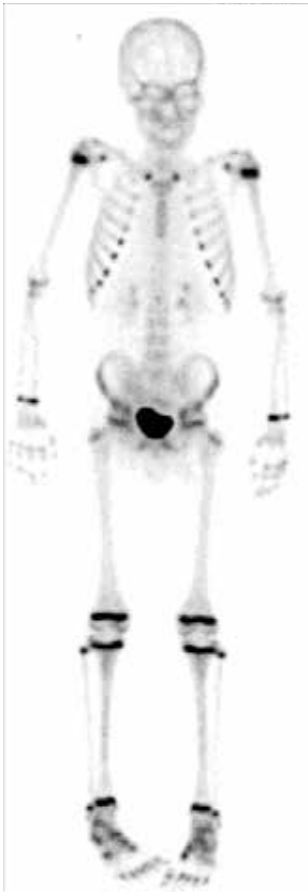Findings

Planar bone scan (A): Normal.

SPECT/CT (B): Shows increased activity in the left subtalar calcaneus joint, where CT also shows changes compatible with arthritis. In addition, a large, soft tissue calcification (without increased uptake) was found behind the calcaneus on the 3-D reconstruction of the CT (C).

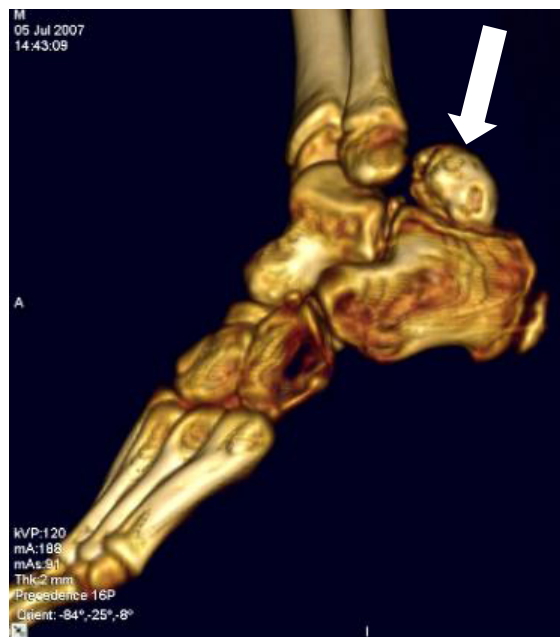Outcome

Based on the precise diagnosis of SPECT/CT, surgery was planned. The pain remained continuous, and subtalar arthrodesis and removal of calcification was planned for 1 year later.



(A)

(B)



(C)

11.7. CASE No. PAED 7

Study type:	Oncology		
Clinical indication:	Soft tissue swelling compatible with a tumour in the left zygomatic bone		
Keywords:	Langerhans cell histiocytosis		
SPECT/CT system:	Philips Precedence 16 slice	Tracer:	^{99m}Tc -HDP
Uptake:	150 min	Dose:	212 MBq
Tube loading:	13 mAs	Tube voltage:	140 kVp

Short clinical history

A 2 year old female patient with soft tissue swelling for 3 weeks. The symptoms are compatible with a tumour in the left zygomatic bone.

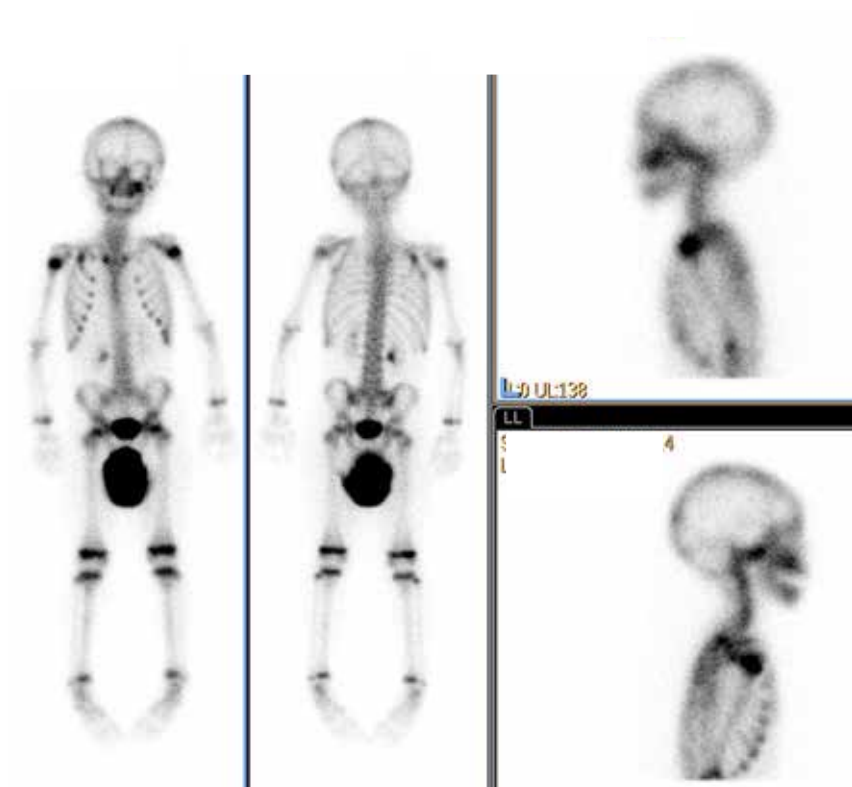
Findings

Planar bone scan (A): Shows increased uptake in the left zygomatic bone and the 2nd anterior right rib. Discrete foci also in the left temporal bone and the 6th anterior right rib.

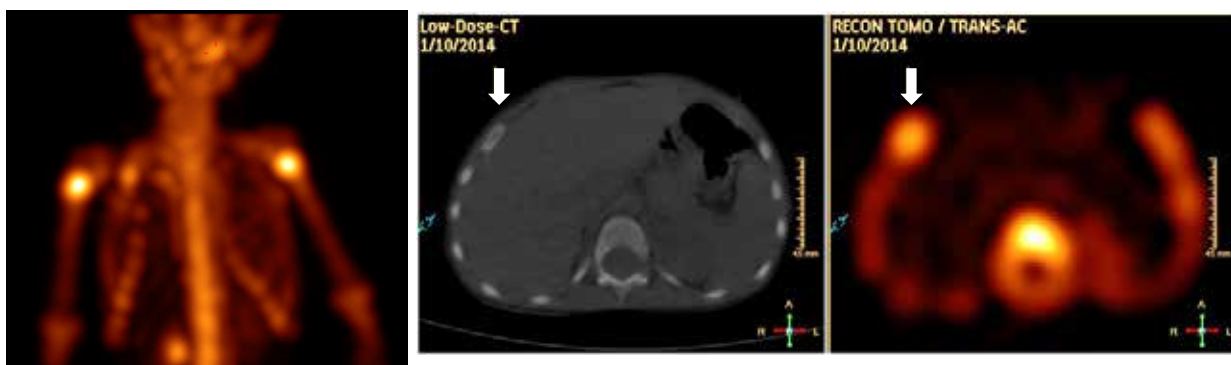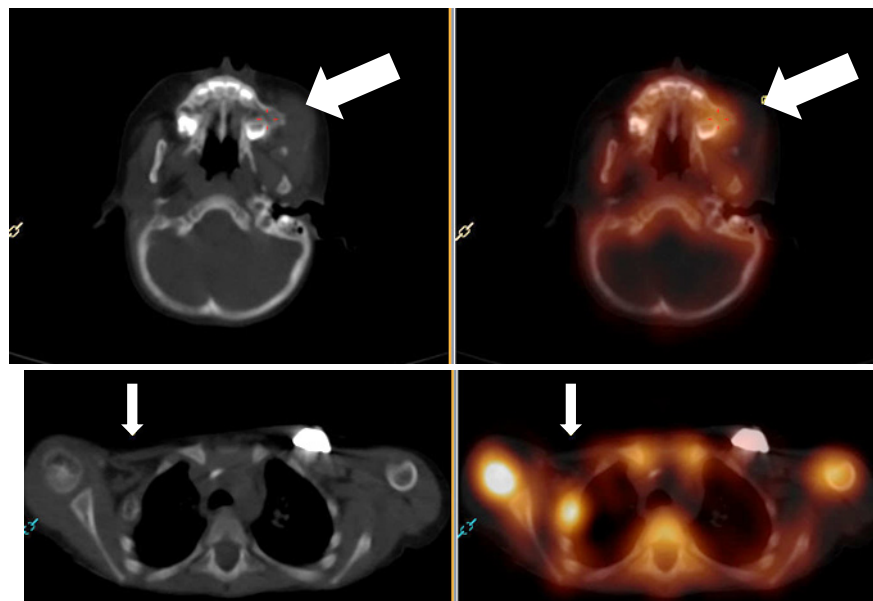
SPECT/CT (B): Shows increased activity in the four foci, where CT also shows changes compatible with a tumour with osteolytic bone lesions.

Outcome

SPECT/CT shows the precise location of extensive disease compatible with the histological diagnosis of Langerhans cell histiocytosis from biopsy of the cheek. Chemotherapy and prednisolone was administered with good clinical response after 3 months.



(A)



(B)

11.8. CASE No. PAED 8

Study type:	Oncology		
Clinical indication:	Suspected relapse of chronic osteomyelitis Suspected tumour		
Keywords:	CRMO Osteomyelitis Tumour		
SPECT/CT system:	Siemens Symbia 16 slice	Tracer:	^{99m}Tc -HDP
Uptake:	180 min	Dose:	426 MBq
Tube loading:	15 mAs	Tube voltage:	130 kVp

Short clinical history

A 14 year old female patient suspected for CRMO in the right femur with radiologic changes for 5 years. There were no positive bacterial findings ever found. Alternatively suspected for tumour.

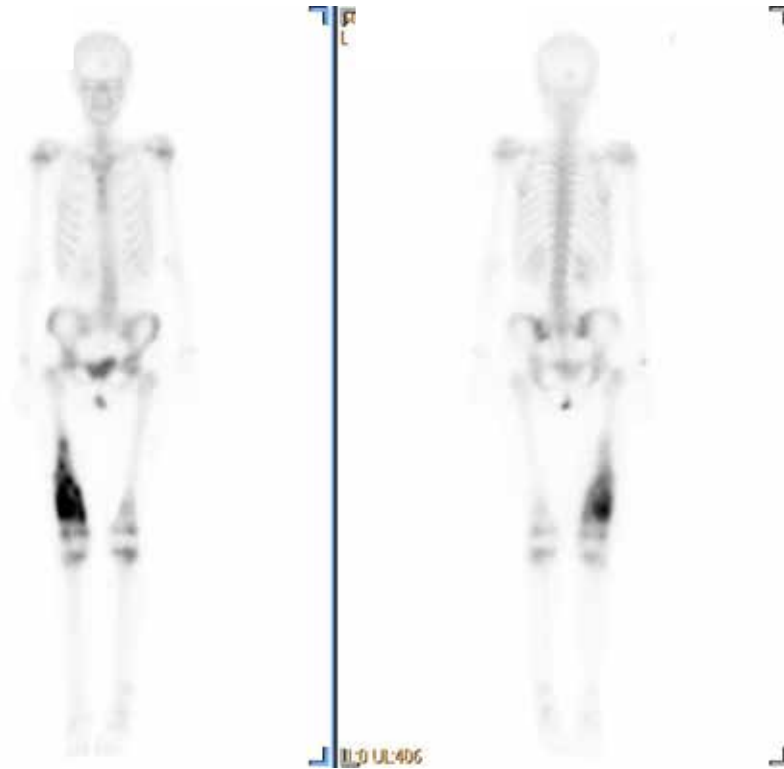
Findings

Planar bone scan (A): Shows intense uptake in the right femur and some increase in the foci in the distal left femur and proximally in both tibia.

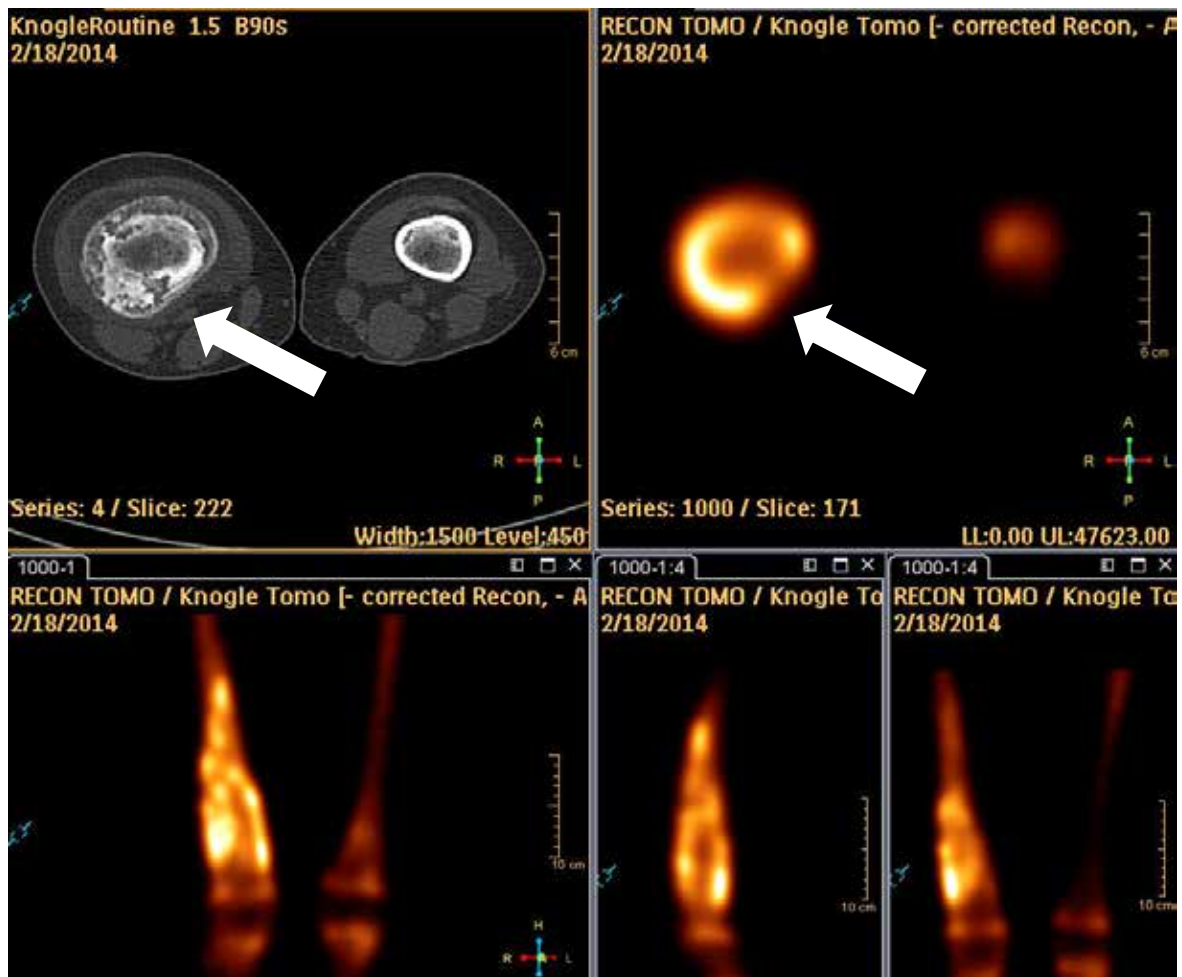
SPECT/CT (B): Shows increased activity in the same foci, where CT also shows mixed sclerotic and osteolytic changes in the bone structure compatible with CRMO.

Outcome

SPECT/CT shows more extensive disease and was compatible with CRMO, which also was in accordance with findings from MRI, bone biopsy and the clinical course. Prednisolone was administered with good clinical response after 3 months.



(A)



(B)

11.9. CASE No. PAED 9

Study type:	Infection		
Clinical indication:	Suspected relapse of chronic osteomyelitis Suspected tumour		
Keywords:	CRMO Osteomyelitis Tumour		
SPECT/CT system:	Siemens Symbia 16 slice	Tracer:	^{99m}Tc -HDP
Uptake:	135 min	Dose:	516 MBq
Tube loading:	13 mAs	Tube voltage:	130 kVp

Short clinical history

A 13 year old male patient and elite athlete, with ankle pain for a few months and relapsing fever after stopping antibiotics. The leucocyte scan was normal. The MRI shows some abnormal bone marrow signals, which do not correlate with discrete foci seen on the bone scan (A). A new bone scan was ordered owing to suspicion of osteomyelitis, CRMO or malignancy.

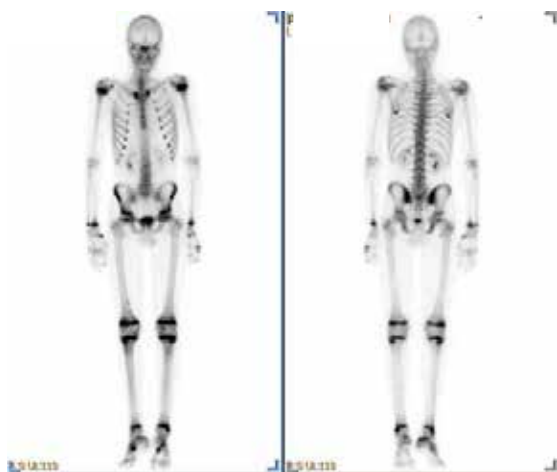Findings

Planar bone scan (A): Shows a new focus with increased uptake in the proximal right tibia and normalization of earlier foci.

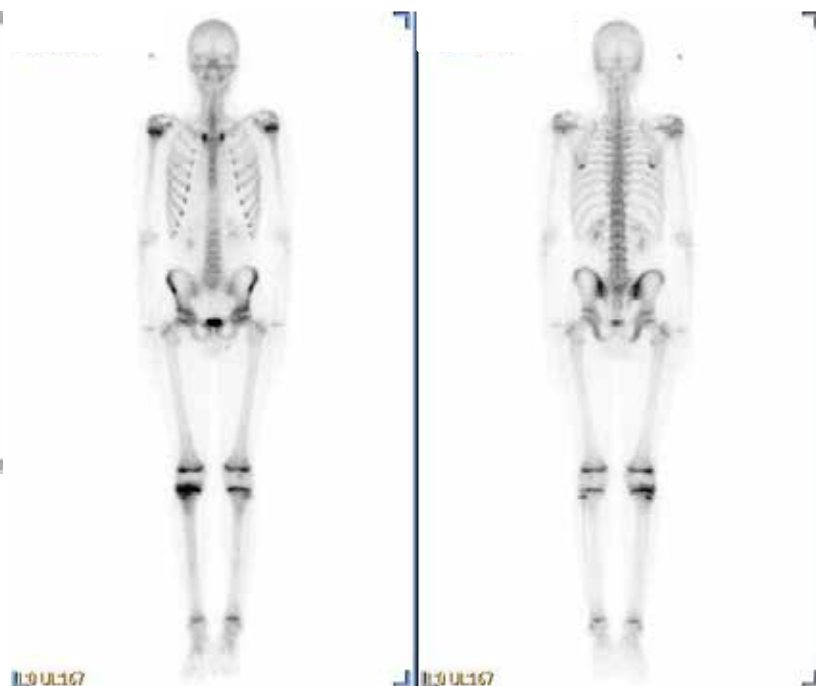
SPECT/CT (B): Shows increased activity in the same area without any CT abnormality.

Outcome

The changing pattern on bone SPECT/CT which correlates with findings on a repeated MRI and the clinical course, were all compatible with CRMO. The possibility for medical treatment was discussed.

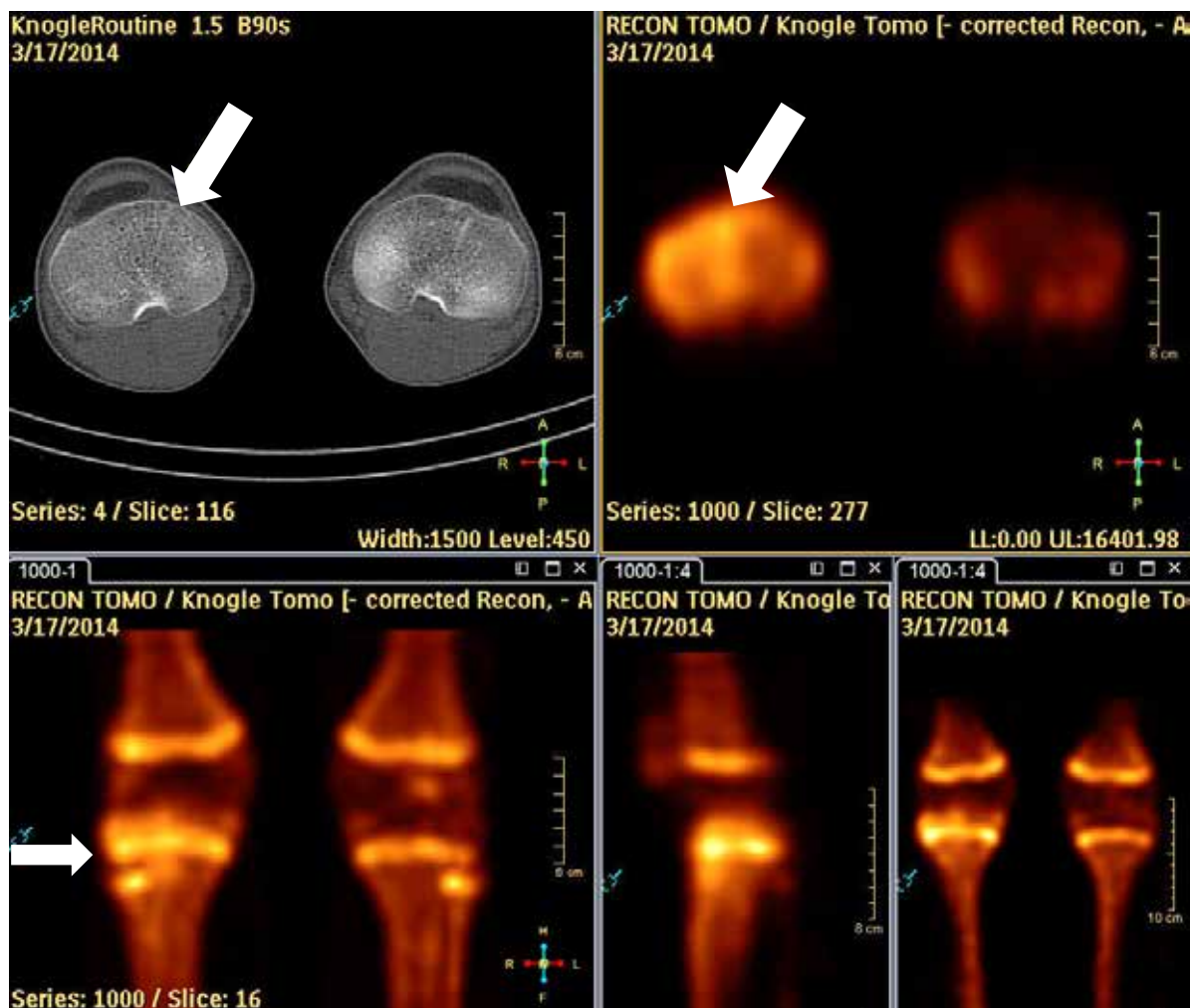


Three months earlier



(A)

Present



(B)

11.10. CASE No. PAED 10

Study type:	Infection Traumatology		
Clinical indication:	Suspected osteomyelitis Suspected fracture Suspected tumour		
Keywords:	Arthritis Fracture Inflammation Osteomyelitis		
SPECT/CT system:	Siemens Symbia 16 slice	Tracer:	^{99m} Tc-HDP
Uptake:	165 min	Dose:	444 MBq
Tube loading:	12 mAs	Tube voltage:	130 kVp

Short clinical history

A 10 year old male patient with pain in the left heel for a few months. MRI shows map like oedema in several bones of the left foot. Suspected stress fracture, osteomyelitis or tumour.

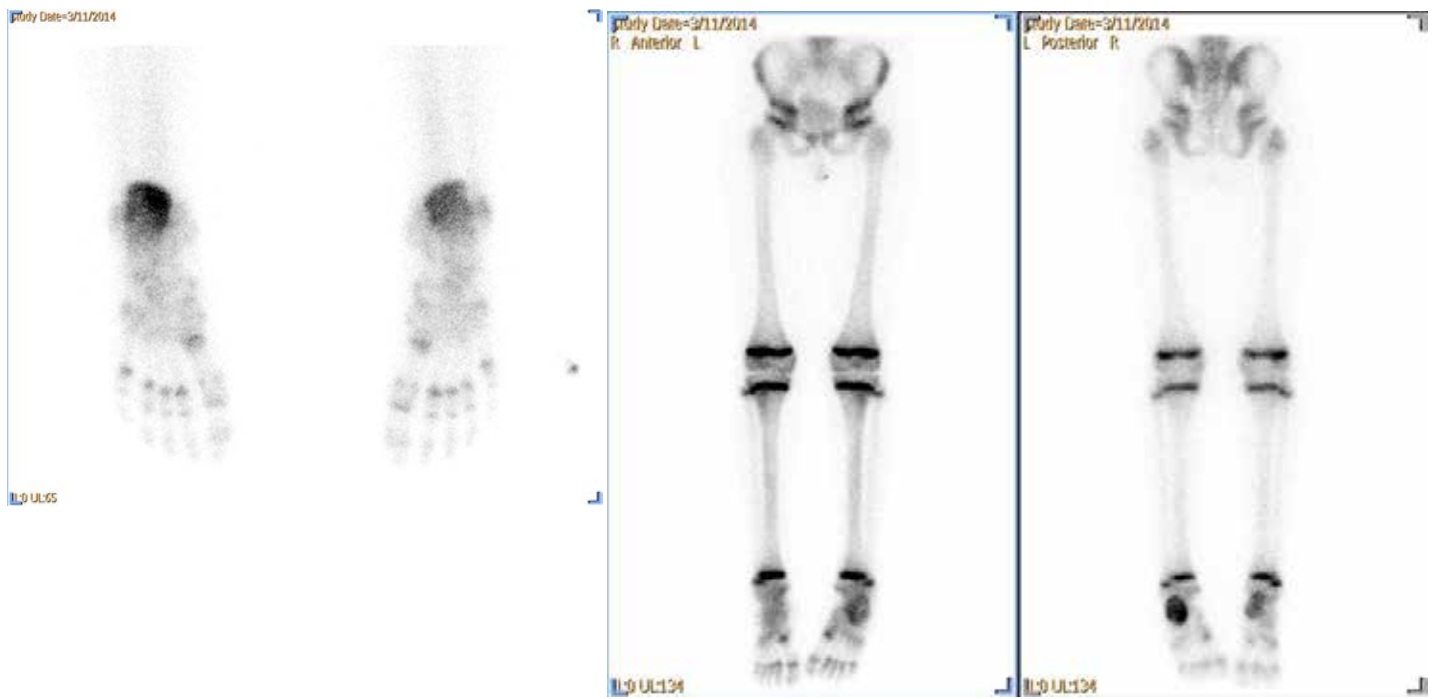Findings

Planar bone scan (A): Shows intense uptake in the left calcaneus.

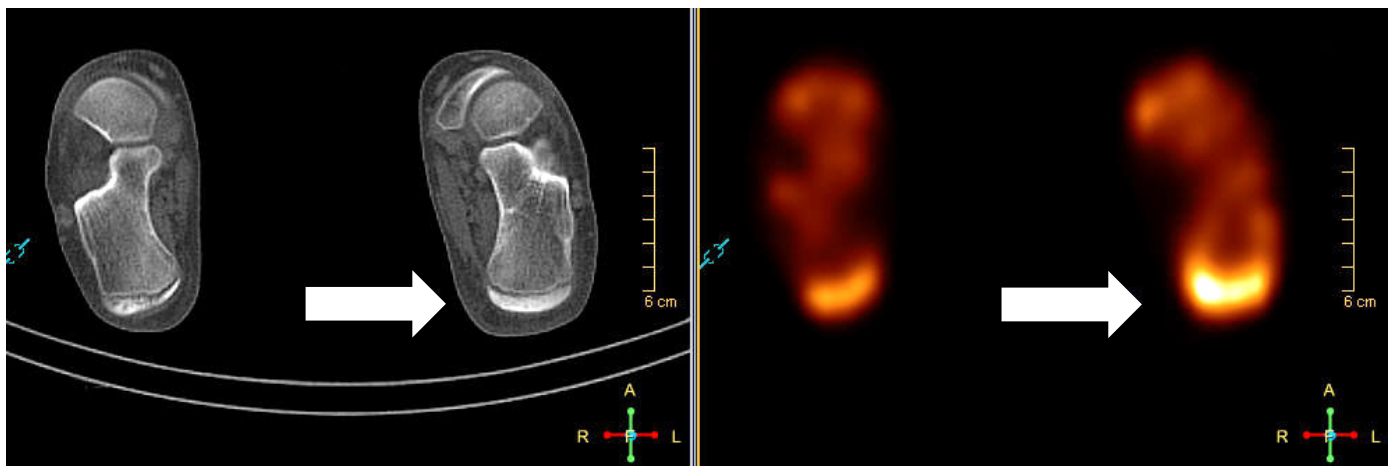
SPECT/CT (B): Shows increased bone uptake in the peripheral posterior left calcaneus (arrow), while CT shows normal findings suggesting inflammation. Malignancy and stress fracture were excluded, and osteomyelitis is less likely.

Outcome

SPECT/CT and a new MRI were compatible with a clinical diagnosis of enthesitis related arthritis. Methotrexate was initiated.



(A)



(B)

ABBREVIATIONS

CMC	carpometacarpal
CRMO	chronic recurrent multifocal osteomyelitis
CRP	C-reactive protein
CT	computed tomography
DPD	dicarboxypropane diphosphonate
DRUJ	distal radioulnar joint
HDP	hydroxymethane diphosphonate
ISJ	sacroiliac joint
kVp	kilovoltage peak
mAs	milliamperere seconds
MBq	megabecquerel
min	minute
MIP	maximum intensity projection
MR	magnetic resonance
MRI	magnetic resonance imaging
PET	positron emission tomography
PSA	prostate-specific antigen
s/p	status post
SPECT	single photon emission computed tomography
TFCC	triangular fibrocartilage complex
THA	total hip arthroplasty
TMC	trapeziometacarpal

CONTRIBUTORS TO DRAFTING AND REVIEW

El-Haj, N.	International Atomic Energy Agency
Estrada Lobato, E.	International Atomic Energy Agency
Freudenberg, L.S.	University of Duisburg-Essen, Germany
Hustinx, R.	Centre Hospitalier Universitaire de Liège, Belgium
Mortensen, J.	University Hospital of Copenhagen, Denmark
Núñez Miller, R.	International Atomic Energy Agency
Paez, D.	International Atomic Energy Agency
Veit-Haibach, P.	University Hospital Zurich, Switzerland



IAEA

International Atomic Energy Agency

No. 24

ORDERING LOCALLY

In the following countries, IAEA priced publications may be purchased from the sources listed below or from major local booksellers.

Orders for unpriced publications should be made directly to the IAEA. The contact details are given at the end of this list.

BELGIUM

Jean de Lannoy

Avenue du Roi 202, 1190 Brussels, BELGIUM

Telephone: +32 2 5384 308 • Fax: +32 2 5380 841

Email: jean.de.lannoy@euronet.be • Web site: <http://www.jean-de-lannoy.be>

CANADA

Renouf Publishing Co. Ltd.

22-1010 Polytek Street, Ottawa, ON K1J 9J1, CANADA

Telephone: +1 613 745 2665 • Fax: +1 643 745 7660

Email: order@renoufbooks.com • Web site: <http://www.renoufbooks.com>

Bernan Associates

4501 Forbes Blvd., Suite 200, Lanham, MD 20706-4391, USA

Telephone: +1 800 865 3457 • Fax: +1 800 865 3450

Email: orders@bernann.com • Web site: <http://www.bernann.com>

CZECH REPUBLIC

Suweco CZ, s.r.o.

SESTUPNÁ 153/11, 162 00 Prague 6, CZECH REPUBLIC

Telephone: +420 242 459 205 • Fax: +420 284 821 646

Email: nakup@suweco.cz • Web site: <http://www.suweco.cz>

FRANCE

Form-Edit

5 rue Janssen, PO Box 25, 75921 Paris CEDEX, FRANCE

Telephone: +33 1 42 01 49 49 • Fax: +33 1 42 01 90 90

Email: fabien.boucard@formedit.fr • Web site: <http://www.formedit.fr>

Lavoisier SAS

14 rue de Provigny, 94236 Cachan CEDEX, FRANCE

Telephone: +33 1 47 40 67 00 • Fax: +33 1 47 40 67 02

Email: livres@lavoisier.fr • Web site: <http://www.lavoisier.fr>

L'Appel du livre

99 rue de Charonne, 75011 Paris, FRANCE

Telephone: +33 1 43 07 43 43 • Fax: +33 1 43 07 50 80

Email: livres@appeldulivre.fr • Web site: <http://www.appeldulivre.fr>

GERMANY

Goethe Buchhandlung Teubig GmbH

Schweitzer Fachinformationen

Willstätterstrasse 15, 40549 Düsseldorf, GERMANY

Telephone: +49 (0) 211 49 874 015 • Fax: +49 (0) 211 49 874 28

Email: kundenbetreuung.goethe@schweitzer-online.de • Web site: <http://www.goethebuch.de>

HUNGARY

Librotrade Ltd., Book Import

Pesti út 237. 1173 Budapest, HUNGARY

Telephone: +36 1 254-0-269 • Fax: +36 1 254-0-274

Email: books@librotrade.hu • Web site: <http://www.librotrade.hu>

INDIA

Allied Publishers

1st Floor, Dubash House, 15, J.N. Heredi Marg, Ballard Estate, Mumbai 400001, INDIA

Telephone: +91 22 4212 6930/31/69 • Fax: +91 22 2261 7928

Email: alliedpl@vsnl.com • Web site: <http://www.alliedpublishers.com>

Bookwell

3/79 Nirankari, Delhi 110009, INDIA

Telephone: +91 11 2760 1283/4536

Email: bkwell@nde.vsnl.net.in • Web site: <http://www.bookwellindia.com>

ITALY***Libreria Scientifica "AEIOU"***

Via Vincenzo Maria Coronelli 6, 20146 Milan, ITALY

Telephone: +39 02 48 95 45 52 • Fax: +39 02 48 95 45 48

Email: info@libreriaaeiou.eu • Web site: <http://www.libreriaaeiou.eu>

JAPAN***Maruzen-Yushodo Co., Ltd.***

10-10, Yotsuyasakamachi, Shinjuku-ku, Tokyo 160-0002, JAPAN

Telephone: +81 3 4335 9312 • Fax: +81 3 4335 9364

Email: bookimport@maruzen.co.jp • Web site: <http://maruzen.co.jp>

RUSSIAN FEDERATION***Scientific and Engineering Centre for Nuclear and Radiation Safety***

107140, Moscow, Malaya Krasnoselskaya st. 2/8, bld. 5, RUSSIAN FEDERATION

Telephone: +7 499 264 00 03 • Fax: +7 499 264 28 59

Email: secnrs@secnrs.ru • Web site: <http://www.secnrs.ru>

UNITED STATES OF AMERICA***Bernan Associates***

4501 Forbes Blvd., Suite 200, Lanham, MD 20706-4391, USA

Telephone: +1 800 865 3457 • Fax: +1 800 865 3450

Email: orders@bernan.com • Web site: <http://www.bernan.com>

Renouf Publishing Co. Ltd.

812 Proctor Avenue, Ogdensburg, NY 13669-2205, USA

Telephone: +1 888 551 7470 • Fax: +1 888 551 7471

Email: orders@renoufbooks.com • Web site: <http://www.renoufbooks.com>

Orders for both priced and unpriced publications may be addressed directly to:

IAEA Publishing Section, Marketing and Sales Unit

International Atomic Energy Agency

Vienna International Centre, PO Box 100, 1400 Vienna, Austria

Telephone: +43 1 2600 22529 or 22530 • Fax: +43 1 2600 29302

Email: sales.publications@iaea.org • Web site: <http://www.iaea.org/books>

QUALITY ASSURANCE FOR PET AND PET/CT SYSTEMS**IAEA Human Health Series No. 1**

STI/PUB/1393 (145 pp.; 2009)

ISBN 978-92-0-103609-4

Price: €32.00

PLANNING A CLINICAL PET CENTRE**IAEA Human Health Series No. 11**

STI/PUB/1457 (146 pp.; 2010)

ISBN 978-92-0-104610-9

Price: €42.00

**STANDARD OPERATING PROCEDURES FOR PET/CT: A PRACTICAL APPROACH
FOR USE IN ADULT ONCOLOGY****IAEA Human Health Series No. 26**

STI/PUB/1616 (116 pp.; 2013)

ISBN 978-92-0-143710-5

Price: €35.00

**QUANTITATIVE NUCLEAR MEDICINE IMAGING: CONCEPTS, REQUIREMENTS
AND METHODS****IAEA Human Health Reports No. 9**

STI/PUB/1605 (59 pp.; 2014)

ISBN 978-92-0-141510-3

Price: €33.00

CLINICAL PET/CT ATLAS: A CASEBOOK OF IMAGING ONCOLOGY**IAEA Human Health Series No. 32**

STI/PUB/1680 (201 pp.; 2015)

ISBN 978-92-0-101115-2

Price: €70.00

The atlas focuses specifically on single photon emission computed tomography/computed tomography (SPECT/CT) in musculoskeletal imaging, and thus illustrates the inherent advantages of the combination of the metabolic and anatomical components in a single procedure. In addition, the atlas provides information on the usefulness of several sets of specific indications. The publication, which serves more as a training tool rather than a textbook, will help to further integrate the SPECT and CT experience in clinical practice by presenting a series of typical cases with many different patterns of SPECT/CT seen in bone scintigraphy.

IAEA HUMAN HEALTH SERIES

INTERNATIONAL ATOMIC ENERGY AGENCY
VIENNA
ISBN 978-92-0-103416-8
ISSN 2075-3772