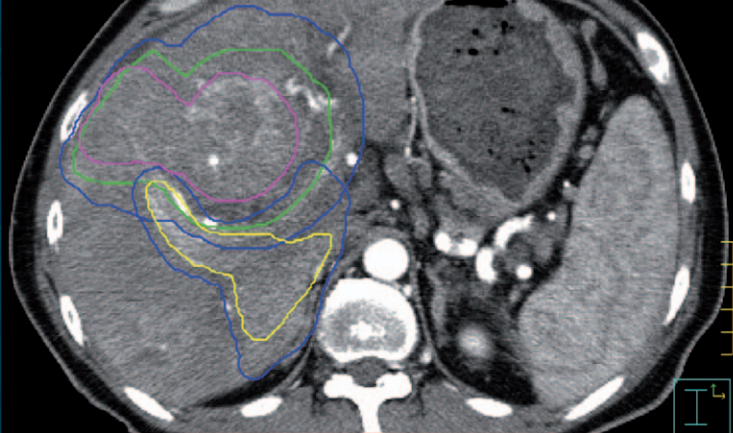

IAEA HUMAN HEALTH SERIES

No. 10

Trends and Practices in Diagnosis and Treatment of Hepatocellular Carcinoma



IAEA

International Atomic Energy Agency

IAEA HUMAN HEALTH SERIES PUBLICATIONS

The mandate of the IAEA human health programme originates from Article II of its Statute, which states that the “Agency shall seek to accelerate and enlarge the contribution of atomic energy to peace, health and prosperity throughout the world”. The main objective of the human health programme is to enhance the capabilities of IAEA Member States in addressing issues related to the prevention, diagnosis and treatment of health problems through the development and application of nuclear techniques, within a framework of quality assurance.

Publications in the IAEA Human Health Series provide information in the areas of: radiation medicine, including diagnostic radiology, diagnostic and therapeutic nuclear medicine, and radiation therapy; dosimetry and medical radiation physics; and stable isotope techniques and other nuclear applications in nutrition. The publications have a broad readership and are aimed at medical practitioners, researchers and other professionals. International experts assist the IAEA Secretariat in drafting and reviewing these publications. Some of the publications in this series may also be endorsed or co-sponsored by international organizations and professional societies active in the relevant fields.

There are two categories of publications in this series:

IAEA HUMAN HEALTH SERIES

Publications in this category present analyses or provide information of an advisory nature, for example guidelines, codes and standards of practice, and quality assurance manuals. Monographs and high level educational material, such as graduate texts, are also published in this series.

IAEA HUMAN HEALTH REPORTS

Human Health Reports complement information published in the IAEA Human Health Series in areas of radiation medicine, dosimetry and medical radiation physics, and nutrition. These publications include reports of technical meetings, the results of IAEA coordinated research projects, interim reports on IAEA projects, and educational material compiled for IAEA training courses dealing with human health related subjects. In some cases, these reports may provide supporting material relating to publications issued in the IAEA Human Health Series.

All of these publications can be downloaded cost free from the IAEA web site:

<http://www.iaea.org/Publications/index.html>

Further information is available from:

Marketing and Sales Unit
International Atomic Energy Agency
Vienna International Centre
PO Box 100
1400 Vienna, Austria

Readers are invited to provide their impressions on these publications. Information may be provided via the IAEA web site, by mail at the address given above, or by email to:

Official.Mail@iaea.org.

TRENDS AND PRACTICES IN
DIAGNOSIS AND TREATMENT OF
HEPATOCELLULAR CARCINOMA

The following States are Members of the International Atomic Energy Agency:

AFGHANISTAN	GHANA	NORWAY
ALBANIA	GREECE	OMAN
ALGERIA	GUATEMALA	PAKISTAN
ANGOLA	HAITI	PALAU
ARGENTINA	HOLY SEE	PANAMA
ARMENIA	HONDURAS	PARAGUAY
AUSTRALIA	HUNGARY	PERU
AUSTRIA	ICELAND	PHILIPPINES
AZERBAIJAN	INDIA	POLAND
BAHRAIN	INDONESIA	PORTUGAL
BANGLADESH	IRAN, ISLAMIC REPUBLIC OF	QATAR
BELARUS	IRAQ	REPUBLIC OF MOLDOVA
BELGIUM	IRELAND	ROMANIA
BELIZE	ISRAEL	RUSSIAN FEDERATION
BENIN	ITALY	SAUDI ARABIA
BOLIVIA	JAMAICA	SENEGAL
BOSNIA AND HERZEGOVINA	JAPAN	SERBIA
BOTSWANA	JORDAN	SEYCHELLES
BRAZIL	KAZAKHSTAN	SIERRA LEONE
BULGARIA	KENYA	SINGAPORE
BURKINA FASO	KOREA, REPUBLIC OF	SLOVAKIA
BURUNDI	KUWAIT	SLOVENIA
CAMBODIA	KYRGYZSTAN	SOUTH AFRICA
CAMEROON	LATVIA	SPAIN
CANADA	LEBANON	SRI LANKA
CENTRAL AFRICAN REPUBLIC	LESOTHO	SUDAN
CHAD	LIBERIA	SWEDEN
CHILE	LIBYAN ARAB JAMAHIRIYA	SWITZERLAND
CHINA	LIECHTENSTEIN	SYRIAN ARAB REPUBLIC
COLOMBIA	LITHUANIA	TAJIKISTAN
CONGO	LUXEMBOURG	THAILAND
COSTA RICA	MADAGASCAR	THE FORMER YUGOSLAV REPUBLIC OF MACEDONIA
CÔTE D'IVOIRE	MALAWI	TUNISIA
CROATIA	MALAYSIA	TURKEY
CUBA	MALI	UGANDA
CYPRUS	MALTA	UKRAINE
CZECH REPUBLIC	MARSHALL ISLANDS	UNITED ARAB EMIRATES
DEMOCRATIC REPUBLIC OF THE CONGO	MAURITANIA	UNITED KINGDOM OF GREAT BRITAIN AND NORTHERN IRELAND
DENMARK	MAURITIUS	UNITED REPUBLIC OF TANZANIA
DOMINICAN REPUBLIC	MEXICO	UNITED STATES OF AMERICA
ECUADOR	MONACO	URUGUAY
EGYPT	MONGOLIA	UZBEKISTAN
EL SALVADOR	MONTENEGRO	VENEZUELA
ERITREA	MOROCCO	VIETNAM
ESTONIA	MOZAMBIQUE	YEMEN
ETHIOPIA	MYANMAR	ZAMBIA
FINLAND	NAMIBIA	ZIMBABWE
FRANCE	NEPAL	
GABON	NETHERLANDS	
GEORGIA	NEW ZEALAND	
GERMANY	NICARAGUA	
	NIGER	
	NIGERIA	

The Agency's Statute was approved on 23 October 1956 by the Conference on the Statute of the IAEA held at United Nations Headquarters, New York; it entered into force on 29 July 1957. The Headquarters of the Agency are situated in Vienna. Its principal objective is "to accelerate and enlarge the contribution of atomic energy to peace, health and prosperity throughout the world".

IAEA HUMAN HEALTH SERIES No. 10

TRENDS AND PRACTICES IN DIAGNOSIS AND TREATMENT OF HEPATOCELLULAR CARCINOMA

INTERNATIONAL ATOMIC ENERGY AGENCY
VIENNA, 2010

COPYRIGHT NOTICE

All IAEA scientific and technical publications are protected by the terms of the Universal Copyright Convention as adopted in 1952 (Berne) and as revised in 1972 (Paris). The copyright has since been extended by the World Intellectual Property Organization (Geneva) to include electronic and virtual intellectual property. Permission to use whole or parts of texts contained in IAEA publications in printed or electronic form must be obtained and is usually subject to royalty agreements. Proposals for non-commercial reproductions and translations are welcomed and considered on a case-by-case basis. Enquiries should be addressed to the IAEA Publishing Section at:

Marketing and Sales Unit, Publishing Section
International Atomic Energy Agency
Vienna International Centre
PO Box 100
1400 Vienna, Austria
fax: +43 1 2600 29302
tel.: +43 1 2600 22417
email: sales.publications@iaea.org
<http://www.iaea.org/books>

© IAEA, 2010

Printed by the IAEA in Austria
October 2010
STI/PUB/1446

IAEA Library Cataloguing in Publication Data

Trends and practices in diagnosis and treatment of hepatocellular carcinoma. —
Vienna : International Atomic Energy Agency, 2010.
p. ; 24 cm. — (IAEA human health series, ISSN 2075–3772 ; no. 10)
STI/PUB/1446
ISBN 978–92–0–102710–8
Includes bibliographical references.

1. Developing countries — Liver — Cancer — Diagnosis. 2. Developing countries — Liver — Cancer — Therapeutics. 3. Radiotherapy.
I. International Atomic Energy Agency. II. Series.

IAEAL

10–00644

FOREWORD

Hepatocellular carcinoma (HCC), or primary liver cancer, is one of the most common causes of cancer and cancer death globally, and has an increasing incidence. It is currently the fifth most common cancer among men and eighth among women. In some Asian and African countries, its incidence is similar to that of lung cancer. It carries a very poor prognosis; the majority of patients die within a year, making it the third most common cause of cancer death. Currently, the main treatments offering the chance of cure are surgical resection and liver transplantation. However, owing to late presentation and underlying liver cirrhosis, these are suitable only for a small minority of patients. Therefore, new investigative protocols in radiotherapy using the most advanced technologies have been developed with some promise of cure and effective palliation. However, no uniform recommendations exist and the use of radiotherapy is limited by pre-existing liver disease.

The IAEA has extensive projects in radiation oncology in low and middle income countries, including areas in Asia and Africa where HCC is a common problem. Since there has been a reported significant increase in the use of radiotherapy in HCC, an expert review was considered timely to assess the role of radiotherapy within the entire framework of HCC management. This publication developed from the need to address this issue.

A meeting on the current knowledge of HCC epidemiology and management protocols was convened in October 2008. The given task was to define the current role of radiotherapy in the management of HCC. The greatest number of patients requiring optimal management protocols for HCC lives in Asia and sub-Saharan Africa, where in many countries access to radiotherapy and cancer care in general is limited and resources for research and access to the most advanced technologies are not available.

This review is intended for use in training courses and as a source of information on treatment decisions. It may also help guide the use of limited resources towards the most appropriate indications and help to differentiate approaches used for cure or palliation. An international registry of radiation treatment applications in HCC would facilitate conclusions regarding clinical applications.

The contributions leading to this publication are gratefully acknowledged. Special thanks are due to G. Stevens, consultant radiation oncologist at Auckland City Hospital and associate professor at the University of Auckland (New Zealand), for his work in producing the final report and updating the text and references. The IAEA officer responsible for this publication was E. Salminen of the Division of Human Health.

EDITORIAL NOTE

Although great care has been taken to maintain the accuracy of information contained in this publication, neither the IAEA nor its Member States assume any responsibility for consequences which may arise from its use.

The use of particular designations of countries or territories does not imply any judgement by the publisher, the IAEA, as to the legal status of such countries or territories, of their authorities and institutions or of the delimitation of their boundaries.

The mention of names of specific companies or products (whether or not indicated as registered) does not imply any intention to infringe proprietary rights, nor should it be construed as an endorsement or recommendation on the part of the IAEA.

The IAEA has no responsibility for the persistence or accuracy of URLs for external or third party Internet web sites referred to in this book and does not guarantee that any content on such web sites is, or will remain, accurate or appropriate.

CONTENTS

1.	EPIDEMIOLOGY, AETIOLOGY, PATHOLOGY	1
1.1.	Epidemiology	1
1.2.	Aetiology	1
1.2.1.	Liver cirrhosis	1
1.2.2.	Chronic viral hepatitis	2
1.2.3.	Aflatoxin B ₁ (AFB ₁) exposure	3
1.2.4.	Alcohol consumption	3
1.2.5.	Inherited metabolic diseases	4
1.2.6.	Other risk factors	4
1.3.	Pathology	4
1.3.1.	Appearance	4
1.3.2.	Tumour biology and behaviour	5
1.3.3.	Carcinogenesis	6
1.3.4.	Advances in molecular pathology	6
2.	CLINICAL FEATURES AND DIAGNOSIS OF HCC	7
2.1.	Clinical features	7
2.1.1.	Presentation	7
2.1.2.	Child–Pugh score	7
2.2.	Laboratory investigations	8
2.2.1.	Alpha-fetoprotein (AFP)	8
2.2.2.	Alkaline phosphatase and carcinoembryonic antigen ..	9
2.2.3.	Desgamma-carboxyprothrombin (DCP)	9
2.2.4.	GP-73	9
2.3.	Radiological detection	9
2.3.1.	Ultrasonography (US)	9
2.3.2.	Computed tomography (CT)	10
2.3.3.	MRI	10
2.3.4.	Summary of imaging	11
2.4.	Liver biopsy	11
2.5.	Algorithm for diagnosis of HCC	12
2.5.1.	Pre-existing cirrhosis	12
2.5.2.	No cirrhosis	13
2.6.	Screening for HCC	13
2.7.	Staging systems and prognosis	15

3.	TREATMENT OF HCC	17
3.1.	Introduction	17
3.2.	Surgery	17
3.2.1.	Resection	18
3.2.2.	OLT	19
3.2.3.	Transplantation or resection for HCC in cirrhosis	24
3.2.4.	Other, less common surgical situations	24
3.3.	Non-surgical treatment of HCC	25
3.3.1.	Ablative therapies	25
3.4.	Systemic therapies	30
3.4.1.	Cytotoxic chemotherapy	30
3.4.2.	Molecular targeted therapy	30
3.4.3.	Hormonal therapy	31
3.4.4.	Immunotherapy	32
4.	RADIOTHERAPY	33
4.1.	Rationale for radiation therapy	33
4.2.	Indications for radiation therapy	33
4.2.1.	Definitive, high dose radiotherapy	33
4.2.2.	Palliation with radiotherapy	35
4.2.3.	Radiotherapy combined with other therapies	36
4.2.4.	Bridge to transplantation	37
4.3.	Types of radiation therapy	38
4.3.1.	Brachytherapy	38
4.3.2.	Radioisotopes	38
4.3.3.	Photons	40
4.4.	Technical aspects of high dose external beam radiotherapy ...	43
4.5.	Radiotherapy toxicity	44
4.5.1.	Hepatic toxicity	44
4.6.	Gastrointestinal mucosal toxicity	47
4.6.1.	Biliary toxicity	48
4.6.2.	Other radiotherapy related toxicities	49
5.	FUTURE DIRECTIONS	50
5.1.	Introduction	50
5.2.	Existing treatment guidelines for HCC	50
5.3.	Treatment of HCC: The radiation oncologist's perspective	52

5.4.	Unresolved issues	53
5.4.1.	Dose escalation studies using radiotherapy as a single modality	53
5.4.2.	Development of combination strategies	53
5.4.3.	New radiotherapy technologies	54
5.4.4.	Redefinition of liver toxicity	54
5.5.	Recommendation for future studies	54
5.5.1.	Clinical trials of HCC incorporating radiotherapy	54
5.5.2.	Stem cell recovery of liver function	55
5.5.3.	Redefinition of staging	55
5.5.4.	Measurement of end points in palliation	55
6.	CONCLUSIONS	56
	REFERENCES	57
	ANNEX I: MOLECULAR PATHOLOGY OF HEPATOCELLULAR CARCINOMA (HCC).	75
	ANNEX II: TECHNICAL CONSIDERATIONS IN RADIOTHERAPY OF HEPATOCELLULAR CARCINOMA (HCC).	79
	ABBREVIATIONS.	87
	CONTRIBUTORS TO DRAFTING AND REVIEW	89

1. EPIDEMIOLOGY, AETIOLOGY, PATHOLOGY

1.1. EPIDEMIOLOGY

Heptocellular carcinoma (HCC) is the fifth most common cancer globally, with an estimate of more than 500 000 new cases annually, and it is the third leading cause of cancer deaths [1, 2]. A striking geographical difference in the incidence of HCC exists, with 80% of new cases occurring in developing countries. High incidence regions include sub-Saharan Africa and East and Southeast Asia, whereas low incidence regions include Northern and Western Europe and North America.

Better control of the risk factors has resulted in a recent decline in HCC in some places such as Taiwan, China and mainland China. In Taiwan, China, for example, mortality from HCC in male and female children younger than 15 years of age has decreased by up to 70% and 62%, respectively, as a result of vaccination against hepatitis B virus (HBV) [3]. However, there is a recent trend of increasing incidence of HCC in Europe and North America due to changes in lifestyle and an increase in HBV and the hepatitis C virus (HCV). In the United States of America, the age adjusted incidence has doubled over the past two decades [4]. There is a marked male predominance, with a male to female ratio of 24:1 [5].

1.2. AETIOLOGY

The key risk factors of HCC are well established and include chronic HBV and HCV infections [6, 7], cirrhosis [8], aflatoxin B1 [9] and inherited metabolic disorders.

1.2.1. Liver cirrhosis

The association of HCC with cirrhosis has been documented widely. Although cirrhosis and HCC development share some common risk factors, such as viral hepatitis and excessive alcohol consumption, cirrhosis itself is an independent risk factor for HCC [10, 11].

1.2.2. Chronic viral hepatitis

1.2.2.1. HBV

HBV is an enveloped DNA virus containing a partially double stranded, circular DNA genome, classified into the *Hepadnaviridae* family. The 3.2 kb HBV genome consists of four major open reading frames, P, S, C and X, encoding the reverse transcriptase essential for viral replication, the viral envelope proteins, the nucleocapsid (core) protein and the X protein, respectively. There are at least 300 million HBV carriers in the world and 8–20% of the population in endemic areas, including China, are carriers [12]. HBV transmission in adults occurs primarily by blood exchange and sexual contact, while children often acquire infection from their infected mothers at the time of birth [13, 14].

HBV is the dominant risk factor for HCC, causing up to 80% of HCCs worldwide. HBV acts as a pro-oncogenic agent indirectly and directly [15, 16]. The indirect mechanism involves the ability of HBV infection to induce hepatocellular necrosis, chronic inflammation and regeneration of the liver, eventually leading to cirrhosis and predisposition to HCC [17–19]. The direct carcinogenic mechanisms have been related to the integration of HBV DNA into the host genome. As HBV DNA insertions are frequently associated with deletions, amplifications or chromosomal translocations, HBV DNA integration may result in chromosomal instability [20]. When the expressions of tumour suppressor genes and proto-oncogenes responsible for regulating cell growth, differentiation and apoptosis are altered, selective growth advantage of infected cells may trigger the onset of tumour and cancer progression [21]. One such molecule is the HBx protein, which is a multifunctional regulator for a number of host processes by interacting with the virus and host factors [22]. For example, the HBx protein plays a role in modulating gene expression by interacting with promoters of oncogenes, cytokines and growth factors [23]. HBx also interacts with transcription activators such as the leucine zipper family, p53, and Smad4. The abnormal activation of the signal transduction in the hepatocytes may result in oncogenic alterations and outgrowth of genetically damaged cells.

1.2.2.2. HCV

HCV is an enveloped single stranded ribonucleic acid virus with a 9.6 kb genome, classified into the *Flaviviridae* family. There are six major genotypes with several subtypes based on the genomic sequence heterogeneity [24, 25]. Types 1a and 1b are the most common, contributing to up to 60% of global infections. HCV is usually spread by sharing infected needles and sexual contact

[26]. HCV has a worldwide distribution, but predominates in Italy, Japan and Egypt [27]. An estimated 3% of the world's population is infected by HCV, with more than 170 million chronic carriers at risk of liver cirrhosis or HCC [28]. HCV infected individuals have a seventeenfold increased risk of developing HCC, compared with HCV negative individuals [29].

Unlike the HBV infection, the HCV genome does not integrate into the host genome [30], and almost all HCC patients infected by HCV suffer from cirrhosis, suggesting that cirrhosis is the major risk factor of HCC development in individuals with HCV [31]. The polymerase enzyme of ribonucleic acid viruses such as HCV lacks efficient 'proofreading' ability, resulting in constant mutation and escape from the host immune response. Although the underlying mechanism of HCV-induced HCC development remains unclear, the core protein of HCV has been reported to have a significant role in HCC development in chronic hepatitis C [32]. The proposed mechanism suggests that the core protein binds with p53 and modulates cellular regulatory functions by regulating the expression of the cyclin-dependent inhibitor p21^{WAF1}, which promotes either cell proliferation or apoptosis [33, 34].

1.2.3. Aflatoxin B₁ (AFB₁) exposure

Extensive studies suggest that HCC risk is increased with high dietary intake of AFB₁ in Western Africa and China [35]. Aflatoxins are naturally produced mycotoxins, being secondary metabolites of *Aspergillus flavus* and *Aspergillus parasiticus* fungi. Warmth and moisture favour fungal contamination of staple crops such as rice, corn and nuts in developing countries, leading to increased dietary intake [36]. AFB₁ is the predominant form among known aflatoxins with the highest toxicity, classified as a category I human carcinogen and a potent genotoxic agent (International Agency for Research on Cancer [37]). Studies report that the synergistic effect of aflatoxin and HBV increases the risk of HCC by twenty-five- to thirtyfold [38].

1.2.4. Alcohol consumption

Although alcohol is not a carcinogen, the association between heavy alcohol intake and risk of HCC has been broadly reported in many epidemiologic studies [39–41]. Alcohol abuse leading to cirrhosis increases HCC risk appreciably by promoting liver cirrhosis. However, only severe, but not moderate, alcohol consumption is related to HCC [42, 43].

1.2.5. Inherited metabolic diseases

Other risk factors for HCC include inherited metabolic diseases such as hereditary hemochromatosis [44], alpha-1-antitrypsin deficiency and hereditary tyrosinemia. Hemochromatosis is an iron overload hereditary disease which involves a predominant mutation C282Y on the HFE gene [45]. The incidence of C282Y homozygosity is 1 in 250 persons in the general population and higher prevalence has been observed in individuals with northern European ancestry [46]. When hepatic production of the essential hormone hepcidin is aberrantly regulated, enterocyte iron absorption is disrupted [47]. Since iron cannot be removed from the human body, a chronic iron overload occurs, leading to severe organ damage and development of HCC [48].

1.2.6. Other risk factors

The role of tobacco smoking in the causation of HCC is controversial. Although the association is supported by some epidemiological studies [49, 50], the mechanism remains incompletely understood. However, cigarette smoke contains many hepatic carcinogens such as 3-aminobiphenyl [9].

Obesity and diabetes can lead to non-alcoholic steatohepatitis, which is an established risk factor for HCC, probably via progression of the steatohepatic disease to cirrhosis and HCC [51]. Obesity and diabetes have been reported as risk factors for HCC in some case studies. In particular, the synergistic effect of diabetes, viral hepatitis and heavy alcohol consumption in the development of HCC has been emphasized [9].

Other factors have also been implicated. For example, oral contraceptives consisting of estrogens and progestogens may act as inducers and promoters for liver tumours. The high level of inorganic arsenic metal in the drinking water of Japan and Taiwan, China, has been linked to HCC, possibly due to induction of oxidative stress by arsenic [9].

1.3. PATHOLOGY

1.3.1. Appearance

1.3.1.1. Macroscopic appearance

HCC is predominantly a soft light brown or tan coloured mass with very little stroma. Hemorrhagic areas are usually present and often extensive, because the tumour is highly vascular, deriving most of its support from very thin-walled

sinusoids. The rich blood supply comes chiefly from branches of the hepatic artery which grow with the tumour. Some areas of the tumour may be better differentiated to produce bile which gives the tumour a green discolouration. Production of bile is a diagnostic feature of HCC.

1.3.1.2. Microscopic appearance

Microscopically, the tumour cells commonly retain the recognizable features of hepatocytes, arranged in a trabecular (80%) or pseudoglandular pattern. Other histological changes may include acinar necroinflammation, steatosis or liver cell dysplasia [52].

HCC has been divided into several histological subtypes, which have some clinicopathological correlations:

- Combined hepatocellular-cholangiocarcinoma (HCC-CC) is a rare tumour in which dual differentiation towards both hepatocytes and bile duct epithelia coexists in the same tumour or the same liver. HCC-CC frequently exhibits an invasive character with frequent venous permeation and tumour microsatellite formation, which are more frequently seen in ordinary HCC than CC. This tumour has been reported to be more aggressive than HCC, with widespread metastases and regional lymph node involvement.
- Sclerosing HCC [53].
- Fibrolamellar HCC [54] occurs in young patients and has an equal sex distribution. It is not associated with HBV infection and has a better prognosis when completely resected.

1.3.2. Tumour biology and behaviour

HCC has a marked tendency to spread into portal vein branches within the liver and also the main portal vein, resulting in intrahepatic metastasis, which dominates the clinical picture. Similarly, invasion into the hepatic venous system and main hepatic veins may lead to systemic metastases to lung, bone and elsewhere. Lymphatic spread may lead to porta hepatic lymphadenopathy. However, in many cases, death occurs before metastases are extensive. Invasion of intra- or extra-hepatic bile ducts occurs less commonly, but can result in biliary obstruction.

Successful treatment of HCC poses particular challenges because in the majority of cases two diseases need to be considered: the aggressive HCC with a propensity for multiple foci and invasion, and a cirrhotic liver that may decompensate with minimal insult and is at risk of developing more tumours.

1.3.3. Carcinogenesis

Hepatocarcinogenesis is understood to be a multistep process with transition from normal liver through chronic liver diseases (chronic hepatitis and cirrhosis), liver dysplasia, dysplastic nodule and, finally, HCC. In the majority of the cases, HCC arises with a background disease of either chronic hepatitis or cirrhosis, although HCC can arise in an apparently normal liver.

The multistep process involves accumulation of chromosomal, genetic and epigenetic abnormalities. Recent evidence suggests that chromosomal instability emerges at an early stage during hepatocarcinogenesis and is an inherent property of tumour cells, ultimately resulting in acquisition of the malignant phenotype [55].

1.3.4. Advances in molecular pathology

Hepatocarcinogenesis is strongly linked to increases in allelic losses, chromosomal changes, gene mutations, epigenetic alterations and alterations in signalling pathways. These genetic changes are undoubtedly of fundamental importance to an understanding of the process of hepatocarcinogenesis and they have started to impact current treatments and treatment guidelines. Therefore, a discussion of these genetic and molecular issues is included in Annex I.

Compared with other cancers such as colon and breast cancers, gene mutations in HCC are relatively infrequent: p53 and β -catenin probably are the most frequently mutated genes in HCC. Interestingly, recent data suggest that HCC harbouring p53 and β -catenin mutation may arise from two independent pathways. In one, p53 mutation is associated with a high level of chromosomal instability, whereas in the other, β -catenin mutation is associated with frequent epigenetic alterations [56].

2. CLINICAL FEATURES AND DIAGNOSIS OF HCC

2.1. CLINICAL FEATURES

2.1.1. Presentation

The presentation of HCC varies according to the size of the mass or masses. With greater use of imaging, particularly ultrasound (US), small asymptomatic lesions are increasingly being diagnosed [57]. In many cases, the clinical manifestations are masked by features of underlying cirrhosis or chronic hepatitis. Large tumours may cause pressure effects and present with ill-defined upper abdominal pain, malaise, weight loss, fatigue and sometimes an awareness of an abdominal mass or fullness. Jaundice may result from compression of the common bile duct, or hepatic decompensation; ascites suggests advanced disease or co-existing cirrhosis. Other presentations include the paraneoplastic syndrome, hypercalcaemia, hormonal imbalance, gastrointestinal (GI) or oesophageal variceal bleeding and tumour-necrosis induced fever [58].

HCCs develop mainly as slow growing nodules which may be asymptomatic for many years. Estimated doubling times of HCCs vary between 1 and 19 months [59], with a median of six months [60].

It has been suggested that tumours with certain defined aetiologies may have more aggressive behaviour, but there are no conclusive data to support this. Data from untreated HCC show that the major factors influencing overall survival are severity of underlying liver dysfunction and tumour size at initial detection. Small HCCs at presentation have relatively long tumour doubling times, and overall survival with tumours of less than 5 cm was 81–100% at one year and 17–21% at three years without therapy [61]. These results suggest that if diagnosis can be made during the asymptomatic phase when the tumour is small, the opportunity for cure may be greater.

2.1.2. Child–Pugh score

As indicated above, the management of HCC for most patients is complicated by the presence of cirrhosis. The degree of cirrhosis is prognostic for survival of the patient in the absence of HCC and also for treatment of the HCC, as sufficient functioning liver must be retained. The Child–Pugh scoring system (Table 1) uses clinical examination and liver function tests to stratify patients for prediction of surgical mortality among cirrhotic patients [59].

TABLE 1. CHILD–PUGH SCORING OF SEVERITY OF LIVER DISEASE [59]

Variable	1 point	2 points	3 points
1. Encephalopathy	None	Moderate	Severe
2. Ascites	None	Slight	Moderate
3. Albumin (mg/dL)	>3.5	2.8–3.5	<2.8
4. PT prolongation ^a (INR ^a)	<4 s (<1.7)	4–6 s (1.7–2.3)	>6 s (>2.3)
5. Bilirubin (mg/dL)	<2	2.1–3	>3

^a PT: prothrombin time, INR: international normalized ratio.

The scores from Table 1 are summed to group patients into three classes, as follows:

- Child–Pugh A = 5–6 points, indicates good liver function; ~100% 1 year survival.
- Child–Pugh B = 7–9 points, indicates intermediate liver function; ~80% 1 year survival.
- Child–Pugh C = 10–15 points, indicates poor liver function; ~45% 1 year survival.

2.2. LABORATORY INVESTIGATIONS

2.2.1. Alpha-fetoprotein (AFP)

AFP, a serum protein synthesized normally by fetal liver cells and yolk sac cells, is the most widely studied tumour marker for HCC. AFP is produced by over 80% of HCCs. The normal range for AFP is 10–20 ng/mL and a level >400 ng/mL is usually regarded as diagnostic for HCC. However, two thirds of HCCs of <4 cm have AFP levels less than 200 ng/mL and up to 20% of HCC do not produce AFP, even when very large [62].

Modifications of AFP with differing carbohydrate structures may occur in HCC and can be detected by altered patterns of lectin binding. These altered profiles have led to the development of alternative diagnostic tests [63], but none are widely available or have been shown to enhance markedly diagnostic ability over AFP. False positive results occur, with AFP levels of 20–250 ng/mL seen with regenerating nodules in viral cirrhosis [64], testicular teratoma, benign liver

disease, normal pregnancy and obstetric abnormalities. Low human chorionic gonadotropin levels help to exclude these possibilities [63]. AFP levels are particularly helpful in monitoring HCC activity after treatment and in screening cirrhotic patients at risk of developing HCC [63].

2.2.2. Alkaline phosphatase and carcinoembryonic antigen

These serum markers may be elevated but are not useful diagnostically, as they are non-specific. Carcinoembryonic antigen levels are often raised with hepatic metastases from colorectal cancer [63].

2.2.3. Desgamma-carboxyprothrombin (DCP)

DCP is a prothrombin precursor resulting from failure to carboxylate glutamic acid residues and may be detected in the serum of HCC patients [65]. DCP has been used as an alternative tumour marker for HCC; 67% of HCCs have elevated levels, but as only 8% of small (<2 cm) HCCs have abnormal levels [66], DCP has not gained wide acceptance as a marker for HCC [63].

2.2.4. GP-73

GP-73 is a recently discovered Golgi protein that is increased in cirrhosis and HCC. DCP and GP-73 are purported to have superior positive and negative predictive values for early HCC compared with AFP. These findings suggest that these markers may eventually replace AFP as a screening assay for HCC [67].

2.3. RADIOLOGICAL DETECTION

2.3.1. Ultrasonography (US)

Imaging of the lesion usually begins with US (if not already performed), which provides information on the shape, echogenicity, growth pattern and vascular involvement of the tumour [68]. US can detect large tumours with high sensitivity and specificity, but has limitations in identifying smaller lesions, which is an essential requirement for improved outcomes in this disease. Expertise of the operator and use of dedicated equipment seem important to optimize results; where these are available, US detects 85% of tumours <3 cm, 85–95% of tumours 3–5 cm in diameter and can achieve 60–80% sensitivity in the detection of tumours measuring 1 cm [61].

The combination of AFP and US improves detection rates. Screening with US has been suggested at six monthly intervals on the basis of tumour doubling times. However, there is evidence that more frequent examinations may enhance sensitivity, but at the expense of a higher false positive rate [69]. Patients with a negative US and an elevated, but not diagnostic, AFP appear to be at higher risk and more frequent US, probably three monthly, may be appropriate in this group [70].

2.3.2. Computed tomography (CT)

CT is used for detection and evaluation of the extent of HCC [71]. Many combinations of techniques and contrast agents have been proposed to improve imaging [72]. Examples include:

- Lipiodol CT (CT following intra-arterial injection of lipiodol). Lipiodol was shown to detect a greater proportion of small HCCs in 22 patients who were subsequently surgically treated (86% for lipiodol CT versus 70% for US, 65% for CT, 62% for magnetic resonance imaging (MRI) and 73% for digital subtraction angiography; $p < 0.05$) [73].
- Helical CT hepatic arteriography combined with CT performed during arterial portography. This technique has shown promise as a more accurate diagnostic tool than several forms of MRI (spin echo, phase shift gradient recalled echo and triple phasic dynamic) in the pre-operative detection of HCC in 37 patients with cirrhosis [74]. Multiphase imaging is important to characterize the vascular features of a hepatic lesion which may be useful in distinguishing HCC from other liver cancers. HCC typically enhances in the arterial phase of imaging and washes out (more than the adjacent liver) in delayed phase imaging.

2.3.3. MRI

MRI techniques are extremely useful in the identification and characterization of regenerating nodules, dysplastic nodules and HCC. Arterial phase dynamic MRI has been reported to allow greater detection of HCC than arterial-phase CT (but not for the delayed phase) [75] and MRI during arterial portography has been suggested to have greater value than CT during arterial portography, to distinguish benign lesions and pseudolesions [76].

2.3.4. Summary of imaging

Despite numerous approaches, no single investigation has been shown to be clearly superior and both MRI and CT scanning yield similar detection rates for HCC [77]. Radiological imaging with US, CT and angiography usually understages HCC [78–80]. The development of US contrast agents and the improving technology of MRI, using iron or gadolinium contrast agents, may enhance the ability to detect satellite or second distant lesions within the liver [81]. The exact role of these contrast agents in treatment planning is uncertain and while these may produce major changes in the diagnostic radiology of HCC in the near future, at present their role should be regarded as experimental [82].

Accurate diagnosis is important for localized treatments such as resection and radiotherapy, as the precise size of the tumour and any associated satellites, or of second primary HCC, will influence the extent of resection (or the radiotherapy treatment volume), but the presence of cirrhosis may limit the tolerance of treatment. Conversely, understaging the extent of intrahepatic tumour has little significance in the selection of patients for transplantation, as prognosis relates to the pre-operative radiological assessment of the tumour rather than to the actual stage at pathological examination of the removed organ [80].

2.4. LIVER BIOPSY

When aggressive treatment of HCC is possible but the diagnosis remains uncertain, a percutaneous liver biopsy or fine needle aspirate under US or CT guidance may aid diagnosis [83]. In a study of 121 patients with suspected HCC ≤ 3 cm using US, 118 were finally diagnosed as HCC by percutaneous biopsy, CT and angiography. Retrospective analysis of results produced a correct diagnosis of HCC in 87.3% by histology, 55.1% by CT and 52.5% by angiography. However, for tumours ≤ 1.5 cm, the specificity of the imaging techniques fell markedly and the correct diagnosis was obtained in 88.5% (biopsy), 34.6% (CT) and 23.1% (angiography). On the basis of these findings, it has been suggested that percutaneous biopsy with histological examination is the most reliable method of making a definitive diagnosis of small HCC [84].

The requirement for histological confirmation of all HCC is controversial, owing to the added risks of biopsy (haemorrhage, inadequate sampling and needle track metastases) versus the higher false positive results from imaging alone. Some authors have suggested that percutaneous biopsy of potentially resectable tumours may not be appropriate, as patients with resectable HCC occasionally develop post-resection recurrence along the needle track [85]. The

risk of needle track recurrence may be reduced if the length of interposing liver parenchyma exceeds 1 cm, as shown in a study of 139 liver biopsies in which two cases of bleeding occurred following the procedure, both cases having interposing tracks of <1 cm [86]. The risk of seeding of HCC does not appear to be related to tumour size [79]; therefore, if curative treatment is considered, biopsy should be avoided if possible, even for small lesions [87].

2.5. ALGORITHM FOR DIAGNOSIS OF HCC

When a patient presents with a liver mass, there is a requirement to make a diagnosis and to stage the disease. The commonest clinical scenario is a patient with cirrhosis and a mass discovered on US where AFP may or may not be raised.

2.5.1. Pre-existing cirrhosis

2.5.1.1. *Liver mass >2 cm in diameter*

- Of these lesions, >95% are HCC [88].
- If AFP is raised, this confirms the diagnosis and further investigation is only required to establish the most appropriate therapy.
- If AFP is normal, further radiological imaging (CT, MRI, or lipiodol angiography with follow-up CT) will usually allow a confident diagnosis to be made and proceed to assessment of treatment without the need for biopsy [73, 89, 90]. In the few cases where diagnostic doubt persists and would affect management, biopsy is indicated [87].

2.5.1.2. *Liver mass <2 cm in diameter*

- Approximately 75% are HCC [91].
- Using CT and/or MRI, a firm diagnosis of HCC is still difficult to reach when the nodule is <1 cm in diameter and short term follow-up is suitable in this setting.
- Nodules 1–2 cm in diameter should be further studied by the determination of serum AFP and additional imaging, either CT and/or MRI, even though diagnosis should rely on histology [92].

2.5.1.3. *Non-invasive criteria*

Criteria for the diagnosis of HCC in cirrhotic patients without the requirement for biopsy have been proposed. The basis for considering this approach is that:

- The incidence of HCC is high in cirrhotic patients.
- Any focal lesion growing in a cirrhotic liver has a high probability of being neoplastic; either a pre-malignant dysplastic nodule or an HCC.
- Most HCCs are hypervascular during the arterial phase of contrast enhancement, with absence of discrete hypervascularity in other lesions.

The diagnosis of HCC has been proposed by the findings of either:

- Two imaging techniques showing a nodule of >2 cm with arterial hypervascularity; or
- A single positive imaging technique and AFP of >400 ng/mL.

These criteria are simple, specific and easy to use, even by a non-specialist [93]. These non-invasive criteria have yet to be validated in large scale studies. New criteria are required for tumours <2 cm in diameter [94].

These recommendations for the diagnosis of HCC in a patient with cirrhosis are summarized in Table 2.

2.5.2. **No cirrhosis**

With a liver mass as the presenting problem, the initial investigation is AFP:

- If the AFP is raised, in the absence of a germ cell tumour (particularly testicular), the diagnosis of HCC is confirmed.
- If AFP is normal, a search for other causes (non-liver primary) and further radiological assessment are required.
- Radiological imaging can exclude benign liver lesions (e.g. cysts, haemangiomas) with a high degree of sensitivity and specificity. In situations where considerable doubt exists, biopsy of the lesion is required [91].

2.6. SCREENING FOR HCC

A number of series demonstrate the value of AFP, either alone or in combination with US, in screening for HCC [93]. The largest screening study is

TABLE 2. DIAGNOSTIC PROCESS FOR A LIVER NODULE NEWLY DISCOVERED BY ULTRASOUND IN PATIENTS WITH CIRRHOSIS [94]

Nodule size (diameter) (cm)	Likelihood of HCC	Recommended diagnostic procedure
<1	Improbable (<50% are finally HCC)	Repeat US at 3 months; if progression, proceed to step below
1–2	Probable	Serum AFP, CT and/or MRI Biopsy required for diagnosis, but 40% are false negatives
2–3	Highly probable	Apply non-invasive criteria (AFP, CT and/or MRI) Biopsy is indicated in the absence of arterial hypervascularity
>3		Apply non-invasive criteria (AFP, CT and/or MRI), biopsy rarely indicated

in the Alaskan population with a high HBV carrier rate. Screening was undertaken in the total population with hepatitis B surface antigen (HBsAg) positivity, irrespective of viral replication. The results of this study showed that from 1982 to 1998 there were 18 299 AFP estimations undertaken in 2230 HBsAg positive individuals. Twenty cases developed HCC. Of these, five were inoperable at presentation and 14 had resections, six of which recurred [95]. A similar study of patients with HBV, only 4% of whom had proven cirrhosis, detected 14 cancers in 1069 cases screened [96]. Prospective studies of patients with viral cirrhosis have been carried out using US and AFP measurements and showed that 64–87% of detected tumours were single and 43–75% were ≤ 3 cm in diameter [97].

A New Zealand study compared the outcomes of chronic hepatitis B carriers with HCC who were identified in a new HCC screening programme, using 6 monthly AFP and US. There was a marked improvement in identifying treatable, early stage cancers among this population with endemic HBV infection, as well as overall improved survival in the screened group compared with unscreened patients. Even with a 3 year lead time bias correction, screened cases had a superior outcome. However, as this was not a randomized study, this result could be due to selection bias [98].

Marrero et al. assessed the utility of DCP, GP-73 and AFP as markers for identifying patients with early stage HCC. DCP and GP-73 had superior positive and negative predictive values for early HCC compared with AFP. These findings suggest that these markers may eventually replace AFP as a screening study for HCC. However, results of a planned, multicentre trial of markers for early HCC and an easier assay for measuring serum GP-73 are needed before these tools can be adapted for routine screening [67].

2.7. STAGING SYSTEMS AND PROGNOSIS

Although surgery (resection or transplantation) is the preferred option for curative treatment in localized HCC, recurrence rates remain high and long term survival is poor. Recurrence in the liver is the main cause of poor prognosis in patients with resectable HCC and the type of hepatectomy has little influence on recurrence or long term survival. Consequently, there is an urgent need to identify factors that can predict tumour recurrence and prognosis in order to stratify patients into risk groups that warrant consideration of more intensive monitoring and/or clinical trials assessing adjuvant treatment.

Pathological prognostic factors are useful not only in predicting survival but also to stratify patients into risk groups for relapse. Tumour grade, size of tumour, microvascular invasion, portal vein tumour thrombus and the presence of tumour microsatellite lesions have all been found to predict survival [99, 100]. With advances in understanding of tumour biology, molecular biomarkers of carcinogenesis have been investigated with regard to both their prognostic significance and their potential as therapeutic targets [101].

Cancer staging is used to predict prognosis, to stratify patients for clinical trials and to guide management [102–104]. However, as previously stated, there is an added dimension in HCC due to the presence of cirrhosis as an independent prognostic factor.

There is no consensus regarding the preferred HCC staging system, which remains controversial. To date, several HCC staging systems have been developed. These include:

- TNM: The TNM staging system, developed by the International Union Against Cancer (UICC), is less predictive of prognosis than the Okuda system in HCC patients undergoing hepatic resection [105].
- Okuda: The Okuda staging system [106], which is based on variables including liver function and tumour size, was proposed to be discriminatory for patients with unifocal HCC who underwent surgery in Western countries [107].

- CLIP: The Cancer of the Liver Italian Program staging system uses the following parameters: the Child–Pugh score, tumour morphology and extent, AFP and the presence of portal vein thrombosis [108]. One study found that the CLIP system had a greater predictive power for survival than the Okuda system [109].
- JIS: Aside from the CLIP scoring system, Kudo et al. reported that the Japan Integrated Staging (JIS) score is a better staging system for HCC, which includes the TNM stage according to the criteria set by the liver cancer study group of Japan as well as the Child–Pugh score [110]. For treatment with radiation therapy (radiotherapy), the TNM staging approach appeared to be the best predictor of prognosis. Staging systems that reflect liver disease status (Okuda stage, CLIP, and JIS score) showed limitations in stratifying patients undergoing radiotherapy into different prognostic groups [111]. However, these systems are based on tumour status with or without liver function. Treatment factors were not considered.
- BCLC: The Barcelona Clinic Liver Cancer staging system [112, 113] was based on data from several independent studies representing different disease stages and/or treatment modalities. It includes variables related to tumour stage, liver functional status, physical status and cancer related symptoms [114–116]. The main advantage of the BCLC staging system is that it links staging with treatment modalities and with an estimation of life expectancy that is based on published response rates to the various treatments [112, 117].
- AASLD: For the best assessment of prognosis, the American Association for the Study of Liver Disease recommended that the staging system should take into account tumour extent, liver function and physical status. The impact of treatment should also be considered when estimating life expectancy. Currently, the BCLC system is the only system that takes into consideration the treatment options available for patients [118].

3. TREATMENT OF HCC

3.1. INTRODUCTION

The treatment of HCC is a therapeutic challenge. Many different medical disciplines need to be involved and a high degree of clinical expertise is needed to achieve the best outcomes for patients. HCC is a slowly growing malignancy with a 50% two year survival of untreated patients diagnosed with small tumours. Once patients become symptomatic, however, the mean survival is approximately 6 months.

The factors which dominate treatment decisions include patient age, the number, size and location of intrahepatic lesions, and the degree of cirrhosis. Although many modalities of treatment may be utilized, curative treatment predominantly involves surgery. However, a range of other modalities is available for treatment to prolong disease control, potentially with curative intent. These include high dose external beam radiotherapy, either alone or in combination with other modalities, such as injected radioisotopes, alcohol injection, radio frequency ablation, cryotherapy and regional chemotherapy. Many of these modalities are also suitable for palliative treatment, which, unfortunately, is the situation for most patients with HCC. This section will deal with all treatments except those involving radiotherapy, which is covered in Section 4.

3.2. SURGERY

As stated above, the only *proven* curative therapy for HCC remains surgical, being either hepatic resection or orthotopic liver transplantation (OLT). Therefore, patients with single, small (<5 cm) HCC, or with no more than three lesions, each ≤ 3 cm in diameter, should be referred for surgical assessment [119]. However, only a small proportion of patients with HCC will be suitable for either of these potentially curative treatments. There are no randomized clinical trials (RCTs) comparing the outcome of surgical resection and OLT for HCC. The decision as to which therapy is appropriate will depend on availability of resources and individual tumour characteristics. Early results of OLT for HCC were poor [120], with 5 year survival figures of <50%, mainly due to tumour recurrence. It is now clear that this was the result of poor selection of patients for transplantation [87].

3.2.1. Resection

Hepatic resection should be considered as primary therapy in any patient with HCC and a non-cirrhotic liver (including the fibrolamellar variant discussed below). Resection can also be carried out in highly selected patients with hepatic cirrhosis and well-preserved hepatic function (Child–Pugh A) who are unsuitable for OLT. Such surgery carries a high risk of post-operative decompensation and should be undertaken in units with expertise in hepatic resection and management of liver failure [119]. Less than 25% of HCC patients are suitable for surgical resection due to several factors, including the presence of cirrhosis, anatomically unresectable disease, extrahepatic spread and vascular spread [87]. The results of surgical treatment of HCC are inferior to the results of treating hepatic metastases from colorectal cancer, although the same general surgical principles apply in both conditions.

Resection remains the treatment of choice for lesions confined to one lobe. The aim of resection is to remove the entire portal territory of the tumour containing segment(s) with a 1 cm clear margin, while preserving maximum liver parenchyma to avoid hepatic failure. In non-cirrhotic HCC patients, greater resection is tolerated as the capacity for liver regeneration is not compromised [121]. Over the past decade, the use of parenchymal-sparing segmental resections has increased significantly. The number of hepatic segments resected, and operative blood loss, were the only predictors of both perioperative morbidity and mortality. Reduction of both these factors is largely responsible for the overall decrease in perioperative mortality [122].

Complications associated with surgical resection include haemorrhage, bile leakage, stress ulceration complicated with bleeding, transient haemobilia, atelectasis and inflammatory changes in the right lung [123]. Hospital mortality rates for resection alone vary from 5 to 24% [121]. Mortality was mainly due to hepatorenal or cardiorespiratory failure and also occasionally to myocardial infarction or disseminated intravascular coagulation [123].

3.2.1.1. *Non-cirrhotic liver*

Surgical resection in the non-cirrhotic patient is the ‘gold standard’ for the treatment of HCC. The indications for resection are lesions limited to one lobe, mild hepatic dysfunction and absence of extrahepatic spread of the cancer. The 1 year survival rate post-resection varies between 50 and 80%, with a 5 year maximum survival of 50%. There is a 68% recurrence rate. In non-cirrhotic HCC patients, partial hepatectomy is associated with a 5 year survival of 30–68% [124, 125].

Prognosis following resection is improved for tumours with the characteristics shown in Table 3.

3.2.1.2. *Cirrhotic liver*

In the presence of cirrhosis, the risks from surgery are increased. Cirrhosis affects post-operative survival in several debilitating ways and remains the major determinant of post-operative survival for the following reasons:

- Liver regeneration cannot occur in the cirrhotic remnant.
- Recurrent HCC may develop in the hepatic remnant [126].
- Pre-operative clotting is abnormal in cirrhosis.
- Hepatic reserve is poor [127].

The pre-operative Child–Pugh score, hepatic reserve [128] and indocyanine green 15 min retention rate [120] may also correlate with post-operative prognosis. With cirrhosis, operative mortality is higher, and of those who survive the surgery, a 5 year survival of 25–30% has been recorded [129]. Wu et al. suggested that the size of the tumour is also a significant determining factor in survival. Of 2051 cases, ‘small’ (<5 cm in diameter) and ‘very small’ (<3 cm in diameter) tumours had post-resection 5 year survivals of 79.8% and 85.3%, respectively [130]. Incidence of HCC recurrence, however, has been reported to vary between 20 and 70%, with almost all relapses occurring within two years of surgery [124].

3.2.2. **OLT**

In the early days of OLT, HCC was a frequent indication for transplantation. The results were inferior to those for benign disease, owing to the high recurrence rate. Thereafter, HCC accounted for <5% of all liver transplants. However, increasing data in the literature suggest that, with selection of appropriate candidates, the results of OLT for HCC may be as good as for benign disease [126].

TABLE 3. TUMOUR CHARACTERISTICS WITH IMPROVED SURVIVAL FOLLOWING RESECTION

<5 cm diameter	No vascular invasion
Tumour margins >5 mm	Lower tumour grade or stage
Single nodule (compared with multiple)	No lymph node involvement

OLT is indicated for patients with HCC who have centrally located tumours not amenable to resection, large tumours, bilobar lesions, cirrhosis and for patients who have no evidence of extrahepatic involvement. Early outcomes in a collective series of 654 patients from the United States Registry, Pittsburgh, Boston and Europe were 40–80% 1 year survivals, 18–65% 5 year survivals, and 21–67% recurrence rates [126].

Three non-randomized studies comparing liver resection ($n = 261$) and OLT ($n = 225$), conducted across several centres (Pittsburgh, France and Hanover) showed similar 1 and 5 year survivals. However, for cirrhotic patients with HCC, mean survival time was improved following transplantation compared with resection [126].

Management of HCC by OLT remains contentious, owing to the restricted availability of organ donors and the high rate of recurrence, due to circulating HCC cells implanting in donor hepatic tissue and/or due to unrecognized micrometastatic disease [131]. In addition to the standard investigations used to diagnose HCC, patients should undergo chest and abdominal CT scans to exclude metastases or nodal disease [121].

The 3 and 5 year survival rates following OLT were 16–82% [132] and 19.6–36% [133], respectively. These wide ranges are not unexpected, as two subgroups with quite different prognoses have been enrolled into OLT trials: those with large and unresectable HCCs and those with small incidentally discovered HCCs with concomitant cirrhosis. Recurrence in the grafted liver, lungs or bone occurred in >80% of the large and unresectable tumour group at 2 years but in <5% in the group with small tumours [134]. Survival following OLT was not influenced by patient age, gender, extent of human leukocyte antigen matching, rejection, immunosuppressive regimen or surgical technique used [132].

In addition to tumour recurrence, cytomegalovirus infection, acute rejection, atelectasis, pleural effusion, pneumonia, hepatic encephalopathy, invasive fungal infection and neurological disease have all been observed after OLT [131]. Chronic liver rejection is also a major problem [135], as are intra- and post-operative mortality rates, which approach 10–20% [136].

To date, OLT has provided the best chance of a cure for most patients with HCC. The surgical procedure for this group of patients is generally simpler than for patients transplanted for end stage liver disease. Unlike patients with end stage liver disease, most patients with HCC are in relatively good physical condition, with well-compensated cirrhosis, absent or mild portal hypertension and without the peripheral stigmata of advanced liver disease. OLT is effective and indicated for patients with stage I and stage II tumours [87].

Adult living related liver transplantation using the right lobe is an alternative to cadaveric donor liver transplantation. However, the recurrence rate

of cancer in the transplanted liver is high. In addition, in patients who have chronic hepatitis B or C infection, the virus reinfection rate within the transplanted liver is also high. Previously, the outlook for patients with replicating HBV was worse due to HBV recurrence and consequently these patients were not considered candidates for transplantation. However, effective antiviral therapy is now available [87]. Undoubtedly, if donor liver grafts were readily available, many patients with locally advanced HCC might benefit from transplantation. However, living related liver transplantation for patients with locally advanced HCC poses the ethical problem of potentially fatal risk to the healthy donor, coupled with the heightened risk of early post-transplant recurrence and death of the recipient. Another possibility for patients with advanced, intrahepatic HCC is the use of livers from deceased donors as a means to expand the pool of available donors [137].

3.2.2.1. Milan criteria

Mazzaferro et al. reported from a prospective study in 1996 that small HCCs (1 nodule <5 cm or 3 nodules <3 cm) had an excellent chance of recurrence free long term survival after OLT [132]. These 'Milan criteria' are now widely accepted. Therefore, OLT represents the best available treatment for a small HCC in the patient with cirrhosis (even Child–Pugh A) and should be performed as soon as possible after diagnosis to improve survival. Resection for Child–Pugh A cases should be limited to patients with contraindications to OLT, such as psychiatric problems, advanced age, high grade tumour, extrahepatic spread of the tumour, or non-availability of transplantation [138]. Using the Milan criteria, 3 year post-transplant survival was 83% with an 8% recurrence rate. The recurrence rate of HCC found incidentally at the time of OLT for non-malignant indications is very low [139].

3.2.2.2. Expanded Milan criteria

Patients with nodule(s) in excess of the Milan criteria (University of California, San Francisco expansion criteria) have a significantly lower chance of cure after OLT and should not routinely be considered for transplantation. However, cure remains possible if there is no extrahepatic spread.

In 2001, Yao et al. proposed that the Milan criteria for transplantation eligibility could potentially be expanded to either a unifocal tumour mass <6.5 cm in diameter or multifocal tumours, fewer than four in number, each <4.5 cm in diameter with total tumour diameter <8 cm (now designated stage T3A) and demonstrated a 75% 5 year survival. This proposal is problematic because it was based on tumour size and number identified by histopathological

review of the removed liver, rather than the clinically available pre-operative radiological evaluation [140].

Recently, these authors reported a new analysis, comparing the outcomes after transplant of 17 T3A patients versus 53 T1,2 patients, all staged by radiological evaluation before transplantation. They found similar 3 year survival between the groups. Preoperative understaging occurred in 17% of T1,2 patients and in 35% of T3A patients. However, 23% of pre-operatively staged T3A patients were overstaged, having T2 tumours on histopathology [141].

A French group also assessed the expanded Milan criteria for OLT in patients with HCC and confirmed the original findings of Yao et al. of good 5 year survival based on tumour explant data [142]. However, longer term assessment is required, as early and aggressive recurrence occurred in patients with good prognosis according to the Milan criteria, and conversely, some patients with high grade tumours remained recurrence free [138].

Overall, these studies indicate the pressing need for a large multicentre trial to determine whether the current tumour size criteria for transplantation can be modestly expanded. These studies also caution that many patients will be under- and overstaged by current radiological evaluation [143].

3.2.2.3. Model for ESLD score

As many patients with HCC become ‘untransplantable’ whilst waiting for liver transplantation owing to progressive tumour that exceeds the Milan criteria, efforts were made to change organ allocation policy in the USA. In February 2002, allocation of organs for OLT in the USA changed to the model for end stage liver disease (MELD) system and special exception points were granted to patients with HCC. T1 lesions (solitary HCC <2 cm) received 24 MELD points, which is equivalent to a 15% 3 month waiting list mortality, and T2 (solitary lesion 2–5 cm or 2–3 lesions each <3 cm) received 29 MELD points, equivalent to a 30% 3 month mortality. A priority MELD weight of 24–29 points is given to patients with HCC who meet the Milan criteria while awaiting transplantation. Under this system, transplantation in patients with HCC increased 350% over a corresponding time interval from the previous year. It was found that 86–91% of patients with HCC received a transplant within 3 months of being issued a priority MELD score [144]. The end result was that HCC became a major indication for OLT, representing 22% of all adult deceased donor liver transplants. This system may have disproportionally favoured HCC patients, because <7% of potential candidates with HCC were removed from the waiting list for tumour progression or other causes [143].

3.2.2.4. Reduced MELD exception point

A review of the explant pathology reports from this first period of MELD transplant allocation showed that at least 23% of the patients transplanted for HCC had no evidence of HCC on further evaluation, including 31% of all patients with a T1 lesion. Additionally, during this period, withdrawal of patients with T1 tumours from the transplant waiting list due to death, deterioration in performance status, or progressive HCC was only 4% [144].

Subsequently, the United Network for Organ Sharing changed the organ allocation policy, with patients with T1 lesions receiving 20 points and those with T2 lesions receiving 24 points, i.e. reduction in the MELD exception points. HCC now represents about 14% of all adult OLT in the USA [144].

Sharma et al. assessed the impact of the reduction in the MELD exception points for HCC. They showed no differences in the 12 month dropout rate on the transplant waiting list, no differences in survival while waiting for OLT and no differences in post-OLT survival. Thus, reducing the MELD score for HCC candidates did not adversely affect patient outcomes. More recently, exception points were eliminated for patients with T1 lesions because of their excellent short term survival [144].

Analysis of the Milan criteria and other systems will continue in an effort to refine criteria for entry of patients with HCC into the United Network for Organ Sharing liver transplant waiting list [139]. Continued assessment and refinement of this allocation policy is ongoing and, clearly, the changes are a great improvement on the former scoring systems [144].

3.2.2.5. Transplantation following resection of HCC in cirrhotic patients

Owing to the chronic shortage of organ donors, many clinicians have suggested that OLT cannot be advocated as the primary treatment modality for HCC without overwhelming the transplant system. A group from Clichy, France, reported the outcome of patients who had undergone hepatic resection for HCC prior to transplantation. They found no differences in survival between the patients with prior resection and those without, after a median follow-up period of 32 months [145].

In 2004, another group assessed 47 patients with HCV-associated HCC who conformed to the Milan criteria and underwent resection. They found a low 5 year survival of 49% compared with an expected survival of 74% with OLT. Additionally, 61% of the tumour recurrences were more advanced than the Milan criteria, thus contraindicating 'rescue OLT'. These authors suggested that using resection as a bridge to transplant was a better strategy than resection with salvage transplant [146]. In reality, however, salvage transplantation after

resection is rarely possible. While surgery may serve as a better bridge to transplantation, local ablative therapies discussed below are utilized more often in this setting [143].

3.2.3. Transplantation or resection for HCC in cirrhosis

It is well established that patients with the Milan criteria have an almost zero recurrence rate for HCC following OLT and have a prognosis the same as that for a similar underlying liver disease without HCC [132]. Relaxation of these criteria to include the expanded Milan criteria carries a higher risk of HCC recurrence and poorer overall prognosis. Resection of HCC is a viable option, with short term survival figures very similar to transplantation. After three years of follow-up, however, there is a clear advantage for transplantation in terms of tumour free survival [147].

Resection is only suitable for patients with excellent liver function (Child–Pugh A), because of the high risk of hepatic decompensation. Perioperative mortality in experienced centres remains between 6 and 20%, depending on the extent of the resection and the severity of preoperative liver impairment [148]. The majority of this early mortality is due to liver failure. The residual liver after resection continues to have a malignant potential. Recurrence rates of 50–60% after five years of follow-up after resection are usual [149] and the majority of this recurrence is intrahepatic, representing either satellite nodules or de novo second tumour development. Small satellite nodules are not usually detected by preoperative imaging, although the increasing use of intraoperative US may allow detection and better resection margins [150].

In patients with cirrhosis, both resection and transplantation probably have a role. In areas of the world where organ donation rates cannot supply existing demand, resection is likely to be widely used. Transplantation probably offers the best chance of cure for patients with small tumours and cirrhosis and is therefore the treatment of choice, even in patients with Child–Pugh A cirrhosis. Any patient with a single tumour ≤ 5 cm in diameter should be assessed for surgery in a centre where resection or transplantation is available [87].

3.2.4. Other, less common surgical situations

3.2.4.1. Liver transplantation or resection in fibrolamellar HCC

Fibrolamellar HCC has a very different biology and arises in non-cirrhotic liver. Surgical resection for this tumour is, therefore, less likely to produce liver failure. The overall survival for fibrolamellar HCC at 5 years is 25–36% [151]. As it arises without pre-existing liver disease, fibrolamellar HCC usually presents

with symptoms of locally advanced disease and vascular or diaphragmatic involvement. Reported outcomes following resection are poor, with 12–65% 5 year survival rates [152]. OLT has been performed for fibrolamellar HCC with 5 year survival rates of 28–49% [153]. However, as tumour recurrence remains common, resection remains the main surgical procedure for this rare tumour, where donor organ shortages exist [87].

3.2.4.2. Incidental HCC

Small HCCs are not infrequently found in liver pathology specimens. These are known as ‘incidental HCCs’. They have a very good prognosis, e.g. 91% survival at 33 months for a cohort of 12 such tumours[154, 155].

3.3. NON-SURGICAL TREATMENT OF HCC

3.3.1. Ablative therapies

A number of non-surgical therapies are in clinical use for HCC. Percutaneous ablative therapies are well described, most commonly using ethanol injection. Radiofrequency ablation (RFA) and cryotherapy are more recent techniques to produce tumour necrosis with low morbidity and mortality. As there are no RCTs of alcohol injection versus RFA and cryotherapy, or of these techniques versus resection, assessment of the literature relies on comparisons of prospective series of patients treated by the different techniques. Chemoembolization can also produce tumour necrosis and has been shown to improve survival in highly selected patients with good liver reserve. Chemoembolization using lipiodol is effective therapy for pain or bleeding from HCC [87].

3.3.1.1. Percutaneous ethanol injection (PEI)

PEI may induce 70–100% coagulation necrosis of the tumour via protein degeneration and thrombotic effects [156, 157]. Using local anaesthetic for the skin, abdominal wall and liver capsule, a 22 gauge Chiba needle is introduced percutaneously into the liver tumour under US or other guidance system. Absolute alcohol (99.5%) is slowly injected, with frequent adjustment of the needle tip to achieve distribution within the whole tumour. PEI can be repeated several times a week according to tumour size and patient compliance. Contraindications to its use are gross ascites, severe clotting abnormalities and obstructive jaundice. Good survival rates following PEI have been achieved, such

as 5 year figures of 44% in Child–Pugh A patients, 34% in Child–Pugh B patients [158] and 3 year figures of 63% in patients with single lesions and 31% in those with multiple lesions [157].

The selection criteria for PEI are:

- HCC <3 cm in diameter;
- No more than three lesions;
- No severe hepatic dysfunction;
- Child–Pugh A or B cirrhosis [131].

These encouraging survivals have been derived from uncontrolled studies. In a cohort of PEI ($n = 30$) compared with resection ($n = 33$), there was no difference in 1–4 year survivals between the two treatments, although recurrence at 2 years was higher in the PEI group (66% versus 45%) [159]. Combination treatment with transarterial chemoembolization (TACE) and PEI would be of interest [160], but a controlled trial of PEI/TACE versus resection may be unethical, as resection would be denied to patients with resectable tumours [131].

Although PEI has not been subjected to RCTs, there is a considerable literature on its use in HCC. In large series, complete response rates of 75% in tumours <3 cm in diameter have been reported, with 5 year survival rates of 35–75% [27]. These studies have generally been restricted to patients with good underlying liver function. The largest series with 746 patients showed 79% and 47% survivals at 3 and 5 years, respectively, in patients with Child–Pugh A cirrhosis (239 patients) and 63% and 29%, respectively, in Child–Pugh B cirrhosis (149 patients) [161].

The results of series from Asia and Europe report similar survival rates. One problem in the interpretation of these series is that a histopathological diagnosis of HCC was not obtained in all series. This could introduce bias into series with a substantial number of lesions <2 cm in diameter, where the diagnosis may be uncertain. Treatment of larger and multiple lesions is possible, often requiring repeated sessions and general anaesthesia, but recurrence occurs in more than 50% at one year and only 10% of 3–4 cm lesions were completely ablated [162].

Treatment is technically very difficult in lesions affecting the posterior segments of the liver [108]. Complications associated with PEI include pain, fever and transient drunkenness. Haemorrhage, needle track seeding [163] and hepatic failure are more serious adverse effects [164]. Complications are uncommon, but seeding in the needle tract occurs in 3% and serious bile duct injury in 1% [164, 165].

The largest series to report complications included 1066 patients, for whom the mean number of sessions needed to ablate a HCC nodule was 6.7. There was

one death (0.09%) and 34 complications (3.2%), including eight episodes of bleeding and seven cases of tumour seeding. Pain following injection required cessation of therapy in 3.2% [164].

Comparison with other techniques is difficult. However, historical comparison suggests little difference in survival rates between resection, transplantation and PEI for tumours <3 cm in diameter. A study of 260 tumours <5 cm in diameter in Child–Pugh A cirrhosis showed a 3 year survival of 79% for surgery and 71% for PEI, compared with 26% for no treatment [161]. Similar results have been reported from other centres [159]. Most experts regard surgery as the therapy providing the best chance of cure and PEI as the best therapy for patients with small inoperable HCCs [164].

Experimental studies have been undertaken injecting agents other than ethanol, e.g. cisplatin and cold acetic acid. Local injection of acetic acid, in one RCT of 60 patients with tumours <3 cm in diameter demonstrated a higher survival rate when compared with PEI (92% versus 63% at 2 years) and a lower recurrence rate (8% versus 37% at 2 years) [166]. These interesting results require confirmation in other studies.

3.3.1.2. *RFA*

RFA of HCC is a relatively newly described technique using a probe placed into the tumour mass, usually percutaneously [167–169]. It uses high frequency US to generate heat at the probe tip, which can destroy tissue. A single probe can destroy lesions ≤ 3 cm in diameter and a multiple tipped probe has been used to target lesions ≤ 6 cm in diameter. Larger tumours can be treated by RFA. However, local control reduces significantly when tumour size exceeds 3–4 cm. In a series of 126 HCCs >3 cm in diameter, complete necrosis occurred in 47% [170].

In a single series of 149 tumour nodules with an average tumour diameter of 3.5 cm treated either percutaneously or at open operation, the local recurrence rate at 19 months was 3.6%, with all nodules showing initial complete resolution [171]. However, distant metastasis or a second tumour developed in 46%.

A comparison of 112 patients treated by PEI or RFA showed that 47 of 52 treated by RFA had complete tumour necrosis, with a median of 1.2 treatment sessions, versus 48 of 60 having complete ablation by PEI, with 4.8 sessions required [172]. The authors suggested that RFA was more effective but also had a higher complication rate. Unpublished data suggest a possible higher rate of tumour seeding. Clearly, RCTs of PEI versus RFA are required for further evaluation [87].

3.3.1.3. Cryotherapy

This technique involves freezing the tumour and a 1 cm surrounding margin of healthy tissue [173] using liquid nitrogen delivered by a vacuum insulated cryoprobe, inserted under US guidance or during a laparoscopy or laparotomy. There are limited data available on the efficacy of this therapy; Zhou and Tang reported a 37.9% 5 year survival in 191 treated patients and a 53.1% rate in 56 patients with tumours smaller than 5 cm in diameter [174]. Follow-up treatment with alcohol ablation after cryotherapy may be a useful adjunct in treating residual tumour and controlling recurrences. The major complication is damage to adjacent structures, particularly the portal and hepatic veins. Other reported adverse effects are temperature rise, liver failure, pleural effusion and basal atelectasis [175].

3.3.1.4. TACE

Chemoembolization has been widely used as the primary therapy for inoperable HCC. The literature is difficult to interpret and compare, as the techniques used differ substantially and the patient groups treated are frequently those with advanced disease where the risk of therapy may be greatest. Initial interest in radiological techniques producing tumour devascularization developed in the 1970s [176], with good evidence of their efficacy in reducing tumour size [177], pain and bleeding [178].

Of the six initial RCTs of chemoembolization as primary treatment for HCC [179–184], none showed any increase in survival, although tumour shrinkage was observed. All of these trials predominantly included patients with large tumours and severe underlying liver disease, which may have masked any beneficial effect.

TACE combines intra-arterial chemotherapy with intermittent occlusion of the hepatic artery by embolic material, in order to prolong the contact time between drug and tumour, and to induce massive tumour necrosis by ischaemia. Normal liver tissue is permitted a degree of ‘ischaemic escape’ via portal vein blood flow. Therefore, main portal vein thrombosis is a contraindication to TACE therapy, as are insufficient hepatic reserve, severe clotting abnormalities and significant arteriovenous shunting to the portal/hepatic vein. The use of CO₂ microbubble enhanced sonographic angiography may help reveal tumour vascularity before embarking upon treatment [185, 186].

The embolic material used is often gelatin foam powder or particles. Lipiodol is now less commonly used. These compounds have been used alone in TACE, but the results are limited by tumour type, size and extension. Most trials have combined these embolic materials with chemotherapeutic agents, but as

there is no standard protocol, a large number of combinations have been used. For example, Ryder et al. studied the effect of doxorubicin and lipiodol in 67 unresectable HCCs and reported a 50% reduction in tumour size in 10 of 18 patients with small tumours (<4 cm); 5 of 49 patients with large or multifocal tumours also showed a response to treatment. Survival ranged between 3 days and 4 years, with a median survival of 36 weeks. This study concluded that TACE has promising effects on small tumours but that large tumours show a poor response and a high rate of complications [177].

Despite encouraging figures for small tumours, several RCTs have failed to show a marked improvement in survival with TACE, e.g. 24% 1 year survival for TACE versus 31% with no treatment [180] and 62% for TACE versus 43.5% with no treatment [182]. However, two RCTs have recently confirmed the superiority of repeated TACE or transarterial embolization over supportive or symptomatic care in patients with small tumours and good liver function [186, 187]. These studies established the role of chemoembolization in the palliative treatment of HCC. However, this will only be applicable to a relatively small group of patients (Child–Pugh A without portal vein involvement, ideally with small volume disease, e.g. <10 cm) and results in <10% 5 year survival.

Side effects of chemoembolization are those of the chemotherapeutic agent used (usually doxorubicin), in addition to the complications of arterial embolization, namely pain, fever, hepatic decompensation and, rarely, infarction of organs other than the liver [188]. Serious complications occur in 3–5% of treated patients. In addition, the use of TACE is associated with a ‘post-embolization syndrome’ of fever, pain and vomiting in over 60% of patients [188]. These complications are thought to be secondary to stretching of the liver capsule, pancreatitis, gall bladder infarction, peptic ulceration and necrosis. This is a transient side effect and in most cases can be controlled by non-steroidal anti-inflammatory drugs or hydrocortisone. Less common complications include hepatic failure, liver abscess, arteritis [189] and ruptured HCC [190]. A small number of studies have combined ethanol injection with chemoembolization [191–193].

3.3.1.5. Regional chemotherapy

This technique delivers a chemotherapeutic agent through the hepatic artery via a catheter inserted by laparotomy or angiography. The drug can be given as a single injection [194], a pump driven continuous drip, or using a ‘portacath’ for repeated long term injection. Transarterial chemotherapy is based on the principles that normal hepatic tissue is supplied by both the hepatic artery and portal vein, whereas HCC tumours derive most of their blood supply from the hepatic artery [195].

Compared with systemic chemotherapy, transarterial chemotherapy permits a higher concentration of drug in the tumour tissues using a lower drug dose and lower toxicity [196]. Fluorouracil and anthracyclines (mainly doxorubicin) have been used intra-arterially, the latter producing response rates of up to 42% [197]. Patt et al. reported a 64% response rate using doxorubicin in combination with floxuridine, leucovorin and cisplatin, but with significant toxicity, including deaths [198]. Other drugs used include mitomycin, cisplatin and mitoxantrone, which yielded 50%, 55% and 25% response rates, respectively [199].

3.4. SYSTEMIC THERAPIES

3.4.1. Cytotoxic chemotherapy

Systemic chemotherapy has not been used widely for patients with advanced HCC because HCC has generally been regarded as chemoresistant. This may be due to the high rate of expression of drug resistant genes [200] and underlying liver cirrhosis which reduces the tolerability of systemic chemotherapy.

The efficacy of systemic cytotoxic chemotherapy is modest in HCC, with low response rates and short response durations. Doxorubicin has been the most widely studied cytotoxic, both as a single agent and in combination with other drugs. It has a 10–15% response rate with a high frequency of severe neutropenia [201, 202]. Other chemotherapeutic agents such as epirubicin, cisplatin, 5-FU, and etoposide have also been studied, but with disappointing results [203–205]. Multiple combination regimens have been investigated in the treatment of advanced HCC. However, these have not demonstrated a survival advantage in RCTs. The combination of cisplatin, interferon- α -2b, doxorubicin and fluorouracil showed a significantly higher response rate but no survival benefit compared with doxorubicin alone [206].

Newer chemotherapeutic agents such as gemcitabine, irinotecan, and oxaliplatin have been tested [207–209]. Recent phase II studies using a combination of gemcitabine and oxaliplatin demonstrated modest efficacy and promising toxicity profiles and require further validation [209]. Overall, conventional cytotoxic chemotherapy has not been accepted as standard treatment because of its failure to improve survival in advanced HCC.

3.4.2. Molecular targeted therapy

In recent years, advances in the knowledge of hepatocarcinogenesis have provided an opportunity to treat this chemoresistant tumour with newly

developed molecular targeted agents. Sorafenib is an oral multikinase inhibitor with antiproliferative and antiangiogenic effects that target the Raf/MAPK/ERK signaling pathway and the tyrosine kinase VEGFR-2 and -3 and PDGF receptors [210].

Two pivotal RCTs established sorafenib monotherapy as the new standard systemic therapy for advanced HCC. The multicentre, double blind, European SHARP trial randomly assigned 602 patients with locally advanced HCC, unsuitable for local therapies, to receive sorafenib or placebo. Most patients (82%) were BCLC C; 97% were Child–Pugh A; 38% had macrovascular invasion and 51% had extrahepatic disease [211]. The results showed a significant improvement in both overall survival (median 10.7 months versus 7.9 months) and time to progression (median 5.5 months versus 2.8 months) in the sorafenib arm compared with the placebo arm. Sorafenib was well tolerated with acceptable side effects (8% grade 3/4 diarrhoea, 8% hand–foot syndrome). This represents the first RCT to demonstrate an overall survival benefit of systemic treatment in patients with advanced HCC. A similar sorafenib study of advanced stage HCC patients was conducted in Asia, where there is a high prevalence of HBV [212]. The median overall survival in the sorafenib arm was 6.2 months, which was significantly better than the 4.1 months in the placebo arm. The median time to progression was 2.8 months in the sorafenib group compared with 1.4 months in the placebo group.

In addition to sorafenib, other targeting agents have shown encouraging activity. However, in order to improve survival substantially, more effective combination of local, regional and/or systemic therapies will be needed in patients with advanced HCC.

3.4.3. Hormonal therapy

There is a rationale for the use of hormonal agents such as tamoxifen, as HCC (and cirrhotic liver) tissue contains oestrogen and androgen receptors [131]. Reports on the efficacy of tamoxifen have been conflicting; some studies demonstrated improved survival [213], particularly in females [214], whereas others have shown no impact on survival [215] and no benefit in females [216]. Initial data suggesting a positive effect on survival in patients with inoperable HCC [217] were not confirmed in larger RCTs [218]. In addition to tamoxifen, other agents that have been assessed include flutamide [219], ketoconazole [220] and buserelin [221]. None have impacted significantly on survival. Overall, hormonal therapy currently has no role in the treatment of HCC.

3.4.4. Immunotherapy

Immunologically active agents are theoretically of use in HCC treatment, as interferons are known to play a role in viral reproduction, i.e. hepatitis B/C, and as the activity of lymphokine activated killer cells is often reduced in HCC patients [222]. Immunotherapy has not, however, been demonstrated to achieve any significant impact on patient survival and high incidences of severe complications have been reported. Agents studied include interferon alone [223] and in combination with doxorubicin [224] or fluorouracil [225].

Interferon may have a role in the prevention of HCC in hepatitis C cirrhosis. There is a scientific rationale for this therapy as interferon alpha has a broad range of antitumour activity and is known to be effective therapy for some haematological malignancies. Initial data from both Japan and Europe showed a lower risk of HCC in cohorts of patients with hepatitis C cirrhosis who were given interferon therapy compared with those who were not treated [226]. This effect was irrespective of the antiviral effects of interferon alpha and was observed with a treatment duration of only three months.

However, these studies were not RCTs and had inherent selection bias. As other evidence indicates no effect of interferon on tumour development rates [227], such tumour preventative therapy in patients with cirrhosis should remain investigational within clinical trials. Interferon has been used as treatment for HCC rather than for the underlying viral infection. An RCT using high doses of interferon alpha showed an improved survival [228], but a more recent RCT using more conventional doses of interferon alpha showed no improvement in survival and a high incidence of side effects [229].

Other approaches to prevent tumour development have included retinoids and adaptive immunotherapy. Both of these approaches have been used in the context of prevention of second tumour development after initial tumour resection or ablation. Adaptive immunotherapy, using primed peripheral lymphocytes, showed a significant increase in tumour free survival [230]. Retinoids and compounds involved in the vitamin A metabolic pathway are known to be differentiation inducing agents with hypoproliferative effects. A single study using retinol showed a 20% reduction in second tumour development in patients who had been treated with PEI [231]. Further studies of immunotherapy in HCC are required to validate these interesting results in different patient cohorts.

4. RADIOTHERAPY

4.1. RATIONALE FOR RADIATION THERAPY

The management options for the majority of patients with HCC are limited, using the treatment options discussed in Section 3. The standard local therapies, including resection, transplantation, PEI and RFA, are applicable to <30% of patients with HCC. Similarly, hepatic arterial embolization, either chemoembolization or bland embolization, is suitable for the minority of patients with Child–Pugh A, without major vessel or extrahepatic involvement. Further, the benefits of systemic agents (chemotherapy and biological agents) are modest, with high recurrence rates.

By contrast, the anatomical barriers that may make resection, ablation or embolization less effective do not exist for radiotherapy. Although HCC is a radiosensitive tumour, the relatively low radiation tolerance dose of radiotherapy to the whole liver, as used historically, has promoted the concept that radiotherapy has no role in HCC. However, low doses of radiation can certainly lead to palliation of symptoms from HCC, and there is a substantial and growing body of clinical data supporting the view that radiotherapy can lead to sustained local control, extended survival and pathological complete responses in patients with early and locally advanced HCC.

There are technical challenges in delivering conformal high dose radiotherapy safely to HCC and there is a lack of RCTs of radiotherapy in HCC. As such, radiotherapy has not been recognized as a valuable treatment option for HCC. Thus, there is a pressing need for further studies, including RCTs of radiotherapy in HCC, to demonstrate its value.

4.2. INDICATIONS FOR RADIATION THERAPY

4.2.1. Definitive, high dose radiotherapy

Radiotherapy with curative intent may be used to treat HCC confined to the liver when other treatment options are either unavailable, contraindicated or considered ineffective due to co-morbidities or the size and location of the tumour. A resurgence of interest in the definitive management of HCC with radiotherapy has been generated by a number of factors, including improvements in:

- The ability to deliver tumouricidal doses of radiation;
- Diagnostic imaging and visualization of the tumour;

- Radiotherapy treatment planning software;
- The ability to account for tumour and organ motion at the time of radiation planning and delivery.

The specific indications for high dose radiotherapy include confirmed HCCs confined to the liver, including the presence of satellite nodules. Although there is no absolute limit on the maximum number of intrahepatic tumours that can be treated, the ability to deliver tumouricidal doses decreases and the chance of extensive subclinical disease increases as the number of tumours increases. A maximum of 5 intrahepatic tumour nodules is an arbitrary recommendation for treatment with curative intent.

Tumours fulfilling these criteria generally fall into two categories:

- (1) Smaller tumours of <8 cm in diameter without portal vein thrombosis in patients with medical co-morbidities that preclude surgery, transplantation or ablative therapies. Tumouricidal doses of radiotherapy are indicated, subject to normal tissue tolerances. Dose schedules vary widely and include hyperfractionated (e.g. 70–90 Gy at 1.5 Gy bid), conventionally fractionated (e.g. 66–70 Gy in 33–35 fractions) and hypofractionated regimens (e.g. 50–65 Gy in 20 fractions, 50–66 Gy in 10 fractions, 42–54 Gy in 6 fractions, 50 Gy in 5 fractions and 48 Gy in 4 fractions). Hypofractionated schedules should be used with caution, especially for tumours centrally placed within the liver or in proximity to mucosal structures. The ideal fractionation is not well established. The best results for tumour control are reported with hypofractionation, with the risk of increased toxicity.
- (2) Larger tumours of >8 cm in diameter, which may include portal vein thrombosis, which are ‘focal’ in distribution (such that portions of the liver can be spared from radiation) and are not amenable to surgery or other regional treatments. Typical treatment schedules using photons include 50–60 Gy in 25–30 fractions and 30–42 Gy in 6 fractions, depending on normal tissue tolerance. With larger tumours, hypofractionation is less favoured, again because of the risk of increased bowel and liver toxicity. More aggressive schedules may be feasible with proton or carbon ion therapy.

In addition to these tumour specific and anatomical features, a number of patient specific factors also influence the decision to offer radiotherapy with curative intent. Absolute and relative contraindications are listed in Table 4.

TABLE 4. CONTRAINDICATIONS TO CURATIVE RADIOTHERAPY FOR HCC: PATIENT FACTORS

A Absolute contraindications:
Child–Pugh C
Portal hypertension with gross ascites
Variceal bleeding
Thrombocytopenia ($<30\,000/\text{mm}^3$)
Reduced volume of tumour free liver ($<800\text{ cm}^3$)
Poor performance status ($>\text{Eastern Cooperative Oncology Group 3}$)
Substantial prior abdominal irradiation
Poor liver function (bilirubin $>2 \times$ normal, transaminases $>5 \times$ normal)
B Relative contraindications:
Platelets $30\,000\text{--}70\,000/\text{mm}^3$
Performance status Eastern Cooperative Oncology Group 2
Child–Pugh B cirrhosis
Close proximity of gastrointestinal mucosa ($<1\text{ cm}$ separating the tumour from the nearest mucosa)
Lack of response to prior non-radiation treatment

4.2.2. Palliation with radiotherapy

Simple, low dose radiation therapy may be delivered to any patient with HCC (including Child–Pugh B or C) if they are unsuitable for any other therapy and they have local symptoms from their HCC requiring palliation. Radiotherapy may be used to improve liver related symptoms that may occur due to HCC involving the liver capsule or diffusely infiltrating the liver. Symptoms of pain, discomfort, fever, anorexia or bleeding can be reduced in the majority of HCC patients. Local palliative radiotherapy may also be used following rupture of an HCC nodule (into the peritoneal cavity) to reduce the chance of further rupture and for symptoms of biliary obstruction (although biliary stenting is preferable for palliation if possible).

The ability of radiotherapy to reduce symptoms from liver metastases has been documented, but not specifically for symptomatic, locally advanced HCC. In a trial of symptomatic liver metastases, Leibel et al. prospectively studied 187 patients treated with whole liver radiotherapy to a dose of 21 Gy in 7 fractions; abdominal pain was improved in 80% of patients [232]. There is a

paucity of literature on the palliative benefits of whole liver radiation, so the most appropriate fractionation is not well defined. Possible palliative dose fractionations include 8 Gy in 1 fraction, 10 Gy in 2 fractions, 16 Gy in 4 fractions and 21 Gy in 7 fractions. In a prospective Trans-Tasman Radiation Oncology Group study using 10 Gy in 2 fractions to the whole liver, symptoms were reduced in 54% of cases [233]. Simple beam arrangements (parallel opposed fields) are appropriate for whole liver radiotherapy, with pre-medication with steroids and antiemetics.

In the presence of portal vein thrombosis, a variety of fractionation schedules have been used (up to 50 Gy in 20 fractions), with or without chemotherapy. Inclusion of the tumour thrombus and the primary HCC in the treatment volume is recommended if possible. However, if the main symptoms or life threatening problem is due to the portal vein thrombus and inclusion of the primary HCC is not possible, treatment of the portal vein thrombus only is indicated. Recanalization occurs in approximately 50% of cases over 3–6 months (though the time to maximum recanalization and response may exceed a year).

Symptoms due to HCC metastases to bone [234, 235], brain [236], lymph nodes [237, 238] and other sites [237] can also be alleviated by palliative radiotherapy. Pain relief from bone metastases was observed in 73–83% of patients in two of the largest series [234, 235]. A variety of palliative schedules can be used, depending on the volume of normal tissue to be treated and life expectancy.

4.2.3. Radiotherapy combined with other therapies

Radiotherapy alone can be an effective modality for small tumours. However, in treating locally advanced tumours, radiation doses are limited by liver tolerance, particularly for patients with cirrhosis. In Asia, where TACE has been a major non-surgical option, radiotherapy has been introduced to improve the high rates of progression after TACE. In fact, the characteristic features of HCC, which involve vascular shunting, recanalization around the tumour capsule and development of multiple feeding vessels, have limited the efficacy of TACE [239, 240].

Previously, only the patients referred for consideration of radiotherapy were those with poor liver function contraindicating resection, tumours unresponsive to TACE and locally advanced disease not suitable for TACE.

Seong et al. used radiotherapy following incomplete responses to TACE, with response rates greater than 60% [241]. Of 73 patients with HCC and an incomplete response to TACE, 38 were treated with radiotherapy and 35 with repeat TACE. A statistically significant improvement in survival was observed in patients treated with radiotherapy (2 year survival rate 37% with radiotherapy

versus 14% with repeated TACE, $p = 0.001$). The survival difference was greatest for larger tumours, with 2 year survival rates of 63% versus 42% in 5–7 cm tumours, 50% versus 0% in 8–10 cm tumours and 17% versus 0% in tumours larger than 10 cm, for treatment with radiotherapy and TACE, respectively [241]. A similar range of response rates with TACE followed by radiotherapy has been reported by other investigators [242–245]. While this strategy improves local control within the irradiated volume, the pattern of recurrence continues to be intrahepatic (outside the treatment volume) and/or extrahepatic metastasis. Following chemotherapy, a washout period of at least two weeks is customary prior to starting radiotherapy. It remains unclear whether there is any benefit to concurrent chemoradiation; nevertheless, the use of fluoropyrimidines may be considered.

Radiotherapy has also been combined with concurrent transarterial chemotherapy. This combination has improved survival in patients with main portal vein tumour thrombosis. Han et al. [246] reported promising survival results of conformal radiotherapy combined with hepatic arterial chemotherapy in 40 patients with locally advanced HCC with portal vein tumour thrombosis. The 3 year overall survival rate was 24.1% and the median survival time was 13.1 months, which was a marked improvement compared with the previously reported survivals of 4–6 months [211]. The same group updated the treatment outcomes in 101 patients who had a median survival of 16.7 months [247].

Since 1987, investigators at the University of Michigan have dose escalated conformal hyperfractionated radiotherapy (1.5 Gy twice daily over 6–8 weeks), with concurrent hepatic arterial floxuridine in serial phase I/II studies of unresectable HCC. In this approach, the prescribed dose was based on the volume of liver irradiated, with no upper limit on size of HCC that may be irradiated. In 1997, the outcomes of 20 patients with HCC treated with this approach were reported; the median survival was 16 months and the 4 year survival rate was 20% [248]. In the latest phase II study, a median survival of 15.2 months was observed in 25 HCC patients treated with doses as high as 90 Gy [249].

In a Japanese series of 121 patients with HCC treated with hyperfractionated radiotherapy (1.5 Gy bid, total dose 45–75 Gy) combined with thalidomide, the 1 and 2 year survivals were 60% and 45%, respectively. Multivariate analysis found that portal vein thrombosis and the AFP level were significantly associated with survival [250].

4.2.4. Bridge to transplantation

There is limited experience in using radiotherapy as a bridge to liver transplantation [251]. Since the waiting list for transplantation is long and many standard therapies are not suitable in patients with poor liver function,

radiotherapy may have a role in this patient group. Pathological complete responses have been reported and the safety of radiation in this setting is becoming established. Most often, the majority of the liver (which is usually Child–Pugh B or C) is spared from the high radiation dose. The majority of experience with radiotherapy as a bridge to transplantation is with protons [251], but photon therapy using conformal radiotherapy or intensity-modulated radiation therapy (delivered in 6 fractions) has also been used without significant toxicity in this setting (unpublished, L. Dawson, Princess Margaret Hospital, Toronto, March 2009). It is recommended that the local standard radiotherapy protocol be used as a bridge to transplantation, ideally in the context of a clinical study, since experience is scarce. Centres without a local standard radiation fractionation schedule or a policy for HCC should consider offering radiotherapy only within a clinical trial, owing to the risk of radiotherapy induced liver toxicity.

4.3. TYPES OF RADIATION THERAPY

There is a range of strategies that may be used to deliver radiotherapy to HCCs. Although several strategies are reviewed in this section, the emphasis will be on external beam photon treatment.

4.3.1. Brachytherapy

Interstitial and intraluminal brachytherapy have been used to treat liver metastases and cholangiocarcinoma [252]. However, there is far less experience in HCC, possibly due to the potential for tumour seeding and the increased risk of intrahepatic haemorrhage in patients with underlying cirrhosis. Intraluminal ^{192}Ir has been used occasionally for intraductal HCC and following incomplete resection [253, 254]. Overall, the role of brachytherapy in HCC is very limited.

4.3.2. Radioisotopes

Regional radionuclide therapeutic options are increasingly available for HCC patients, with encouraging results. However, these methods have not displaced external beam radiotherapy as the main radiotherapeutic technique. The three ways by which radioisotopes are delivered to HCC are ^{90}Y , ^{131}I –lipiodol and labelled antibodies.

4.3.2.1. ^{90}Y

Yttrium-90 is a pure β emitter that decays with a physical half life of 2.7 d. The β rays from ^{90}Y embedded in glass microspheres have an average penetration of 2.5 mm and a maximum penetration of 11 mm in tissue. Intratumoural injection of ^{90}Y glass microspheres under US guidance was used by Tian et al. as a means to administer local radiotherapy [255]. Yttrium-90 may be delivered to HCCs by segmental, subsegmental, regional, or global hepatic arterial infusion via an appropriately placed hepatic arterial catheter.

Safety trials in HCC have demonstrated that doses of up to 100 Gy can be safely administered focally [256–259]. A subsequent phase II trial with a planned dose of 100 Gy suggested a dose–response relationship and a survival benefit among patients receiving a dose >104 Gy [260]. Not unexpectedly, the survival durations are longer in patients with better liver function and earlier stages of disease [261]. In a recent analysis of toxicity, Goin et al. documented an 18% 90 d mortality following this procedure [262, 263]. Patients were stratified into high and low risk cohorts based on the presence or absence of seven pretreatment and treatment variables. The significantly higher 90 d mortality (49% versus 7%) and significantly lower median survival (108 d versus 466 d) in high risk compared with low risk patients led the authors to conclude that the use of ^{90}Y microspheres should be limited to low risk patients [263].

Yttrium-90 has also been tagged to resin microspheres. Most of the clinical experience in unresectable HCC comes from Hong Kong where the microspheres were delivered intraoperatively [264]. Patients receiving <120 Gy had fewer responses and a lower median survival (26 versus 56 weeks). A larger trial of 71 patients who were administered an estimated median tumour dose of 225 Gy confirmed a 27% partial response rate and complete pathological response in 2 of 4 patients who underwent subsequent resection [265]. Treatment was well tolerated and the median survival was 9.4 months. To date, this procedure is not Federal Drug Administration approved for treatment of HCC.

4.3.2.2. ^{131}I -lipiodol

Another form of administering regional radiotherapy is injection of ^{131}I -lipiodol via the hepatic artery. Similar to TACE, the lipiodol is selectively retained and concentrated within the tumour and the ^{131}I delivers internal radiation. Iodine-131 decays with a half-life of 8 d by β emission, but also produces γ rays which can be used for scintigraphy. However, accurate dosimetry remains a challenge with these treatments [266].

Two RCTs have been conducted in France by Raoul et al. In the first, 27 patients ineligible for TACE due to presence of a portal venous tumour

thrombus were randomized to intrahepatic artery injection of ^{131}I -lipiodol versus supportive care [267]. Treatment was tolerated well and a significant improvement in 6 month overall survival was noted for the ^{131}I -lipiodol group (48% versus 0%, $p < 0.01$). In the subsequent trial, 129 unresectable HCC patients were randomized to TACE versus ^{131}I -lipiodol [268]. There was no significant difference in overall survival and ^{131}I -lipiodol therapy was better tolerated clinically.

4.3.2.3. *Labelled antibodies*

The final mode of administering radionuclides is systemic infusion of radiolabelled antibodies. Early attempts at using monoclonal ^{131}I -anti-ferritin antibody were not successful, as outcomes were no better than with chemotherapy [269]. More recently, monoclonal antibodies against putative HCC specific antigens have been conjugated to ^{131}I (including Hepama-1, isoferitin, AFP and carcinoembryonic antigen) [270]. However, tumour specificity and tumour retention remain ongoing challenges in radioimmunotherapy.

4.3.3. **Photons**

4.3.3.1. *Conformal radiotherapy*

As the external beam dose that may be delivered safely to the *whole liver* is less than 30 Gy over three weeks, the benefits of whole liver irradiation are palliative, predominantly to reduce symptoms such as pain. Advances in CT based radiation planning have permitted high doses of radiation to conform to the HCC target volume tightly, allowing the volume of uninvolved liver spared from radiotherapy to be quantified, providing improved understanding of partial volume tolerance.

In the French radiotherapy F1 prospective phase II trial of conformal radiotherapy, a response rate of 92% was observed in 27 cirrhotic patients with small HCCs (single nodule ≤ 5 cm, or 2 nodules ≤ 3 cm) treated with 66 Gy in 33 fractions [271]. Two grade 4 toxicities occurred in 11 Child–Pugh B patients with pre-existing grade 3 abnormalities. Others have observed similar outcomes following conformal radiation, with increased local control and survival associated with higher doses [272].

The greatest experience with radiotherapy for HCC is from Asia, where a variety of fractionation schemes with conformal radiation techniques have been used. Seong et al. from the Republic of Korea reviewed their data for 1992–2003 to evaluate which staging system was most appropriate for Child–Pugh A patients with HCC treated with radiotherapy. They found that the TNM staging system

was the best predictor of treatment outcomes in patients with Child–Pugh A liver cirrhosis and HCC [111]. They also reported the largest series of radiotherapy outcomes [273]. Using a multicentre retrospective cohort study, they analysed 398 HCC patients treated with conformal radiotherapy (326 patients) or radiosurgery (72 patients) from 10 major cancer referral centres. The 2 year overall survival and the median survival time were 27.7% and 12 months, respectively. In multivariate analysis, tumour size of <5 cm, absence of lymph node metastasis and a radiation dose of >53.1 Gy₁₀ (biologically equivalent dose) were independent factors predicting improved outcome.

In summary, following a variety of dose and fractionation schedules, 1 year survival rates range from 50–95% and 5 year survival rates range from 9 to 25% following 40–60 Gy delivered over 1–5 weeks [274–278]. The reasons for the large range of outcomes include substantial heterogeneity in patient selection (Child–Pugh A and B), treatment intent and treatment delivered. Some series report on outcomes for liver confined disease, whilst others report on tumours with portal vein thrombus or regional metastases treated with palliative intent.

4.3.3.2. Stereotactic body radiation therapy (SBRT)

SBRT refers to the use of high dose radiotherapy delivered in far fewer radiation fractions (e.g. 1–10 fractions) compared with conventional radiotherapy. The use of improved imaging for tumour delineation, CT based conformal planning, breathing motion management and image guided radiation therapy allow high radiation doses to be delivered to focal HCCs with relative safety. As dose gradients are steeper and doses are higher with SBRT than conventional radiotherapy, the consequences of error in tumour delineation, errors introduced by dosimetry and geometric uncertainties may be more serious than following conventional radiotherapy. Thus, all aspects of treatment planning that are important in conformal radiation planning are even more crucial in SBRT, especially for tumours in close proximity to critical normal tissues, where a systematic error could lead to permanent serious toxicity if sensitive normal tissue is unexpectedly subjected to the high doses planned for the tumour. Special quality assurance procedures are required prior to SBRT and it has been recommended that radiation delivery equipment should have mechanical tolerances accurate to ± 2 mm.

Blomgren et al. first reported on the use of SBRT for HCC in 1995 [279]. Patients with HCC and hepatic metastases were treated with 15–45 Gy in 1–5 fractions, with frequent objective responses. Wulf et al. treated 5 patients with HCC and 39 patients with liver metastases using SBRT, with no limit on tumour size if no more than 50% and 30% of the liver received 5 Gy and 7 Gy respectively. No local recurrences or toxicity were seen in the 5 HCC patients

[280]. Mendez Romero et al. treated 8 Child–Pugh A or B patients with 11 HCCs with 25 Gy in 5 fractions, 30 Gy in 3 fractions or 37.5 Gy in 3 fractions over 5–10 d. The maximum tumour diameter was 7 cm. Two HCC patients treated with 25 Gy in 5 fractions recurred locally at 4 and 7 months and were re-treated with 24 Gy in 3 fractions. The crude local control rate for HCC was 82% and the 1 and 2 year actuarial survival rates were 75% and 40%, respectively. One patient (Child–Pugh B) developed grade 5 toxicity due to liver failure and infection [281].

One series of hypofractionated conformal radiotherapy (similar to SBRT) has been reported in which 98 patients with HCC received 48–63 Gy in 6–9 fractions over 12–18 d. Most (94%) showed tumour remission 6 months post-treatment. From 48 patients with malignant portal vein thrombosis, there was reduction in the size of the thrombus in 31 (65.6%) and significant reduction in AFP levels ($p = 0.015$). Among the stage III patients, the 1 year survival rate was 68% and the 2 and 3 year survival rates were 41% and 35%, respectively [282].

In Toronto, a phase I study of a 6 fraction SBRT schedule in 31 HCC patients (52% with portal vein thrombosis) refractory to, or unsuitable for, standard therapies was reported. The median tumour volume was 173 cm³ (9–1913 cm³). The median dose was 36 Gy in 6 fractions (24–54 Gy). No classic radiation induced liver disease (RILD) was observed, but five patients had a decline in Child–Pugh score 3 months following radiotherapy (3 with progressive disease). The 12 month local control rate was 65%. The overall median survival was 11.7 months and the median survival of patients without portal vein thrombosis was 17.2 months [283].

4.3.3.3. *Proton and heavy ion therapy*

Proton and heavy ion therapy exploits the unique characteristics of charged particle beams to deposit most of their energy at the end of their range (the Bragg peak effect), with steep dose gradients after the fall-off. In addition, charged particle radiotherapy has sharp lateral margins and a slightly greater biologically effective dose than photons. A modulated (spread out) Bragg peak is used to encompass the target volume completely.

Most experience gained with proton radiotherapy for HCC is from Tsukuba, Japan, where Chiba et al. treated 162 patients (192 HCCs) with proton beam therapy with or without transarterial chemotherapy or PEI [284]. The median dose of 72 Gy in 16 fractions over 29 d was well tolerated. The 5 year local control rate was 87% and the 5 year overall survival was 23.5%. Among a subset of 50 patients with solitary tumours and Child–Pugh A, the 5 year survival rate

was 53.5%. Outcomes were also good in patients with portal venous thrombosis [285] and impaired liver function [286, 287].

Further prospective studies from Tsukuba have confirmed these impressive outcomes [288]. Most recently, in a prospective study of 51 patients (20% Child–Pugh B), proton therapy was used to deliver 66 Gy equivalent in 10 fractions to patients with 1–3 tumour nodules (≤ 10 cm). Five year local control and survival rates were 88% and 39%, respectively. In Child–Pugh A patients with solitary tumours, 5 year survival was 46%, similar to the results of surgery. Liver function remained stable or improved in 84%, with no RILD. Late rib fractures were seen in 3 patients, indicating that ribs may be a novel sensitive tissue for late radiation damage. No other serious late toxicities were observed. Patients with tumours near the gastrointestinal tract or porta hepatis were ineligible for this hypofractionated protocol, which is used to reduce the risk of mucosal and biliary toxicities that may occur following high doses per fraction. This paper adds to the growing literature demonstrating the efficacy of radiotherapy in HCC.

Bush et al. reported the results of a phase II trial of 34 patients treated with 63 cobalt Gray equivalent in 15 fractions over 3 weeks. Two year local control and overall survival rates were 75% and 55%, respectively [251]. Gastrointestinal bleeding occurred in 9% owing to the proximity of the tumour to the bowel. More recently, Kawashima et al. reported a 66% overall 2 year survival in 30 patients treated on a phase II protocol with 72 cobalt Gray equivalent in 20 fractions over 5 weeks, without gastrointestinal or pulmonary toxicity greater than grade 1 [289].

Kato et al. treated 24 patients in the first phase I/II protocol of carbon ions. The treatment dose was 49.5–79.5 Gray equivalent in 15 fractions over 5 weeks with step-wise escalation of dose per fraction. The 5 year local control was 81% and 5 year overall survival was 25%. The only reported grade 3 toxicity was radiation dermatitis [290].

4.4. TECHNICAL ASPECTS OF HIGH DOSE EXTERNAL BEAM RADIOTHERAPY

As stated above, the ability to deliver high dose radiotherapy, using any of the advanced technologies already discussed, is dependent on modern imaging, planning and treatment methods. These include methods that reduce, or account for, the considerable normal movement of the liver and other normal dose limiting structures. As most of these advanced radiotherapy technologies are applied in the treatment of many disease sites, including the liver, a brief description has been included in Annex II.

4.5. RADIOTHERAPY TOXICITY

4.5.1. Hepatic toxicity

4.5.1.1. RILD

Early studies of whole abdominal irradiation demonstrated that irradiation of the liver produced signs and symptoms of liver disease within three months of treatment in approximately one third of patients [291–293]. This form of subacute liver injury has been termed RILD [294]. Irradiated patients recorded rapid weight gain, increase in abdominal girth, enlargement of the liver (often with tenderness) and occasionally jaundice [292]. This clinical picture resembled veno-occlusive disease (as observed in the Budd–Chiari syndrome or after conditioning regimens used for bone marrow transplantation) and the typical laboratory abnormality was a marked elevation in ALP, with less frequent transaminitis [292]. While most patients recovered, deaths were recorded. The pathological hallmarks of this injury included marked congestion, hyperemia, haemorrhage of the central portion of the lobules and atrophy of the hepatocytes surrounding the central vein with minimal congestion of the portal triad [293]. The central venous congestion extended to the sublobular veins (between the central vein and the hepatic vein) but not the hepatic vein [294, 295]. Later in the subacute course of RILD, small portal vein branches became obstructed due to collagen deposition [295]. The lack of a predominantly inflammatory component to this injury led to the choice of nomenclature as ‘RILD’ rather than ‘radiation hepatitis’.

To confirm RILD rather than disease progression, it is usual to obtain a CT scan and to perform a paracentesis. The CT scan may demonstrate a band of decreased density of liver parenchyma corresponding to the radiation portals, especially following proton therapy, but may be less apparent with the use of multiple beams or intensity-modulated radiation therapy [294, 296, 297]. The low attenuation area on non-contrast CT scans may show enhancement with dynamic contrast studies [297].

There are no established therapies for subacute RILD. Over the course of 1–2 months, most patients respond to conservative measures such as diuretics (spironolactone), vitamin K for coagulopathy, and repeated paracenteses. A minority of patients develop jaundice (markedly elevated bilirubin, alkaline phosphatase and prothrombin time with moderately elevated transaminases), progressive ascites refractory to paracentesis and diuretics, and coagulopathies. Although some of these patients may recover, a substantial proportion will die of liver failure [294].

At radiation doses inadequate for tumour eradication, whole liver radiation with doses as low as 28 Gy delivered over 3 weeks carry a risk of RILD of >5%. With conventional fractionation, the mean liver (minus gross tumour volume) dose should be <18 Gy to minimize toxicity. A summary of liver radiotherapy tolerances from the literature is shown in Table 5. Partial liver irradiation permits dose escalation to tumours while sparing surrounding normal liver; this concept has been responsible for resurgence in the role of radiotherapy in unresectable HCC.

Liver tolerance depends on the radiation dose, the proportion of liver that is irradiated, the pretreatment functional capacity of the liver and the use of concurrent chemotherapy. Also, hepatic toxicity following radiotherapy combined with chemotherapy is influenced by the organ distribution of the chemotherapeutic drugs [298]. Pre-irradiation estimates of liver radiation tolerance are difficult when liver function is damaged or when the total liver volume has been reduced by cancer, chemotherapy, or previous disease. No accurate assessment of liver reserve exists, although liver function tests coupled with CT or isotope scanning, angiography and US are helpful. One method that has been employed by surgical groups, mostly in Japan, has been to determine the functional capacity of the liver using an indocyanine-green retention test [299, 300]. Another method that provides functional and anatomical data is ^{99m}Tc galactosyl serum albumin scintigraphy, which gives volumetric data as well as kinetic distribution curves [301].

Table 6 shows the recommended radiation dose–volume to normal liver and total liver. All dose limits are kept as low as possible, especially if hepatitis B carrier or Child–Pugh B.

4.5.1.2. Non-RILD hepatic toxicity

Another liver related acute toxicity observed in HCC patients treated with focal radiotherapy is reactivation of viral hepatitis and precipitation of underlying liver disease [302, 303]. Treatment of active hepatitis B is always recommended before irradiation, if possible. The radiation tolerance of the liver in hepatitis B patients in Taiwan, China, with HCC is lower than for hepatitis B HCC patients in North America. In patients from Taiwan, China, the risk of liver toxicity is very low if the mean liver dose is kept <18 Gy in 20–35 fractions [304].

A common complication in patients with portal hypertension and splenomegaly, or baseline liver dysfunction, is the increased risk of coagulopathies due to decreased platelet count or function and/or elevated prothrombin time. As these patients are at risk of bleeding (often from stomach and duodenal mucosae within the treatment field), prophylactic treatment with proton pump inhibitors and discontinuing radiotherapy at platelet counts <50 000/mm³ is advised.

TABLE 5. SUMMARY OF LIVER RADIOTHERAPY TOLERANCES FROM LITERATURE REVIEW

Study group	N	Diagnosis	Baseline Child–Pugh score	Radiotherapy dose per fraction	Crude % RILD	MDTNL in patients with and (without) RILD	Factors associated with RILD
Michigan (Dawson)	203 ^a	PLC+LM	203 A	1.5 Gy bid	9.4% (19/203)	37 Gy (31.3 Gy)	PLC versus LM mean liver dose
Taipei (Cheng)	89 ^b	HCC	68 A 21 B	1.8–3.0 Gy	19% (17/89)	23 Gy (19 Gy)	HBV, cirrhosis
Shanghai (Liang)	109 ^b	PLC	93 A 16 B	4–6 Gy	15.6% (17/109)	24.9 Gy (19.9 Gy)	Cirrhosis
Guangdong (Wu, Xu)	94 ^b	HCC	43 A 51 B	4–8 Gy	17% (16/94) (4 fatal)	Not stated	Cirrhosis
Republic of Korea (Seong, Park)	158 ^b	HCC	117 A 41 B	1.8 Gy	7% (11/158)	Not stated	Dose
Republic of Korea (Kim)	105 ^b	HCC	85 A 20 B	2.0 Gy	12.3% (13/105)	25.4 Gy (19.1 Gy)	Total liver volume >30 Gy exceeds 60%

^a Patients also received Fluorouracil deoxyribose or bromouracil deoxyribose. The MDTNL was calculated as corrected for 1.5 Gy bid equivalent dose. Comparison of patients with versus without RILD refers to the median value of the MDTNL, whereas for other series the comparison is between the averages (mean) of the MDTNL in each group.

^b At least 77% of patients in these series also received TACE.

PLC: primary liver cancer (including HCC and intrahepatic cholangiocarcinoma); LM: liver metastases; MDTNL: mean dose to normal liver.

TABLE 6. RECOMMENDED RADIATION DOSE–VOLUMES TO NORMAL LIVER AND TOTAL LIVER

Organs at risk	Constraint		
Normal liver	1. $V_{50\%}$ (50% of the isocentre dose) [271, 305, 306])		
		$V_{50\%}$ (%)	Total dose (Gy)
	University of Michigan guideline	<33	Up to 93 ^a
		33–66	Up to 47 ^a
		>66	Up to 32 ^a
	Yonsei University guideline	<25	59.4 or more
		25–49	45–54
		50–75	30.6–45
		>75	No treatment
	2. Normal tissue complication probability model [294, 307–309]		
	5% risk of RILD (TD ₅)		
1/3 liver 43–93 ^a Gy	2/3 liver 34–47 Gy	Whole liver 30–35 Gy	
50% risk of RILD (TD ₅₀)			
39.8–49.4 Child–Pugh A: 40.5–48.9 Gy Child–Pugh B: 23–38.7 Gy			
3. MDTNL [309–311] MDTNL for whole patients: <28 Gy in conventional 2 Gy per fraction <18 Gy in 6 fractions Child–Pugh A: 21 Gy; Child–Pugh B: 6 Gy			
4. Non-tumour liver volume >800 cm ³			
Total liver including target volume	No more than 60% of normal liver receives over 30 Gy (V ₃₀ <40–60%) [312]		
All dose limits are kept as low as possible, especially if hepatitis B carrier or Child–Pugh B			

^a 1.5 Gy twice daily.

4.6. GASTROINTESTINAL MUCOSAL TOXICITY

Other critical structures that may be included in high dose treatment volumes for HCC include the oesophagus, stomach, duodenum, small intestine and large intestine. If portions of these tissues are irradiated beyond threshold doses (approximately 45 Gy in 1.8 Gy per fraction or 30 Gy in 6 fractions), acute oesophagitis, gastritis, duodenitis, or colitis may occur 1–3 months following

irradiation. The discomfort from these self-limited, acute reactions is generally a response to antacids, topical analgesics (e.g. viscous lidocaine) or proton pump inhibitors. Other acute reactions may include nausea (if the stomach is irradiated), anorexia, diarrhoea or abdominal cramps.

Acute variceal bleeding may occur in cirrhotic patients and is more common in patients with prior variceal bleeds, baseline portal hypertension and treatment with higher doses per fraction. Optimization of liver function and banding of varices prior to irradiation may reduce the risk.

Late gastrointestinal mucosal complications may occur if doses exceeding 50 Gy in 1.8 Gy per fraction (or 30 Gy in 6 fractions) are delivered to portions of the gastrointestinal tract. These late toxicities include bleeding, ulcer formation, chronic gastritis, bowel obstruction and fistula formation. Although not proven to reduce bleeding or ulcer formation, H₂ receptor blockers or proton pump inhibitor medications are often used in patients if high doses are delivered to the gastrointestinal tract.

Late gastrointestinal bleeding occurred in 5% of patients treated with conformal radiotherapy for HCC or hepatic metastases with 1.2 Gy twice daily [249]. When external beam radiation is combined with intraluminal ¹⁹²Ir brachytherapy, focal regions of the duodenum may receive high doses and the risk of gastrointestinal bleeding is increased. Bleeding has been reported to occur in 25–30% of patients with biliary malignancies treated with external irradiation plus intraluminal ¹⁹²Ir. Mogavero et al. reported gastric and duodenal obstruction in 7 of 63 patients who underwent radiotherapy for hilar cholangiocarcinoma, although some of these symptoms may have been due to the tumour in addition to radiation fibrosis [313].

4.6.1. Biliary toxicity

Kopelson et al. reported asymptomatic, non-obstructing biliary fibrosis after 60 Gy of external irradiation [314]. Biliary fibrosis is often amenable to endoscopic or percutaneous transhepatic bile duct stenting. However, as bile duct stenting combined with radiotherapy may increase the incidence of stent related infection, prophylactic stenting is not recommended [315, 316].

Relevant to HCC are the reports of biliary toxicity in long term HCC survivors treated with radiotherapy. Chiba et al. reported 5 late complications following 185 proton treatment courses in 162 patients. These included one case of common bile duct stenosis and two cases of infection bilomas [284].

4.6.2. Other radiotherapy related toxicities

The constitutional symptoms of fatigue, anorexia, fever and asymptomatic bone marrow suppression are common, but usually mild and transient. Depending on the fractionation used, grade 1–2 fatigue may start during therapy and usually passes within a few months following radiotherapy. Occasionally, substantial fatigue may last >2 months, sometimes associated with hypoalbuminemia or a reduction in liver function.

Thrombocytopenia is the most common haematological toxicity and is related to the presence of portal hypertension and splenomegaly in cirrhotic patients. Thrombocytopenia is also more likely in patients who have been heavily pretreated with chemotherapy or where TACE is used with radiotherapy. Substantial declines in the platelet count are unusual following radiotherapy alone.

Depending on the location of the HCC, other normal tissues, including the kidneys, spinal cord, heart and lungs, should be considered at the time of radiotherapy planning, to reduce the risk of toxicity. Similar to the liver, partial organ radiographic changes may be seen following high dose radiotherapy to the kidneys (on renal scans) and/or the base of the lungs (ground glass changes in the lung parenchyma). These acute changes may develop into fibrosis, but would constitute a clinically important decline in organ function only if a substantial portion of the organ were irradiated.

Another less common subacute side effect from radiotherapy is pleuritic pain that is usually transient, but which can mimic pulmonary embolus. This is more common following SBRT. This usually resolves within 4 months following radiotherapy and may be due to lower lung irradiation. Rib fractures are another toxicity that may occur following high dose radiotherapy, more likely following SBRT or hypofractionated proton therapy.

5. FUTURE DIRECTIONS

5.1. INTRODUCTION

The tumour status and hepatic functional reserve are equally important as major determinants of treatment selection and prognosis. Although potentially curative therapies are well established for HCC, these are only applicable to 20–30% of patients. Also, resection is accompanied by high recurrence rates and transplantation has limitations. TACE, the most common non-surgical alternative, and other ablative therapies, including PEI and RFA, are effective only in limited instances. HCC is also resistant to current systemic chemotherapeutic regimens. Even sorafenib, the first systemic drug to show statistically improved survival in a RCT may not find widespread use, owing to the small absolute gain in survival and its high cost.

There is, therefore, an urgent need both to define other effective therapies and to systematize the use of existing therapies, including radiotherapy. As indicated in Chapter 4 and Annex II, there have been major advances in radiation treatment planning and delivery during the past decade, providing a capability for effective treatment of HCC. However, radiotherapy has not been incorporated into many management guidelines, and the optimal fractionation for HCC has yet to be determined.

5.2. EXISTING TREATMENT GUIDELINES FOR HCC

On the basis of the encouraging reports showing the efficacy of radiotherapy, delivered in a variety of techniques, it is of interest to review the extent to which radiotherapy is incorporated into existing guidelines for the management of HCC (Table 7).

Table 7 indicates that radiotherapy is *not* included as a treatment option in several guidelines. Some relevant aspects of these guidelines are:

- The NCCN practice guideline (version.2.2008, www.nccn.org) is a consensus statement regarding current approaches to management. There is level 2A evidence that radiotherapy is an alternative therapeutic option to transplantation for patients with unresectable disease, or for those who decline surgery. This is supported by the uniform NCCN consensus on the appropriateness of this recommendation.

TABLE 7. PUBLISHED GUIDELINES FOR THE MANAGEMENT OF HCC

Year	Guideline for HCC management	Radiotherapy in guideline
2001	Barcelona–European Association for the Study of the Liver consensus	No
2003	Korean Liver Cancer Study Group (KLCSG) guideline	Yes
2005	AASLD guideline	No ^a
2005	Japan guideline for evidence based clinical practice	No ^b
2007	Japan Society of Hepatology guideline (consensus based clinical practice manual)	No
2008	United States National Comprehensive Cancer Network (NCCN) guideline	Yes
2009	Taiwan, China, national guideline	Yes

^a Non-curative treatment. There are multiple other treatment modalities such as octreotide, interferon, external radiation, tamoxifen, or anti-androgenic therapy, but none have been shown to improve survival.

^b For Child–Pugh C cases with vascular invasion or an extrahepatic lesion, palliative care is the basic treatment, including radiotherapy aimed at pain relief.

- In the KLCSG practice guideline for diagnosis and treatment of HCC [317], radiotherapy is considered for surgically unresectable, locally advanced tumours without extrahepatic metastasis, Child–Pugh A or B, and tumours occupying less than two thirds of the liver. The KLCSG guideline describes the use of radiotherapy as level III evidence (clinical experience, descriptive studies, or expert committee reports) according to the AASLD definition.
- The AASLD practice guideline for the management of HCC contains an evidence-based treatment strategy for HCC patients based on fewer than one hundred RCTs [118]. Patients are stratified by BCLC stage, with a suggested treatment for each stage. Patients diagnosed at an early HCC stage are optimal candidates for resection, liver transplantation or percutaneous ablation. If these options are not feasible, patients are considered for palliation.

5.3. TREATMENT OF HCC: THE RADIATION ONCOLOGIST’S PERSPECTIVE

There has been increasing interest in the role of radiotherapy in the treatment of HCC over the past few years, as indicated by the results of a PubMed search (Fig. 1). This shows an exponential growth in the number of publications over the past 15 years, in all aspects of radiotherapy for liver cancers. Therefore, it is timely to reassess the role of radiotherapy in HCC.

From the radiation oncologist’s viewpoint, radiotherapy may be used as the definitive therapy with curative intent in early stage tumours. The best outcomes have been reported following proton or carbon therapy, but high dose photon therapy is also potentially curative. Radiotherapy may also be used in combination with TACE, or in patients not suitable for TACE for intermediate stage tumours. In locally advanced tumours, radiotherapy may be used in combination with systemic agents (on trials only), or alone in patients with portal vein thrombosis not suitable for other therapies. Technical advances in the use of radiotherapy allow more precise delivery of radiation, permitting higher doses to the tumour and reduced doses to surrounding normal tissues. As HCC usually arises in already compromised livers, these modern technologies are a prerequisite for local control and possible cure.

Radioisotopes are also available as a treatment option. The selection of patients for external beam radiotherapy versus radioisotope therapy is not well

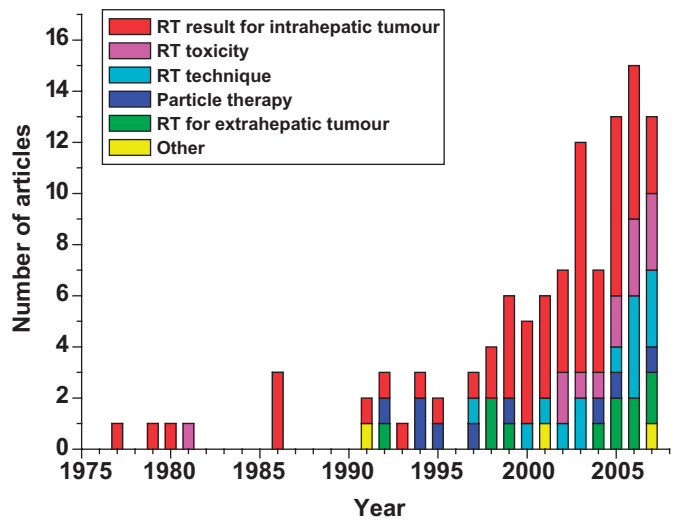


FIG. 1. Increasing frequency of publications on radiotherapy for liver cancer (source: PubMed).

defined. In general, radioisotopes may be considered for multifocal diffuse intrahepatic HCC, where conformal radiotherapy is not an option. However, many questions remain unanswered and many of the comparative clinical trials between different treatment methods and modalities have not been undertaken.

Patients with advanced stage and deteriorating condition should be managed palliatively. For control of local or distant symptoms, short fractionation schedules (e.g. 5–8 Gy in a single fraction, 20 Gy in 4 fractions) are recommended, since survival is generally short.

5.4. UNRESOLVED ISSUES

5.4.1. Dose escalation studies using radiotherapy as a single modality

A number of studies demonstrate a radiation dose response relationship for HCC. Higher doses improve tumour response at the expense of greater toxicity. With better understanding of partial liver irradiation, delivery of very high doses should be possible using conventional or hypofractionated radiotherapy if <25% of the effective liver volume is irradiated. With this proviso, radiotherapy with high doses can achieve substantial tumour response in selected patients. However, the availability of dose/volume statistics from 3-D planning is required for dose escalation to be undertaken safely.

5.4.2. Development of combination strategies

The natural progression of HCC involves early vascular invasion, contributing to intrahepatic relapse and extrahepatic metastasis even after substantial tumour regression by local treatments. This provides a rationale to combine local and systemic modalities. Radiotherapy can be combined with TACE, regional or systemic chemotherapy, or new targeting agents in an attempt to reduce these recurrences. This approach has been proven to achieve substantial tumour regression, even with portal vein invasion. Despite the impressive outcomes reported from single institutions, these combined treatments have not been tested in RCTs. Until RCTs are available, tumour boards may be unwilling to incorporate these combinations into clinical guidelines.

An increased number of novel molecular targeting agents have been developed and are awaiting assessment in clinical studies. Combinations of radiotherapy and these novel molecular targeting agents may well lead to further outcome improvement.

5.4.3. New radiotherapy technologies

A variety of newer precision technologies has been developed to improve radiotherapy dose delivery and improve the therapeutic ratio. These include intensity-modulated radiation therapy, image guided technology and particle beam radiotherapy. Reports using these techniques are increasing and fusion of these technologies and concepts are being trialled (e.g. the use of intensity modulation technology with proton beams). However, the impact of these new technologies on outcomes for HCC needs to be confirmed in further studies.

5.4.4. Redefinition of liver toxicity

Traditionally, radiation induced toxicity in the liver has been defined as RILD, as discussed in Section 4. While applicable for radiotherapy alone, different types of toxicity are frequently seen in combined modality strategies [304]. With the development of novel targeting agents and their combination with radiotherapy, the toxicity profile may change. In fact, any ‘hepatic dysfunction’ following therapy (including radiation therapy) should be included in future reports and considered as possibly related to therapy. One measure to be incorporated into a definition of hepatic dysfunction may be the Child–Pugh score.

5.5. RECOMMENDATION FOR FUTURE STUDIES

A number of clinical trials are suggested for consideration, as it is anticipated that the HCC community will be reluctant to accept radiotherapy without positive results confirming the advantage of radiotherapy, either alone or in various combinations. Suggested phase I, II and III trials are listed below. Given the substantial patient and tumour heterogeneity associated with HCC, some randomized phase II trials are recommended below (rather than single arm phase II studies). The following studies are recommended.

5.5.1. Clinical trials of HCC incorporating radiotherapy

- Phase I trials:
 - Radiotherapy combined with sorafenib or other molecular targeted agents.
- Phase II trials:
 - Randomized phase II trial of radiotherapy combined with TACE;
 - Randomized phase II trial of radiotherapy combined with molecular targeted agents.

- Phase III randomized trials:
 - BCLC B: TACE +/- radiotherapy;
 - BCLC C (portal vein thrombosis only): sorafenib +/- radiotherapy.

Symptomatic HCC is not suitable for other therapies: 8 Gy in one fraction versus best supportive care.

5.5.2. Stem cell recovery of liver function

Other studies indirectly related to the role of radiotherapy in the treatment of HCC include hematopoietic or hepatocyte stem cell transfer to rescue end stage liver disease from HCC or from radiation induced toxicity.

5.5.3. Redefinition of staging

It is clear that the tumour stage alone or the status of liver function alone is insufficient to categorize and select patients for optimal management. As stated in Section 3, the BCLC system may be helpful in describing patient populations in future studies, in addition to TNM staging. Furthermore, the Child–Pugh score should always be reported for all patients in any future studies.

5.5.4. Measurement of end points in palliation

In contrast to curative trials, for which the end points are survival and time to progression, the appropriate end points for palliative trials are short term improvement using validated questionnaires for symptom control (e.g. McGill pain tool) and quality of life (e.g. the European Organisation for Research and Treatment of Cancer or FACT HCC module).

6. CONCLUSIONS

HCC is a disease common to developing countries and one that usually develops following a number of well defined insults (viral, toxins, etc.) that are both hepatotoxic and carcinogenic. The anatomy of the liver, particularly the rich network of intrahepatic vascular structures draining into the hepatic veins, allows easy intrahepatic and extrahepatic tumour progression. The scenario of locally advanced tumour development within a compromised yet vital organ has implications for all aspects of management, including diagnosis, staging and treatment.

The only treatments currently with a recognized role for curative management are resection and liver transplantation. These are inapplicable for most patients, owing to the inability to leave a functional remnant of liver (resection) and the shortage of donor livers (transplantation). Unfortunately both procedures are associated with high intrahepatic and/or extrahepatic relapses.

As a result, most patients are considered incurable at the time of diagnosis, owing to a combination of tumour characteristics — predominantly size — and compromised hepatic function. This combination limits the application of many local treatments, including PEI, RFA and TACE, all of which are associated with high intrahepatic relapse rates.

In an attempt to improve the poor results of non-surgical treatment, there is currently a resurgence of interest in radiotherapy, either alone or in combination with other modalities. The rapid developments in radiotherapy technology over the past decade, together with promising early results of the treatment of HCC with radiotherapy, suggest that radiotherapy should be viewed as a legitimate treatment modality for HCC. High dose radiotherapy, delivered in a variety of ways, may be superior to non-surgical treatments in improving survival and even cure. The patterns of recurrence following high dose radiotherapy provide a strong rationale for combining radiotherapy with regional therapies such as TACE. Similarly, the feasibility and safety of combining radiotherapy with biological targeted agents should be assessed in future studies. Radiotherapy also retains a useful place in palliation of symptoms from advanced disease.

The lack of comparative data, especially RCTs, has impeded the inclusion of radiotherapy in the routine management of HCC. Thus, the imperative is the conduct of well designed RCTs, in parallel with phase I and II clinical trials using developing radiotherapy technology and combination therapies with radiotherapy.

Ultimately, the aim must be earlier diagnosis, when the tumour is smaller, reducing the risk of intra- or extrahepatic spread and facilitating curative treatments that retain a sufficient functioning liver. In particular, diagnostic imaging techniques with novel contrast enhancement are being explored.

REFERENCES

- [1] PARKIN, D.M., BRAY, F., FERLAY, J., PISANI, P., Estimating the world cancer burden: Globocan 2000, *Int. J. Cancer* **94** (2001) 153–156.
- [2] CHEN, J.G., et al., Trends in the incidence of cancer in Qidong, China, 1978–2002, *Int. J. Cancer* **119** (2006) 1447–1454.
- [3] LEE, C.L., HSIEH, K.S., KO, Y.C., Trends in the incidence of hepatocellular carcinoma in boys and girls in Taiwan after large-scale hepatitis B vaccination, *Cancer Epidemiol. Biomarkers Prev.* **12** (2003) 57–59.
- [4] EL-SERAG, H.B., Hepatocellular carcinoma: Recent trends in the United States, *Gastroenterology* **127** (2004) 27–34.
- [5] EL-SERAG, H.B., RUDOLPH, K.L., Hepatocellular carcinoma: Epidemiology and molecular carcinogenesis, *Gastroenterology* **132** (2007) 2557–2576.
- [6] ANZOLA, M., Hepatocellular carcinoma: Role of hepatitis B and hepatitis C virus proteins in hepatocarcinogenesis, *J. Viral Hepat.* **11** (2004) 383–393.
- [7] BRECHOT, C., Pathogenesis of hepatitis B virus-related hepatocellular carcinoma: Old and new paradigms, *Gastroenterology* **127** (2004) 56–61.
- [8] FATTOVICH, G., STROFFOLINI, T., ZAGNI, I., DONATO, F., Hepatocellular carcinoma in cirrhosis: Incidence and risk factors, *Gastroenterology* **127** (2004) 35–50.
- [9] YU, M.C., YUAN, J.M., Environmental factors and risk for hepatocellular carcinoma, *Gastroenterology* **127** (2004) S72–78.
- [10] GOLDACRE, M.J., WOTTON, C.J., YEATES, D., SEAGROATT, V., COLLIER, J., Liver cirrhosis, other liver diseases, pancreatitis and subsequent cancer: Record linkage study, *Eur. J. Gastroenterol. Hepatol.* **20** (2008) 384–392.
- [11] MALHI, H., GORES, G.J., Cellular and molecular mechanisms of liver injury, *Gastroenterology* **134** (2008) 1641–1654.
- [12] WORLD HEALTH ORGANIZATION, WHO Statistics Fact Sheets, 7 June 2008 WHO, Geneva (2006).
- [13] SHAPIRO, C.N., Epidemiology of hepatitis B, *Pediatr. Infect. Dis.* **12** (1993) 433–437.
- [14] ZIMMERMAN, R.K., RUBEN, F.L., AHWESH, E.R., Hepatitis B virus infection, hepatitis B vaccine, and hepatitis B immune globulin, *J. Fam. Pract.* **45** (1997) 295–315.
- [15] CHEN, P.J., CHEN, D.S., Hepatitis B virus infection and hepatocellular carcinoma: Molecular genetics and clinical perspectives, *Semin. Liver Dis.* **19** (1999) 253–262.
- [16] CHISARI, F. V., Rous–Whipple Award Lecture: Viruses, immunity, and cancer: lessons from Hepatitis B, *Am. J. Pathol.* **156** (2000) 1117–1132.
- [17] MURAKAMI, T., KIM, T., NAKAMURA, H., Hepatitis, cirrhosis, and hepatoma, *J. Magn. Reson. Imaging* **8** (1998) 346–358.
- [18] NAKAMOTO, Y., GUIDOTTI, L.G., KUHLEN, C.V., FOWLER, P., CHISARI, F.V., Immune pathogenesis of hepatocellular carcinoma, *J. Exp. Med.* **188** (1998) 341–350.
- [19] WANG, X.W., et al., Molecular pathogenesis of human hepatocellular carcinoma, *Toxicology* **181–182** (2002) 43–47.
- [20] HILDT, E., MUNZ, B., SAHER, G., REIFENBERG, K., HOFSCHEIDER, P.H., The Pres2 activator MHBs(T) of hepatitis B virus activates C–Raf–1/Erk2 signaling in transgenic mice, *EMBO J.* **21** (2002) 525–535.

- [21] PATERLINI-BRECHOT, P., et al., Hepatitis B virus-related insertional mutagenesis occurs frequently in human liver cancers and recurrently targets human telomerase gene, *Oncogene* **22** (2003) 3911–3916.
- [22] MURAKAMI, S., Hepatitis B virus X protein: A multifunctional viral regulator, *J. Gastroenterol.* **36** (2001) 651–660.
- [23] MURAKAMI, S., Expression and function of hepatitis B virus (HBV) X protein, *Seikagaku* **71** (1999) 1309–1326 (in Japanese).
- [24] SIMMONDS, P., Viral heterogeneity of the hepatitis C virus, *J. Hepatol.* **31** Suppl. 1 (1999) 54–60.
- [25] SIMMONDS, P., Genetic diversity and evolution of hepatitis C virus — 15 years on, *J. Gen. Virol.* **85** (2004) 3173–3188.
- [26] STRICKLAND, G.T., EL-KAMARY, S.S., KLENERMAN, P., NICOSIA, A., Hepatitis C vaccine: Supply and demand, *Lancet Infect. Dis.* **8** (2008) 379–386.
- [27] MONDELLI, M.U., SILINI, E., Clinical significance of hepatitis C virus genotypes, *J. Hepatol.* **31** Suppl. 1 (1999) 65–70.
- [28] LAUER, G.M., WALKER, B.D., Hepatitis C virus infection, *N. Engl. J. Med.* **345** (2001) 41–52.
- [29] EL-SERAG, H.B., Hepatocellular carcinoma: An epidemiologic view, *J. Clin. Gastroenterol.* **35** (2002) S72–78.
- [30] BRANDA, M., WANDS, J.R., Signal transduction cascades and hepatitis B and C related hepatocellular carcinoma, *Hepatology* **43** (2006) 891–902.
- [31] HU, K.Q., TONG, M.J., The long-term outcomes of patients with compensated hepatitis C virus-related cirrhosis and history of parenteral exposure in the United States, *Hepatology* **29** (1999) 1311–1316.
- [32] MORIYA, K., et al., The core protein of hepatitis C virus induces hepatocellular carcinoma in transgenic mice, *Nat. Med.* **4** (1998) 1065–1067.
- [33] YAMANAKA, T., KODAMA, T., DOI, T., Subcellular localization of HCV core protein regulates its ability for P53 activation and P21 suppression, *Biochem. Biophys. Res. Commun.* **294** (2002) 528–534.
- [34] KWUN, H.J., JANG, K.L., Dual effects of hepatitis C virus core protein on the transcription of cyclin-dependent kinase inhibitor P21 gene, *J. Virol. Hepat.* **10** (2003) 249–255.
- [35] MEISSONNIER, G.M., et al., Immunotoxicity of aflatoxin B1: Impairment of the cell-mediated response to vaccine antigen and modulation of cytokine expression, *Toxicol. Appl. Pharmacol.* (2008).
- [36] WILLIAMS, J.H., et al., Human aflatoxicosis in developing countries: A review of toxicology, exposure, potential health consequences, and interventions, *Am. J. Clin. Nutr.* **80** (2004) 1106–1122.
- [37] GROOPMAN, J.D., KENSLER, T. W., Role of metabolism and viruses in aflatoxin-induced liver cancer, *Toxicol. Appl. Pharmacol.* **206** (2005) 131–137.
- [38] SYLLA, A., DIALLO, M.S., CASTEGNARO, J., WILD, C.P., Interactions between hepatitis B virus infection and exposure to aflatoxins in the development of hepatocellular carcinoma: A molecular epidemiological approach, *Mutat. Res.* **428** (1999) 187–196.
- [39] ADAMI, H.O., et al., Alcoholism and liver cirrhosis in the etiology of primary liver cancer, *Int. J. Cancer* **51** (1992) 898–902.

- [40] ADAMI, H.O., et al., Alcoholism and cancer risk: A population-based cohort study, *Cancer Causes Control* **3** (1992) 419–425.
- [41] TANAKA, K., et al., Hepatitis B virus, cigarette smoking and alcohol consumption in the development of hepatocellular carcinoma: A case-control study in Fukuoka, Japan, *Int. J. Cancer* **51** (1992) 509–514.
- [42] STICKEL, F., SCHUPPAN, D., HAHN, E.G., SEITZ, H.K., Cocarcinogenic effects of alcohol in hepatocarcinogenesis, *Gut* **51** (2002) 132–139.
- [43] MORGAN, T.R., MANDAYAM, S., JAMAL, M.M., Alcohol and hepatocellular carcinoma, *Gastroenterology* **127** (2004) S87–96.
- [44] KOWDLEY, K.V., Iron, hemochromatosis, and hepatocellular carcinoma, *Gastroenterology* **127** (2004) S79–86.
- [45] FOWLER, C., Hereditary hemochromatosis: Pathophysiology, diagnosis, and management, *Crit. Care Nurs. Clin. North Am.* **20** (2008) 191–201, vi.
- [46] ADAMS, P.C., et al., Hemochromatosis and iron-overload screening in a racially diverse population, *N. Engl. J. Med.* **352** (2005) 1769–1778.
- [47] TADDEI, T., MISTRY, P., SCHILSKY, M.L., Inherited metabolic disease of the liver, *Curr. Opin. Gastroenterol.* **24** (2008) 278–286.
- [48] CAYLEY, W.E., Jr., Haemochromatosis, *Br. Med. J.* **336** (2008) 506.
- [49] CHEN, C.J., YU, M.W., LIAW, Y.F., Epidemiological characteristics and risk factors of hepatocellular carcinoma, *J. Gastroenterol. Hepatol.* **12** (1997) S294–308.
- [50] HARA, M., et al., Case-control study on cigarette smoking and the risk of hepatocellular carcinoma among Japanese, *Cancer Sci.* **99** (2008) 93–97.
- [51] CALLE, E.E., RODRIGUEZ, C., WALKER-THURMOND, K., THUN, M.J., Overweight, obesity, and mortality from cancer in a prospectively studied cohort of US adults, *N. Engl. J. Med.* **348** (2003) 1625–1638.
- [52] GRANDO-LEMAIRE, V., GUETTIER, C., CHEVRET, S., BEAUGRAND, M., TRINCHET, J.C., Hepatocellular carcinoma without cirrhosis in the West: Epidemiological factors and histopathology of the non-tumorous liver, *J. Hepatol.* **31** (1999) 508–513.
- [53] OMATA, M., PETERS, R.L., TATTER, D., Sclerosing hepatic carcinoma: Relationship to hypercalcemia, *Liver* **1** (1981) 33–49.
- [54] CRAIG, J.R., PETERS, R.L., EDMONDSON, H.A., OMATA, M., Fibrolamellar carcinoma of the liver: A tumor of adolescents and young adults with distinctive clinicopathologic features, *Cancer* **46** (1980) 372–379.
- [55] LEE, J.M.F., WONG, C.M., NG, I.O.L., Hepatitis B virus-associated multistep hepatocarcinogenesis — a stepwise increase in allelic alterations, *Cancer Res.* **68** (2008) 5988–5996.
- [56] LAURENT-PUIG, P., et al., Genetic alterations associated with hepatocellular carcinomas define distinct pathways of hepatocarcinogenesis, *Gastroenterol.* **120** (2001) 1763–1773.
- [57] BAIN, I., McMASTER, P., Benign and malignant liver tumors, *Surgery* **15** (1997) 169–176.
- [58] CONTRAN, R.S., KUMAR, V., ROBBINS, S.L., Robbins pathologic basis of disease, Saunders Publ., Philadelphia (2001).

- [59] BARBARA, L., et al., Natural history of small untreated hepatocellular carcinoma in cirrhosis: A multivariate analysis of prognostic factors of tumor growth rate and patient survival, *Hepatology* **16** (1992) 132–137.
- [60] OKAZAKI, N., et al., Evaluation of the prognosis for small hepatocellular carcinoma based on tumor volume doubling time: A preliminary report, *Cancer* **63** (1989) 2207–2210.
- [61] COLOMBO, M., et al., Hepatocellular carcinoma in Italian patients with cirrhosis, *N. Engl. J. Med.* **325** (1991) 675–680.
- [62] ALPERT, E., OKUDA, K., PETERS, R.L., *Human alpha-1 fetoprotein in hepatocellular carcinoma*, Wiley, New York (1976).
- [63] TAKETA, K., et al., A collaborative study for the evaluation of lectin-reactive alpha-fetoproteins in early detection of hepatocellular carcinoma, *Cancer Res.* **53** (1993) 5419–5423.
- [64] LOK, A.S., LAI, C.L., Alpha-fetoprotein monitoring in Chinese patients with chronic hepatitis B virus infection: Role in the early detection of hepatocellular carcinoma, *Hepatology* **9** (1989) 110–115.
- [65] SOULIER, J.P., GOZIN, D., LEFRERE, J.J., A new method to assay des-gamma-carboxyprothrombin: Results obtained in 75 cases of hepatocellular carcinoma, *Gastroenterology* **91** (1986) 1258–1262.
- [66] LIEBMAN, H.A., et al., Des-gamma-carboxy (abnormal) prothrombin as a serum marker of primary hepatocellular carcinoma, *N. Engl. J. Med.* **310** (1984) 1427–1431.
- [67] MARRERO, J.A., LOK, A.S., Newer markers for hepatocellular carcinoma, *Gastroenterology* **127** (2004) S113–119.
- [68] BOLONDI, L., et al., Ultrasonography and guided biopsy in the diagnosis of hepatocellular carcinoma, *Ital. J. Gastroenterol.* **24** (1992) 46–49.
- [69] MIMA, S., et al., Mass screening for hepatocellular carcinoma: Experience in Hokkaido, Japan, *J. Gastroenterol. Hepatol.* **9** (1994) 361–365.
- [70] OKUDA, K., Early recognition of hepatocellular carcinoma, *Hepatology* **6** (1986) 729–738.
- [71] DALLA PALMA, L., POZZI-MUCELLI, R., Computed tomography and magnetic resonance imaging in diagnosing HCC, *Ital. J. Gastroenterol.* **24** (1992) 87–97.
- [72] RUMMENY, E.J., MARCHAL, G., Liver imaging: Clinical applications and future perspectives, *Acta Radiol.* **38** (1997) 626–630.
- [73] BARTOLOZZI, C., et al., Small hepatocellular carcinoma: Detection with US, CT, MR imaging, DSA, and Lipiodol-CT, *Acta Radiol.* **37** (1996) 69–74.
- [74] KANEMATSU, M., et al., Detection of hepatocellular carcinoma in patients with cirrhosis: MR imaging versus angiographically assisted helical CT, *Am. J. Roentgenol.* **169** (1997) 1507–1515.
- [75] YAMASHITA, Y., et al., Small hepatocellular carcinoma in patients with chronic liver damage: Prospective comparison of detection with dynamic MR imaging and helical CT of the whole liver, *Radiology* **200** (1996) 79–84.
- [76] YU, J.S., KIM, K.W., LEE, J.T., YOO, H.S., MR imaging during arterial portography for assessment of hepatocellular carcinoma: Comparison with CT during arterial portography, *Am. J. Roentgenol.* **170** (1998) 1501–1506.

- [77] BORN, M., LAYER, G., KREFT, B., SCHWARZ, N., SCHILD, H., MRI, CT and CT arterial portography in the diagnosis of malignant liver tumors in liver cirrhosis, *RoeFo* **168** (1998) 567–572 (in German).
- [78] RIZZI, P.M., et al., Accuracy of radiology in detection of hepatocellular carcinoma before Liver Transplantation, *Gastroenterology* **107** (1994) 1425–1429.
- [79] HUANG, G.T., et al., Ultrasound-guided cutting biopsy for the diagnosis of hepatocellular carcinoma — a study based on 420 patients, *J. Hepatol.* **25** (1996) 334–338.
- [80] ACHKAR, J.P., et al., Undetected hepatocellular carcinoma: Clinical features and outcome after liver transplantation, *Liver Transpl. Surg.* **4** (1998) 477–482.
- [81] KANEMATSU, M., et al., Small hepatic nodules in cirrhosis: Ultrasonographic, CT, and MR imaging findings, *Abdom. Imaging* **24** (1999) 47–55.
- [82] TANG, Y., et al., Detection of hepatocellular carcinoma arising in cirrhotic livers: Comparison of gadolinium and ferumoxides-enhanced MR imaging, *Am. J. Roentgenol.* **172** (1999) 1547–1554.
- [83] DUVOUX, C., Epidemiology and diagnosis of hepatocellular carcinomas in cirrhosis, *Ann. Chir.* **52** (1998) 511–517.
- [84] MATSUSHIRO, Y., EBARA, M., OHTO, M., KONDO, F., Usefulness of percutaneous biopsy under sonographic control and histological examination in the early diagnosis of hepatocellular carcinoma, *Nippon Shokakibyō Gakkai Zasshi* **90** (1993) 655–664 (in Japanese).
- [85] JOURDAN, J.L., STUBBS, R.S., Percutaneous biopsy of operable liver lesions: Is it necessary or advisable?, *N.Z. Med. J.* **109** (1996) 469–470.
- [86] CHU YU, S., METREWELI, C., LAU, W., Safety of percutaneous biopsy of HCC with an 18 gauge automated needle, *Clin. Radiol.* **52** (1996) 907–911.
- [87] RYDER, S.D., Guidelines for the diagnosis and treatment of hepatocellular carcinoma (HCC) in adults, *Gut* **52** Suppl. 3 (2003) (iii)1–8.
- [88] FRAZER, C., Imaging of hepatocellular carcinoma, *J. Gastroenterol. Hepatol.* **14** (1999) 750–756.
- [89] SAADA, J., et al., Detection of small hepatocellular carcinomas in cirrhotic livers using iodised oil computed tomography, *Gut* **41** (1997) 404–407.
- [90] BIZOLLON, T., et al., Diagnostic value and tolerance of Lipiodol–computed tomography for the detection of small hepatocellular carcinoma: Correlation with pathologic examination of explanted livers, *J. Hepatol.* **28** (1998) 491–496.
- [91] HORIGOME, H., et al., Limitations of imaging diagnosis for small hepatocellular carcinoma: Comparison with histological findings, *J. Gastroenterol. Hepatol.* **14** (1999) 559–565.
- [92] DAS, D.K., Cytodiagnosis of hepatocellular carcinoma in fine-needle aspirates of the liver: Its differentiation from reactive hepatocytes and metastatic adenocarcinoma, *Diagn. Cytopathol.* **21** (1999) 370–377.
- [93] BOLONDI, L., et al., Surveillance programme of cirrhotic patients for early diagnosis and treatment of hepatocellular carcinoma: A cost effectiveness analysis, *Gut* **48** (2001) 251–259.
- [94] BRUIX, J., et al., Clinical management of hepatocellular carcinoma: Conclusions of the Barcelona 2000 EASL, *J. Hepatol.* **35** (2001) 421–430.

- [95] McMAHON, B.J., ALBERTS, S.R., WAINWRIGHT, R.B., BULKOW, L., LANIER, A.P., Hepatitis B-related sequelae: Prospective study in 1400 hepatitis B surface antigen-positive Alaska native carriers, *Arch. Intern. Med.* **150** (1990) 1051–1054.
- [96] SHERMAN, M., PELTEKIAN, K.M., LEE, C., Screening for hepatocellular carcinoma in chronic carriers of hepatitis B virus: Incidence and prevalence of hepatocellular carcinoma in a North American urban population, *Hepatology* **22** (1995) 432–438.
- [97] SOLMI, L., PRIMERANO, A.M., GANDOLFI, L., Ultrasound follow-up of patients at risk for hepatocellular carcinoma: Results of a prospective study on 360 cases, *Am. J. Gastroenterol.* **91** (1996) 1189–1194.
- [98] FUNG, J., GANE, E., BULLEN, C., HORNELL, J., McCALL, J., Improved survival with screening for hepatocellular carcinoma in chronic hepatitis B: Preliminary results of a national screening programme, *Hepatology* **40** (2004) 258A.
- [99] NG, I.O., LAI, E.C., FAN, S.T., NG, M.M., SO, M.K., Prognostic significance of pathologic features of hepatocellular carcinoma: A multivariate analysis of 278 patients, *Cancer* **76** (1995) 2443–2448.
- [100] ZHOU, L., et al., Clinicopathological features, post-surgical survival and prognostic indicators of elderly patients with hepatocellular carcinoma, *Eur. J. Surg. Oncol.* **32** (2006) 767–772.
- [101] MANN, C.D., et al., Prognostic molecular markers in hepatocellular carcinoma: A systematic review, *Eur. J. Cancer* **43** (2007) 979–992.
- [102] FIELDING, L.P., FENOGLIO-PREISER, C.M., FREEDMAN, L.S., The future of prognostic factors in outcome prediction for patients with cancer, *Cancer* **70** (1992) 2367–2377.
- [103] JUSTICE, A.C., COVINSKY, J.E., BERLIN, J.A., Assessing the generalizability of prognostic information, *Ann. Intern. Med.* **130** (1999) 515–524.
- [104] YARBRO, J.W., PAGE, D.L., FIELDING, L.P., PARTRIDGE, E.E., MURPHY, G.P., American Joint Committee on Cancer Prognostic Factors Consensus Conference, *Cancer* **86** (1999) 2436–2446.
- [105] IZUMI, R., et al., Prognostic factors of hepatocellular carcinoma in patients undergoing hepatic resection, *Gastroenterology* **106** (1994) 720–727.
- [106] OKUDA, K., et al., Natural history of hepatocellular carcinoma and prognosis in relation to treatment: Study of 850 patients, *Cancer* **56** (1985) 918–928.
- [107] MARKOVIC, S., et al., Treatment options in Western hepatocellular carcinoma: A prospective study of 224 patients, *J. Hepatol.* **29** (1998) 650–659.
- [108] SHIBATA, T., et al., Transthoracic percutaneous ethanol injection therapy for hepatocellular carcinomas located beneath the diaphragm, *J. Vasc. Interv. Radiol.* **9** (1998) 97–100.
- [109] LEVY, I., SHERMAN, M., Staging of hepatocellular carcinoma: Assessment of the CLIP, Okuda, and Child–Pugh staging systems in a cohort of 257 patients in Toronto, *Gut* **50** (2002) 881–885.
- [110] KUDO, M., CHUNG, H., OSAKI, Y., Prognostic staging system for hepatocellular carcinoma (CLIP score): Its value and limitations, and a proposal for a new staging system — the Japan Integrated Staging score (JIS score), *J. Gastroenterol.* **38** (2003) 207–215.

- [111] SEONG, J., et al., Evaluation of the prognostic value of Okuda, Cancer of the Liver Italian Program, and Japan Integrated Staging systems for hepatocellular carcinoma patients undergoing radiotherapy, *Int. J. Radiat. Oncol. Biol. Phys.* **67** (2007) 1037–1042.
- [112] LLOVET, J.M., BRU, C., BRUIX, J., Prognosis of hepatocellular carcinoma: The BCLC staging classification, *Semin. Liver Dis.* **19** (1999) 329–338.
- [113] BRUIX, J., BOIX, L., SALA, M., LLOVET, J.M., Focus on hepatocellular carcinoma, *Cancer Cell* **5** (2004) 215–219.
- [114] CONILL, C., VERGER, E., SALAMERO, M., Performance status assessment in cancer patients, *Cancer* **65** (1990) 1864–1866.
- [115] VERGER, E., SALAMERO, M., CONILL, C., Can Karnofsky performance status be transformed to the Eastern Cooperative Oncology Group scoring scale and vice versa?, *Eur. J. Cancer* **28A** (1992) 1328–1330.
- [116] SORENSEN, J.B., KLEE, M., PALSHOF, T., HANSEN, H.H., Performance status assessment in cancer patients: An inter-observer variability study, *Br. J. Cancer* **67** (1993) 773–775.
- [117] CILLO, U., et al., Prospective validation of the Barcelona Clinic Liver Cancer staging system, *J. Hepatol.* **44** (2006) 723–731.
- [118] BRUIX, J., SHERMAN, M., Management of hepatocellular carcinoma, *Hepatology* **42** (2005) 1208–1236.
- [119] PRIMROSE, J.N., Treatment of colorectal metastases: Surgery, cryotherapy, or radiofrequency ablation, *Gut* **50** (2002) 1–5.
- [120] BISMUTH, H., et al., Liver resection versus transplantation for hepatocellular carcinoma in cirrhotic patients, *Ann. Surg.* **218** (1993) 145–151.
- [121] BAIN, I., McMASTER, P., Benign and malignant liver tumors, *Surgery* **15** (1997) 169–174.
- [122] WILLIAMS, R.S., et al., Adult-to-adult living donor liver transplant: UK experience, *Eur. J. Gastroenterol. Hepatol.* **15** (2003) 7–14.
- [123] SNARSKA, J., PUCHALSKI, Z., SOKOLOWSKI, Z., PRUSZYNSKI, K., Complications after surgical resection of liver parenchyma, *Wiad. Lek.* **50** Suppl. 1 Pt 2 (1997) 284–288 (in Polish).
- [124] NAGASUE, N., et al., Clinical experience with 118 hepatic resections for hepatocellular carcinoma, *Surgery* **99** (1986) 694–701.
- [125] ZIBARI, G.B., et al., Surgical and nonsurgical management of primary and metastatic liver tumors, *Am. Surg.* **64** (1998) 211–220.
- [126] BUSUTTIL, R.W., et al., Analysis of long-term outcomes of 3200 liver transplantations over two decades: A single center experience, *Ann. Surg.* **241** 6 (2005) 905–918.
- [127] KAWARADA, Y., et al., Surgical treatment of hepatocellular carcinoma, *Cancer Chemother. Pharmacol.* **33** Suppl. (1994) S12–17.
- [128] FUNOVICS, J.M., et al., Primary hepatic cancer — the role of limited resection and total hepatectomy with orthotopic liver replacement, *Hepatogastroenterology* **35** (1988) 316–320.
- [129] FARMER, D.G., ROSOVE, M.H., SHAKED, A., BUSUTTIL, R.W., Current treatment modalities for hepatocellular carcinoma, *Ann. Surg.* **219** (1994) 236–247.
- [130] WU, M., CHEN, H., YAO, X., Surgical Treatment of Primary Liver Cancer, *Zhonghua Wai Ke Za Zhi* **34** (1996) 707–710 (in Chinese).

- [131] COLLEONI, M., et al., Practical considerations in the treatment of hepatocellular carcinoma, *Drugs* **55** (1998) 367–382.
- [132] MAZZAFERRO, V., et al., Liver transplantation for the treatment of small hepatocellular carcinomas in patients with cirrhosis, *N. Engl. J. Med.* **334** (1996) 693–699.
- [133] PICHLMAYR, R., et al., Role of liver transplantation in the treatment of unresectable liver cancer, *World J. Surg.* **19** (1995) 807–813.
- [134] SELBY, R., et al., Liver transplantation for hepatocellular carcinoma, *World J. Surg.* **19** (1995) 53–58.
- [135] UNDERWOOD, J.C.E., *General and Systemic Pathology*, Churchill Livingstone, (1996).
- [136] DALGIC, A., et al., Role of total hepatectomy and transplantation in hepatocellular carcinoma, *Transplant Proc.* **26** (1994) 3564–3565.
- [137] GREWAL, H.P., BONATTI, H., HEWITT, W., “Use of extended criteria liver donors shortens waiting time to transplantation and may improve survival for patients with hepatocellular carcinoma”, paper presented at 9th Congress of the International Liver Transplantation Society, Barcelona, 2003.
- [138] BRUIX, J., “State-of-the-art lecture: Hepatocellular carcinoma and liver transplantation”, paper presented at 9th Congress of the International Liver Transplantation Society, Barcelona, 2003.
- [139] FREEMAN, R.B., HARPER, A.M., EDWARDS, E.B., MELD/PELD: One year later, *Transplant Proc.* **35** (2003) 2425–2427.
- [140] YAO, F.Y., et al., Liver transplantation for hepatocellular carcinoma: Expansion of the tumor size limits does not adversely impact survival, *Hepatology* **33** (2001) 1394–1403.
- [141] YAO, F.Y., BASS, N.M., ASCHER, N.L., ROBERTS, J.P., Liver transplantation for hepatocellular carcinoma: Lessons from the first year under the model of end-stage liver disease (MELD) organ allocation policy, *Liver Transpl.* **10** (2004) 621–630.
- [142] DECAENS, T., ROUDOT-THORAVALL, F., HADNI-BRESSON, S., What is the impact of UCSF expansion criteria according to pre-liver transplantation tumor characteristics on survival: Results from 14 French centers, *Hepatology* **40** (2004) 550A.
- [143] BEFELER, A.S., MARRERO, J.A., CHARI, R.S., The epidemiology and survival of patients with hepatocellular carcinoma in the United States, a preliminary report of the Liver Cancer Network, *Hepatology* **40** (2004) 216A.
- [144] SHARMA, P., et al., Liver transplantation for hepatocellular carcinoma: The MELD impact, *Liver Transpl.* **10** (2004) 36–41.
- [145] BELGHITI, J., et al., Resection prior to liver transplantation for hepatocellular carcinoma, *Ann. Surg.* **238** (2003) 885–892.
- [146] CHIRICA, M., DURAND, F., SOMMACALE, D., Long term outcome after resection for small hepatocellular carcinoma (HCC) in patients with hepatitis C virus (HCV) infection: Arguments for a strategy of resection as a bridge to transplantation rather than salvage transplantation, *Hepatology* **40** (2004) 162A.
- [147] OTTO, G., et al., Survival and recurrence after liver transplantation versus liver resection for hepatocellular carcinoma: A retrospective analysis, *Ann. Surg.* **227** (1998) 424–432.
- [148] LAI, E.C., et al., Hepatic resection for hepatocellular carcinoma: An audit of 343 patients, *Ann. Surg.* **221** (1995) 291–298.

- [149] ADACHI, E., et al., Risk factors for intrahepatic recurrence in human small hepatocellular carcinoma, *Gastroenterology* **108** (1995) 768–775.
- [150] GOUILLAT, C., MANGANAS, D., BERARD, P., Ultrasonically guided hepatic tumorectomy, *J. Am. Coll. Surg.* **180** (1995) 616–618.
- [151] SOREIDE, O., CZERNIAK, A., BRADPIECE, H., BLOOM, S., BLUMGART, L., Characteristics of fibrolamellar hepatocellular carcinoma: A study of nine cases and a review of the literature, *Am. J. Surg.* **151** (1986) 518–523.
- [152] VAUTHEY, J.N., et al., Factors affecting long-term outcome after hepatic resection for hepatocellular carcinoma, *Am. J. Surg.* **169** (1995) 28–34.
- [153] PINNA, A.D., et al., Treatment of fibrolamellar hepatoma with subtotal hepatectomy or transplantation, *Hepatology* **26** (1997) 877–883.
- [154] ADHAM, M.E.A., Results of orthotopic liver transplantation for liver cirrhosis in the presence of incidental and/or undetected hepatocellular carcinoma and tumour characteristics, *Transpl. Int.* **11** (1998) 197–200.
- [155] MANZARBEITIA, C., ORTIZ, J., JEON, H., “Incidental (undetected) hepatocellular carcinomas in liver transplant recipients: A single center experience”, paper presented at 9th Congress of the International Liver Transplantation Society, Barcelona, 2003.
- [156] SHIINA, S., et al., Percutaneous ethanol injection therapy for hepatocellular carcinoma: A histopathologic study, *Cancer J.* **68** (1991).
- [157] LIVRAGHI, T., et al., Percutaneous ethanol injection in the treatment of hepatocellular carcinoma in cirrhosis: A study on 207 patients, *Cancer* **69** (1992) 925–929.
- [158] OKUDA, K., OKUDA, H., MCINTYRE, N., BENHAMOU, J.P., BIRCHER, J., Oxford Textbook of Clinical Hepatology Primary Liver Carcinoma, Oxford University Press, Oxford (1991).
- [159] CASTELLS, A., et al., Treatment of small hepatocellular carcinoma in cirrhotic patients: A cohort study comparing surgical resection and percutaneous ethanol injection, *Hepatology* **18** (1993) 1121–1126.
- [160] BARTOLOZZI, C., LENCIONI, R., ARMILLOTTA, N., Combined treatment of hepatocarcinoma with chemoembolization and alcohol administration: Long-term results, *Radiol. Med.* **94** (1997) 19–23 (in Italian).
- [161] LIVRAGHI, T., et al., Hepatocellular carcinoma and cirrhosis in 746 patients: Long-term results of percutaneous ethanol injection, *Radiology* **197** (1995) 101–108.
- [162] VILANA, R., et al., Tumor size determines the efficacy of percutaneous ethanol injection for the treatment of small hepatocellular carcinoma, *Hepatology* **16** (1992) 353–357.
- [163] SHIMADA, M., MAEDA, T., SAITOH, A., MOROTOMI, I., KANO, T., Needle track seeding after percutaneous ethanol injection therapy for small hepatocellular carcinoma, *J. Surg. Oncol.* **58** (1995) 278–281.
- [164] DI STASI, M., BUSCARINI, L., LIVRAGHI, T., PEI in the treatment of HCC: A multicentre survey of evaluation practices and complication rates, *Scand. J. Gastroenterol.* **32** (1997) 1168–1173.
- [165] ISHII, H., et al., Needle tract implantation of hepatocellular carcinoma after percutaneous ethanol injection, *Cancer J.* **82** (1998) 1638–1642.
- [166] OHNISHI, K., YOSHIOKA, H., ITO, S., FUJIWARA, K., Prospective randomized controlled trial comparing percutaneous acetic acid injection and percutaneous ethanol injection for small hepatocellular carcinoma, *Hepatology* **27** (1998) 67–72.

- [167] ALLGAIER, H.P., DEIBERT, P., ZUBER, I., OLSCHESKI, M., BLUM, H.E., Percutaneous radiofrequency interstitial thermal ablation of small hepatocellular carcinoma, *Lancet* **353** (1999) 1676–1677.
- [168] MORRIS, D.E., ABOULJOD, M., Short-term results of radiofrequency ablation in liver tumors, *Am. J. Surg.* **179** (2000) 527.
- [169] OHMOTO, K., YAMAMOTO, S., Percutaneous microwave coagulation therapy for superficial hepatocellular carcinoma on the liver surface, *Am. J. Gastroenterol.* **95** (2000) 2401–2403.
- [170] LIVRAGHI, T., et al., Hepatocellular carcinoma: Radio-frequency ablation of medium and large lesions, *Radiology* **214** (2000) 761–768.
- [171] CURLEY, S.A., IZZO, F., ELLIS, L.M., NICOLAS VAUTHEY, J., VALLONE, P., Radiofrequency ablation of hepatocellular cancer in 110 patients with cirrhosis, *Ann. Surg.* **232** (2000) 381–391.
- [172] LIVRAGHI, T., et al., Small hepatocellular carcinoma: Treatment with radio-frequency ablation versus ethanol injection, *Radiology* **210** (1999) 655–661.
- [173] LIN, D.Y., LIN, S.M., LIAW, Y.F., Non-surgical treatment of hepatocellular carcinoma, *J. Gastroenterol. Hepatol.* **12** (1997) S319–S328.
- [174] ZHOU, X.D., TANG, Z.Y., Management of hepatocellular carcinoma: Long-term outcome in 2639 cases, *Gan To Kagaku Ryoho* **24** Suppl. 1 (1997) 9–16.
- [175] WONG, W.S., PATEL, S.C., CRUZ, F.S., GALA, K.V., TURNER, A.F., Cryosurgery as a treatment for advanced stage hepatocellular carcinoma: Results, complications, and alcohol ablation, *Cancer* **82** (1998) 1268–1278.
- [176] DOYON, D., MOUZON, A., JOURDE, A.M., REGENSBERG, C., FRILEUX, C., Hepatic, arterial embolization in patients with malignant liver tumours, *Ann. Radiol.* **17** (1974) 593–603 (in French).
- [177] RYDER, S.D., RIZZI, P.M., METIVIER, E., KARANI, J., WILLIAMS, R., Chemoembolisation with lipiodol and doxorubicin: Applicability in British patients with hepatocellular carcinoma, *Gut* **38** (1996) 125–128.
- [178] OKAZAKI, M., et al., Intraoperative hemorrhage from hepatocellular carcinoma: Emergency chemoembolization or embolization, *Radiology* **180** (1991) 647–651.
- [179] LIN, D.Y., LIAW, Y.F., LEE, T.Y., LAI, C.M., Hepatic arterial embolization in patients with unresectable hepatocellular carcinoma: A randomized controlled trial, *Gastroenterology* **94** (1988) 453–456.
- [180] PELLETIER, G., et al., A randomized trial of hepatic arterial chemoembolization in patients with unresectable hepatocellular carcinoma, *J. Hepatol.* **11** (1990) 181–184.
- [181] MADDEN, M.V., et al., Randomised trial of targeted chemotherapy with lipiodol and 5-epidoxorubicin compared with symptomatic treatment for hepatoma, *Gut* **34** (1993) 1598–1600.
- [182] NEW ENGLAND JOURNAL OF MEDICINE, “A comparison of lipiodol chemoembolization and conservative treatment for unresectable hepatocellular carcinoma”, *N. Engl. J. Med.* **332** (1995) 1256–1261.
- [183] BRUIX, J., et al., Transarterial embolization versus symptomatic treatment in patients with advanced hepatocellular carcinoma: Results of a randomized, controlled trial in a single institution, *Hepatology* **27** (1998) 1578–1583.

- [184] PELLETIER, G., et al., Treatment of unresectable hepatocellular carcinoma with lipiodol chemoembolization: A multicenter randomized trial, *J. Hepatol.* **29** (1998) 129–134.
- [185] HASHIMOTO, M., WATANABE, O., HIRANO, Y., KATO, K., WATARAI, J., Use of carbon dioxide microbubble-enhanced sonographic angiography for transcatheter arterial chemoembolization of hepatocellular carcinoma, *Am. J. Roentgenol.* **169** (1997) 1307–1310.
- [186] LLOVET, J.M., et al., Arterial embolisation or chemoembolisation versus symptomatic treatment in patients with unresectable hepatocellular carcinoma: A randomised controlled trial, *Lancet* **359** (2002) 1734–1739.
- [187] LO, C.M., et al., Randomized controlled trial of transarterial lipiodol chemoembolization for unresectable hepatocellular carcinoma, *Hepatology* **35** (2002) 1164–1171.
- [188] KASUGAI, H., et al., Treatment of hepatocellular carcinoma by transcatheter arterial embolization combined with intraarterial infusion of a mixture of cisplatin and ethiodized oil, *Gastroenterology* **97** (1989) 965–971.
- [189] BELLI, L., et al., Arteritis following intra-arterial chemotherapy for liver tumors, *Eur. Radiol.* **7** (1997) 323–326.
- [190] LIU, C.L., NGAN, H., LO, C.M., FAN, S.T., Ruptured hepatocellular carcinoma as a complication of transarterial oily chemoembolization, *Br. J. Surg.* **85** (1998) 512–514.
- [191] LENCIONI, R., et al., Transcatheter arterial embolization followed by percutaneous ethanol injection in the treatment of hepatocellular carcinoma, *Cardiovasc. Intervent. Radiol.* **17** (1994) 70–75.
- [192] BARTOLOZZI, C., et al., Treatment of large HCC: Transcatheter arterial chemoembolization combined with percutaneous ethanol injection versus repeated transcatheter arterial chemoembolization, *Radiology* **197** (1995) 812–818.
- [193] YAMAMOTO, K., et al., Evaluation of combined therapy with chemoembolization and ethanol injection for advanced hepatocellular carcinoma, *Semin. Oncol.* **24** (1997) S6–S50–S56–55.
- [194] SOGA, K., et al., Clinical evaluation of transcatheter arterial embolization and one-shot chemotherapy in hepatocellular carcinoma, *Hepatogastroenterology* **35** (1988) 116–120.
- [195] TOYODA, H., et al., The efficacy of continuous local arterial infusion of 5-fluorouracil and cisplatin through an implanted reservoir for severe advanced hepatocellular carcinoma, *Oncology* **52** (1995) 295–299.
- [196] CHEN, H.S., GROSS, J.F., Intra-arterial infusion of anticancer drugs: Theoretic aspects of drug delivery and review of responses, *Cancer Treat. Rep.* **64** (1980) 31–40.
- [197] DOCI, R., et al., Intrahepatic chemotherapy for unresectable hepatocellular carcinoma, *Cancer* **61** (1988) 1983–1987.
- [198] PATT, Y.Z., et al., Hepatic arterial infusion of floxuridine, leucovorin, doxorubicin, and cisplatin for hepatocellular carcinoma: Effects of hepatitis B and C viral infection on drug toxicity and patient survival, *J. Clin. Oncol.* **12** (1994) 1204–1211.
- [199] ONOHARA, S., KOBAYASHI, H., ITOH, Y., SHINOHARA, S., Intra-arterial cisplatin infusion with sodium thiosulfate protection and angiotensin II induced hypertension for treatment of hepatocellular carcinoma, *Acta Radiol.* **29** (1988) 197–202.

- [200] HUANG, C.C., et al., Overexpression of the MDR1 Gene and P-glycoprotein in human hepatocellular carcinoma, *J. Natl. Cancer Inst.* **84** (1992) 262–264.
- [201] JOHNSON, P.J., WILLIAMS, R., THOMAS, H., SHERLOCK, S., MURRAY-LYON, I.M., Induction of remission in hepatocellular carcinoma with doxorubicin, *Lancet* **1** (1978) 1006–1009.
- [202] SCIARRINO, E., SIMONETTI, R.G., LE MOLI, S., PAGLIARO, L., Adriamycin treatment for hepatocellular carcinoma: Experience with 109 patients, *Cancer* **56** (1985) 2751–2755.
- [203] MELIA, W.M., JOHNSON, P.J., WILLIAMS, R., Induction of remission in hepatocellular carcinoma: A comparison of VP 16 with adriamycin, *Cancer* **51** (1983) 206–210.
- [204] PORTA, C., MORONI, M., NASTASI, G., ARCANGELI, G., 5-fluorouracil and D,L-leucovorin calcium are active to treat unresectable hepatocellular carcinoma patients: Preliminary results of a Phase II study, *Oncology* **52** (1995) 487–491.
- [205] LEE, J., et al., Phase II study of doxorubicin and cisplatin in patients with metastatic hepatocellular carcinoma, *Cancer Chemother. Pharmacol.* **54** (2004) 385–390.
- [206] YEO, W., et al., A randomized Phase III study of doxorubicin versus cisplatin/interferon alpha-2b/doxorubicin/fluorouracil (PIAF) combination chemotherapy for unresectable hepatocellular carcinoma, *J. Natl. Cancer Inst.* **97** (2005) 1532–1538.
- [207] YANG, T.S., LIN, Y.C., CHEN, J.S., WANG, H.M., WANG, C.H., Phase II study of gemcitabine in patients with advanced hepatocellular carcinoma, *Cancer* **89** (2000) 750–756.
- [208] O'REILLY, E.M., et al., A Phase II study of irinotecan in patients with advanced hepatocellular carcinoma, *Cancer* **91** (2001) 101–105.
- [209] LOUAFI, S., et al., Gemcitabine plus oxaliplatin (Gemox) in patients with advanced hepatocellular carcinoma (HCC): Results of a Phase II study, *Cancer* **109** (2007) 1384–1390.
- [210] LIU, L., et al., Sorafenib blocks the RAF/MEK/ERK pathway, inhibits tumor angiogenesis, and induces tumor cell apoptosis in hepatocellular carcinoma model PLC/PRF/5, *Cancer Res.* **66** (2006) 11851–11858.
- [211] LLOVET, J.M., et al., Sorafenib in advanced hepatocellular carcinoma, *N. Engl. J. Med.* **359** (2008) 378–390.
- [212] CHENG, A.L., et al., Efficacy and safety of sorafenib in patients in the Asia-Pacific region with advanced hepatocellular carcinoma: A Phase III randomised, double-blind, placebo-controlled trial, *Lancet Oncol.* **10** (2009) 25–34.
- [213] MARTINEZ CEREZO, F.J., et al., Controlled trial of tamoxifen in patients with advanced hepatocellular carcinoma, *J. Hepatol.* **20** (1994) 702–706.
- [214] MANESIS, E.K., GIANNOULIS, G., ZOUMBOULIS, P., VAFIADOU, I., HADZIYANNIS, S.J., Treatment of hepatocellular carcinoma with combined suppression and inhibition of sex hormones: A randomized, controlled trial, *Hepatology* **21** (1995) 1535–1542.
- [215] CASTELLS, A., et al., Treatment of hepatocellular carcinoma with tamoxifen: A double-blind placebo-controlled trial in 120 patients, *Gastroenterology* **109** (1995) 917–922.
- [216] CHENG, A.L., et al., Chronic oral etoposide and tamoxifen in the treatment of far-advanced hepatocellular carcinoma, *Cancer* **77** (1996) 872–877.

- [217] ELBA, S., GIANNUZZI, V., MISCIAGNA, G., MANGHISI, O.G., Randomized controlled trial of tamoxifen versus placebo in inoperable hepatocellular carcinoma, *Ital. J. Gastroenterol.* **26** (1994) 66–68.
- [218] RIESTRA, S., et al., Tamoxifen does not improve survival of patients with advanced hepatocellular carcinoma, *J. Clin. Gastroenterol.* **26** (1998) 200–203.
- [219] CHAO, Y., et al., Phase II study of flutamide in the treatment of hepatocellular carcinoma, *Cancer* **77** (1996) 635–639.
- [220] YAMASHITA, Y., et al., Prognostic factors in the treatment of hepatocellular carcinoma with transcatheter arterial embolization and arterial infusion, *Cancer* **67** (1991) 385–391.
- [221] FALKSON, G., ANSELL, S., Phase II trial of buserelin in hepatocellular carcinoma, *Eur. J. Cancer Clin. Oncol.* **25** (1989) 1339–1340.
- [222] SON, K., KEW, M., RABSON, A.R., Depressed natural killer cell activity in patients with hepatocellular carcinoma: In vitro effects of interferon and levamisole, *Cancer* **50** (1982) 2820–2825.
- [223] SACHS, E., et al., Treatment of hepatocellular carcinoma with recombinant leucocyte interferon: A pilot study, *Br. J. Cancer* **52** (1985) 105–109.
- [224] LAI, C.L., et al., Placebo-controlled trial of recombinant alpha 2-interferon in Chinese HBsAG-carrier children, *Lancet* **2** (1987) 877–880.
- [225] PATT, Y.Z., et al., Low serum alpha-fetoprotein level in patients with hepatocellular carcinoma as a predictor of response to 5-FU and interferon-alpha-2b, *Cancer* **72** (1993) 2574–2582.
- [226] INOUE, A., et al., Effectiveness of interferon therapy for reducing the incidence of hepatocellular carcinoma among patients with type C chronic hepatitis, *J. Epidemiol.* **10** (2000) 234–240.
- [227] KOWDLEY, K.V., Does interferon therapy prevent hepatocellular carcinoma in patients with chronic hepatitis C?, *Gastroenterology* **117** (1999) 738–739.
- [228] LAI, C.L., et al., Recombinant interferon-alpha in inoperable hepatocellular carcinoma: A randomized controlled trial, *Hepatology* **17** (1993) 389–394.
- [229] LLOVET, J.M., et al., Prevalence and prognostic value of hepatocellular carcinoma in cirrhotic patients presenting with spontaneous bacterial peritonitis, *J. Hepatol.* **33** (2000) 423–429.
- [230] TAKAYAMA, T., et al., Adoptive immunotherapy to lower postsurgical recurrence rates of hepatocellular carcinoma: A randomised trial, *Lancet* **356** (2000) 802–807.
- [231] MUNK, P.L., MAROTTA, T.R., Intralesional injection of absolute alcohol into vertebral hemangiomas: A new treatment option?, *Am. J. Neuroradiol.* **20** (1999) 959–960.
- [232] LEIBEL, S.A., et al., A comparison of misonidazole sensitized radiation therapy to radiation therapy alone for the palliation of hepatic metastases: Results of a radiation therapy oncology group randomized prospective trial, *Int. J. Radiat. Oncol. Biol. Phys.* **13** (1987) 1057–1064.
- [233] BYDDER, S., et al., A prospective trial of short-fractionation radiotherapy for the palliation of liver metastases, *Australas. Radiol.* **47** (2003) 284–288.
- [234] KAIZU, T., et al., Radiotherapy for osseous metastases from hepatocellular carcinoma: A retrospective study of 57 patients, *Am. J. Gastroenterol.* **93** (1998) 2167–2171.
- [235] SEONG, J., KOOM, W.S., PARK, H.C., Radiotherapy for painful bone metastases from hepatocellular carcinoma, *Liver Int.* **25** (2005) 261–265.

- [236] TUNC, B., FILIK, L., TEZER-FILIK, I., SAHIN, B., Brain metastasis of hepatocellular carcinoma: A case report and review of the literature, *World J. Gastroenterol.* **10** (2004) 1688–1689.
- [237] ZENG, Z.C., et al., Consideration of role of radiotherapy for lymph node metastases in patients with HCC: Retrospective analysis for prognostic factors from 125 patients, *Int. J. Radiat. Oncol. Biol. Phys.* **63** (2005) 1067–1076.
- [238] PARK, Y.J., et al., Radiation therapy for abdominal lymph node metastasis from hepatocellular carcinoma, *J. Gastroenterol.* **41** (2006) 1099–1106.
- [239] SAKURAI, M., OKAMURA, J., KURODA, C., Transcatheter chemo-embolization effective for treating hepatocellular carcinoma: A histopathologic study, *Cancer* **54** (1984) 387–392.
- [240] YU, Y.Q., et al., Experience with liver resection after hepatic arterial chemoembolization for hepatocellular carcinoma, *Cancer* **71** (1993) 62–65.
- [241] SHIM, S.J., et al., Local radiotherapy as a complement to incomplete transcatheter arterial chemoembolization in locally advanced hepatocellular carcinoma, *Liver Int.* **25** (2005) 1189–1196.
- [242] YASUDA, S., et al., Radiotherapy for large hepatocellular carcinoma combined with transcatheter arterial embolization and percutaneous ethanol injection therapy, *Int. J. Oncol.* **15** (1999) 467–473.
- [243] GUO, W.J., YU, E.X., Evaluation of combined therapy with chemoembolization and irradiation for large hepatocellular carcinoma, *Br. J. Radiol.* **73** (2000) 1091–1097.
- [244] CHIA-HSIEN CHENG, J., et al., Unresectable hepatocellular carcinoma treated with radiotherapy and/or chemoembolization, *Int. J. Cancer* **96** (2001) 243–252.
- [245] ZENG, Z.C., et al., A comparison of chemoembolization combination with and without radiotherapy for unresectable hepatocellular carcinoma, *Cancer J.* **10** (2004) 307–316.
- [246] HAN, K.H., et al., Pilot clinical trial of localized concurrent chemoradiation therapy for locally advanced hepatocellular carcinoma with portal vein thrombosis, *Cancer* **113** (2008) 995–1003.
- [247] KIM, J.K., et al., Prospective large scaled trial of concurrent intraarterial chemoradiation therapy following repeated intraarterial chemotherapy for advanced hepatocellular carcinoma with portal vein thrombosis, *J. Hepatol.* **48** (2008) S148.
- [248] ROBERTSON, J.M., et al., A Phase I trial of hepatic arterial bromodeoxyuridine and conformal radiation therapy for patients with primary hepatobiliary cancers or colorectal liver metastases, *Int. J. Radiat. Oncol. Biol. Phys.* **39** (1997) 1087–1092.
- [249] BEN-JOSEF, E., et al., Phase II trial of high-dose conformal radiation therapy with concurrent hepatic artery floxuridine for unresectable intrahepatic malignancies, *J. Clin. Oncol.* **23** (2005) 8739–8747.
- [250] HSU, W.C., et al., Results of three-dimensional conformal radiotherapy and thalidomide for advanced hepatocellular carcinoma, *Jpn. J. Clin. Oncol.* **36** (2006) 93–99.
- [251] BUSH, D.A., HILLEBRAND, D.J., SLATER, J.M., SLATER, J.D., High-dose proton beam radiotherapy of hepatocellular carcinoma: Preliminary results of a Phase II trial, *Gastroenterology* **127** (2004) S189–193.
- [252] RICKE, J., et al., CT-guided interstitial brachytherapy of liver malignancies alone or in combination with thermal ablation: Phase I–II results of a novel technique, *Int. J. Radiat. Oncol. Biol. Phys.* **58** (2004) 1496–1505.

- [253] CRELLIN, R.P., CHAN, S.Y., Hepatocellular carcinoma treated by intraluminal brachytherapy, *Clin. Oncol.* **5** (1993) 332.
- [254] GOLDSCHMIDT, R.P., KOTZEN, J.A., GIRAUD, R.M., Intraductal hepatocellular carcinoma treated by intraluminal brachytherapy, *Clin. Oncol.* **5** (1993) 118–119.
- [255] TIAN, J.H., et al., Ultrasound-guided internal radiotherapy using yttrium-90 glass microspheres for liver malignancies, *J. Nucl. Med.* **37** (1996) 958–963.
- [256] GRADY, E.D., Intrahepatic arterial 90-yttrium resin spheres to treat liver cancer, *Int. J. Nucl. Med. Biol.* **5** (1978) 253–254.
- [257] HOULE, S., et al., Hepatocellular carcinoma: Pilot trial of treatment with Y-90 microspheres, *Radiology* **172** (1989) 857–860.
- [258] SHEPHERD, F.A., et al., A Phase I dose escalation trial of yttrium-90 microspheres in the treatment of primary hepatocellular carcinoma, *Cancer* **70** (1992) 2250–2254.
- [259] YAN, Z.P., LIN, G., ZHAO, H.Y., DONG, Y.H., An experimental study and clinical pilot trials on yttrium-90 glass microspheres through the hepatic artery for treatment of primary liver cancer, *Cancer* **72** (1993) 3210–3215.
- [260] DANCEY, J.E., et al., Treatment of non-resectable hepatocellular carcinoma with intrahepatic 90-Y microspheres, *J. Nucl. Med.* **41** (2000) 1673–1681.
- [261] GESCHWIND, J.F., et al., Yttrium-90 microspheres for the treatment of hepatocellular carcinoma, *Gastroenterology* **127** (2004) S194–205.
- [262] GOIN, J.E., et al., Treatment of unresectable hepatocellular carcinoma with intrahepatic yttrium 90 microspheres: Factors associated with liver toxicities, *J. Vasc. Interv. Radiol.* **16** (2005) 205–213.
- [263] GOIN, J.E., et al., Treatment of unresectable hepatocellular carcinoma with intrahepatic yttrium 90 microspheres: A risk-stratification analysis, *J. Vasc. Interv. Radiol.* **16** (2005) 195–203.
- [264] LAU, W.Y., et al., Treatment of inoperable hepatocellular carcinoma with intrahepatic arterial yttrium-90 microspheres: A Phase I and II study, *Br. J. Cancer* **70** (1994) 994–999.
- [265] LAU, W.Y., et al., Selective internal radiation therapy for non-resectable hepatocellular carcinoma with intraarterial infusion of yttrium-90 microspheres, *Int. J. Radiat. Oncol. Biol. Phys.* **40** (1998) 583–592.
- [266] MONSIEURS, M.A., et al., Patient dosimetry for ¹³¹I-lipiodol therapy, *Eur. J. Nucl. Med. Mol. Imaging* **30** (2003) 554–561.
- [267] RAOUL, J.L., et al., Randomized controlled trial for hepatocellular carcinoma with portal vein thrombosis: Intra-arterial iodine-131-iodized oil versus medical support, *J. Nucl. Med.* **35** (1994) 1782–1787.
- [268] RAOUL, J.L., et al., Prospective randomized trial of chemoembolization versus intra-arterial injection of ¹³¹I-labeled-iodized oil in the treatment of hepatocellular carcinoma, *Hepatology* **26** (1997) 1156–1161.
- [269] ORDER, S., et al., A randomized prospective trial comparing full dose chemotherapy to ¹³¹I antiferritin: An RTOG study, *Int. J. Radiat. Oncol. Biol. Phys.* **20** (1991) 953–963.
- [270] LAMBERT, B., VAN DE WIELE, C., Treatment of hepatocellular carcinoma by means of radiopharmaceuticals, *Eur. J. Nucl. Med. Mol. Imaging* **32** (2005) 980–989.

- [271] MORNEX, F., et al., Feasibility and efficacy of high-dose three-dimensional conformal radiotherapy in cirrhotic patients with small-size hepatocellular carcinoma non-eligible for curative therapies: Mature results of the French Phase II RTF-I Trial, *Int. J. Radiat. Oncol. Biol. Phys.* **66** (2006) 1152–1158.
- [272] PARK, W., et al., Local radiotherapy for patients with unresectable hepatocellular carcinoma, *Int. J. Radiat. Oncol. Biol. Phys.* **61** (2005) 1143–1150.
- [273] SEONG, J., et al., A multicenter retrospective cohort study of practice patterns and clinical outcome on radiotherapy for hepatocellular carcinoma in Korea, *Liver Int.* **29** (2009) 147–152.
- [274] CHENG, J.C., et al., Dosimetric analysis and comparison of three-dimensional conformal radiotherapy and intensity-modulated radiation therapy for patients with hepatocellular carcinoma and radiation-induced liver disease, *Int. J. Radiat. Oncol. Biol. Phys.* **56** (2003) 229–234.
- [275] GUO, W.J., et al., Comparison between chemoembolization combined with radiotherapy and chemoembolization alone for large hepatocellular carcinoma, *World J. Gastroenterol.* **9** (2003) 1697–1701.
- [276] LI, B., et al., Study of local three-dimensional conformal radiotherapy combined with transcatheter arterial chemoembolization for patients with stage III hepatocellular carcinoma, *Am. J. Clin. Oncol.* **26** (2003) 92–99.
- [277] YAMADA, K., et al., Prospective trial of combined transcatheter arterial chemoembolization and three-dimensional conformal radiotherapy for portal vein tumor thrombus in patients with unresectable hepatocellular carcinoma, *Int. J. Radiat. Oncol. Biol. Phys.* **57** (2003) 113–119.
- [278] WU, D.H., LIU, L., CHEN, L.H., Therapeutic effects and prognostic factors in three-dimensional conformal radiotherapy combined with transcatheter arterial chemoembolization for hepatocellular carcinoma, *World J. Gastroenterol.* **10** (2004) 2184–2189.
- [279] BLOMGREN, H., LAX, I., NASLUND, I., SVANSTROM, R., Stereotactic high dose fraction radiation therapy of extracranial tumors using an accelerator: Clinical experience of the first thirty-one patients, *Acta Oncologica* (1995) 861–870.
- [280] WULF, J., et al., Stereotactic radiotherapy of primary liver cancer and hepatic metastases, *Acta Oncol.* **45** (2006) 838–847.
- [281] MENDEZ ROMERO, A., et al., Stereotactic body radiation therapy for primary and metastatic liver tumors: A single institution Phase I–II study, *Acta Oncol.* **45** (2006) 831–837.
- [282] CHEN, L.H., GUAN, J., Value of conformal radiotherapy for middle stage or advanced primary hepatocellular carcinoma, *Di Yi Jun Yi Da Xue Xue Bao* **23** (2003) 55–57 (in Chinese).
- [283] TSE, R.V., et al., Phase I study of individualized stereotactic body radiotherapy for hepatocellular carcinoma and intrahepatic cholangiocarcinoma, *J. Clin. Oncol.* **26** (2008) 657–664.
- [284] CHIBA, T., et al., Proton beam therapy for hepatocellular carcinoma: A retrospective review of 162 patients, *Clin. Cancer Res.* **11** (2005) 3799–3805.
- [285] HATA, M., et al., Proton beam therapy for hepatocellular carcinoma with portal vein tumor thrombus, *Cancer* **104** (2005) 794–801.

- [286] HATA, M., et al., Proton beam therapy for hepatocellular carcinoma with limited treatment options, *Cancer* **107** (2006) 591–598.
- [287] HATA, M., et al., Proton beam therapy for hepatocellular carcinoma patients with severe cirrhosis, *Strahlenther. Onkol.* **182** (2006) 713–720.
- [288] FUKUMITSU, N., et al., A prospective study of hypofractionated proton beam therapy for patients with hepatocellular carcinoma, *Int. J. Radiat. Oncol. Biol. Phys.* (2009).
- [289] KAWASHIMA, M., et al., Phase II study of radiotherapy employing proton beam for hepatocellular carcinoma, *J. Clin. Oncol.* **23** (2005) 1839–1846.
- [290] KATO, H., et al., Results of the first prospective study of carbon ion radiotherapy for hepatocellular carcinoma with liver cirrhosis, *Int. J. Radiat. Oncol. Biol. Phys.* **59** (2004) 1468–1476.
- [291] OGATA, K., et al., Hepatic injury following irradiation: A morphologic study, *Tokushima J. Exp. Med.* **43** (1963) 240–251.
- [292] INGOLD, J., REED, G., KAPLAN, H., Radiation hepatitis, *Am. J. Roentgenol.* **93** (1965) 200–208.
- [293] REED, G., COX, A., The human liver after radiation injury: A form of veno-occlusive disease, *Am. J. Pathol.* **48** (1966) 597–611.
- [294] LAWRENCE, T.S., et al., Hepatic toxicity resulting from cancer treatment, *Int. J. Radiat. Oncol. Biol. Phys.* **31** (1995) 1237–1248.
- [295] FAJARDO, L.F., COLBY, T.V., Pathogenesis of veno-occlusive liver disease after radiation, *Arch. Pathol. Lab. Med.* **104** (1980) 584–588.
- [296] YAMASAKI, S., KOSUGE, T., TAKAYAMA, T., SHIMADA, K., YAMAMOTO, J., Hepatocellular carcinoma originated in the caudate lobe, *Ryokibetsu Shokogun Shirizu* (1995) 507–510 (in Japanese).
- [297] AHMADI, T., OKUMURA, T., ONAYA, H., AKINE, Y., ITAI, Y., Preservation of hypervascularity in hepatocellular carcinoma after effective proton-beam radiotherapy: CT observation, *Clin. Radiol.* **54** (1999) 253–256.
- [298] SHIM, S. J., et al., Radiation-induced hepatic toxicity after radiotherapy combined with chemotherapy for hepatocellular carcinoma, *Hepatol. Res.* **37** (2007) 906–913.
- [299] YAMANAKA, Y., YAMANO, M., YASUNAGA, K., SHIKE, T., UCHIDA, K., Effect of warfarin on plasma and liver vitamin K levels and vitamin K epoxide reductase activity in relation to plasma clotting factor levels in rats, *Thromb. Res.* **57** (1990) 205–214.
- [300] HEMMING, A.W., SCUDAMORE, C.H., SHACKLETON, C.R., PUDEK, M., ERB, S.R., Indocyanine green clearance as a predictor of successful hepatic resection in cirrhotic patients, *Am. J. Surg.* **163** (1992) 515–518.
- [301] SCHNEIDER, P.D., Preoperative assessment of liver function, *Surg. Clin. North Am.* **84** (2004) 355–373.
- [302] CHENG, J.C., et al., Unexpectedly frequent hepatitis B reactivation by chemoradiation in postgastrectomy patients, *Cancer* **101** (2004) 2126–2133.
- [303] KIM, J.H., et al., Hepatitis B virus reactivation after three-dimensional conformal radiotherapy in patients with hepatitis B virus-related hepatocellular carcinoma, *Int. J. Radiat. Oncol. Biol. Phys.* **69** (2007) 813–819.
- [304] CHENG, J.C., LIU, H.S., WU, J.K., CHUNG, H.W., JAN, G.J., Inclusion of biological factors in parallel-architecture normal-tissue complication probability model for radiation-induced liver disease, *Int. J. Radiat. Oncol. Biol. Phys.* **62** (2005) 1150–1156.

- [305] SEONG, J., et al., Clinical results of 3-dimensional conformal radiotherapy combined with transarterial chemoembolization for hepatocellular carcinoma in the cirrhotic patients, *Hepatol. Res.* **27** (2003) 30–35.
- [306] LEE, I.J., SEONG, J., SHIM, S.J., HAN, K.H., Radiotherapeutic parameters predictive of liver complications induced by liver tumor radiotherapy, *Int. J. Radiat. Oncol. Biol. Phys.* (2008)
- [307] DAWSON, L.A., et al., Analysis of radiation-induced liver disease using the Lyman NTCP model, *Int. J. Radiat. Oncol. Biol. Phys.* **53** (2002) 810–821.
- [308] CHENG, J.C., et al., Biologic susceptibility of hepatocellular carcinoma patients treated with radiotherapy to radiation-induced liver disease, *Int. J. Radiat. Oncol. Biol. Phys.* **60** (2004) 1502–1509.
- [309] XU, Z.Y., et al., Prediction of radiation-induced liver disease by Lyman Normal Tissue Complication Probability model in three-dimensional conformal radiation therapy for primary liver carcinoma, *Int. J. Radiat. Oncol. Biol. Phys.* **65** (2006) 189–195.
- [310] NIEMIERKO, A., GOITEIN, M., Modeling of normal tissue response to radiation: The critical volume model, *Int. J. Radiat. Oncol. Biol. Phys.* **25** (1993) 135–145.
- [311] DAWSON, L.A., TEN HAKEN, R.K., LAWRENCE, T.S., Partial irradiation of the liver, *Semin. Radiat. Oncol.* **11** (2001) 240–246.
- [312] KIM, T.H., et al., Dose–volumetric parameters predicting radiation-induced hepatic toxicity in unresectable hepatocellular carcinoma patients treated with three-dimensional conformal radiotherapy, *Int. J. Radiat. Oncol. Biol. Phys.* **67** (2007) 225–231.
- [313] MOGAVERO, G.T., JONES, B., CAMERON, J.L., COLEMAN, J., Gastric and duodenal obstruction in patients with cholangiocarcinoma in the porta hepatis: Increased prevalence after radiation therapy, *Am. J. Roentgenol.* **159** (1992) 1001–1003.
- [314] KOPELSON, G., HARISIADIS, L., TRETTER, P., CHANG, C.H., The role of radiation therapy in cancer of the extra-hepatic biliary system: An analysis of thirteen patients and a review of the literature of the effectiveness of surgery, chemotherapy and radiotherapy, *Int. J. Radiat. Oncol. Biol. Phys.* **2** (1977) 883–894.
- [315] BUSKIRK, S.J., et al., Analysis of failure following curative irradiation of gallbladder and extrahepatic bile duct carcinoma, *Int. J. Radiat. Oncol. Biol. Phys.* **10** (1984) 2013–2023.
- [316] ALDEN, M.E., et al., Cholangiocarcinoma: Clinical significance of tumor location along the extrahepatic bile duct, *Radiology* **197** (1995) 511–516.
- [317] PARK, J.W., Practice guideline for diagnosis and treatment of hepatocellular carcinoma, *Korean J. Hepatol.* **10** (2004) 88–98.

Annex I

MOLECULAR PATHOLOGY OF HEPATOCELLULAR CARCINOMA (HCC)

I-1. CHROMOSOMAL AND GENETIC ALTERATIONS IN HEPATOCARCINOGENESIS

Allelic loss is uncommon in cirrhotic livers. For dysplastic nodules, an analysis of chromosomal gains and losses using comparative genomic hybridization (CGH) demonstrated that the frequency and pattern of genetic alterations in dysplastic nodules greatly resembled those in HCCs. Gains of DNA were found to cluster in chromosome arms 1p, 1q, 7q, 15q, 16p, 17q and 20q, with losses of DNA at 3p, 4q, 9p and 11q [I-1]. Such frequency and pattern of genetic alterations were not seen in other hepatocellular nodules such as focal nodular hyperplasia and hepatocellular adenomas, implying that dysplastic nodule is a precancerous lesion. Altogether, the genetic results indicate a stepwise increase in the genetic abnormalities from cirrhosis through dysplastic nodule to HCC, giving support to the notion of multistep hepatocarcinogenesis. Moreover, low grade dysplastic nodules and macroregenerative nodules did not show chromosomal imbalances of allelic losses on 8p and of gains of 1q, as in high grade dysplastic nodule and HCC [I-2]. Recently, genome wide microarray analysis has been employed to study the molecular expression profiles of the different stages in hepatocarcinogenesis from cirrhosis through dysplastic nodules to HCC [I-3 to I-5]. These have been useful in identifying a possible 'molecular signature' to distinguish dysplastic nodules from HCC.

In HCC, recurrent chromosome alterations are frequent and they include loss of 1p, 4q, 8p, 16q and 17p, and gain of 1q, 8q and 20q [I-6 to I-8]. These findings reflect a high degree of chromosomal instability in HCC, contributing to hepatocarcinogenesis. Coupled with detailed clinicopathological correlation and gene mutation analysis (e.g. p53 or β -catenin mutations), different genetic pathways can be delineated [I-9, I-10]. HCC can be divided into two groups, one having chromosome stability with β -catenin mutation and chromosome 8p losses and the other demonstrating chromosomal instability, with frequent allelic losses on chromosome 1p, 4q, 6q, 9p, 13q, 16p, 16q and 17p, and p53 and Axin1 mutations [I-10]. A recent study, using comprehensive genome wide allelotyping with >400 markers coupled with detailed clinicopathological correlation and p53 mutation analysis, has shown that HCC can be stratified into low stage and advanced stage tumours predicting different survivals. In addition, chromosomes 1p, 8p and 13q are among the most frequently affected chromosome arms in HCC

and other cancers [I–11]. Previous reports in HCC have shown that allelic losses on these chromosomes range from 17.5 to 53% and they may harbour putative tumour suppressor genes [I–12 to I–14].

With CGH analysis, HCC has been shown to harbour multiple chromosomal abnormalities, predominantly losses, with increased chromosomal instability. Recurrent aberrant gains have been found on 1q, 8q, 16p and 20q and recurrent chromosomal losses on 1p, 4q, 8p, 13q, 16q and 17p to [I–15 to I–18]. Recently, array based CGH has been used to provide high resolution mapping of chromosomal aberrations in HCC. Although the chromosomal abnormalities reported are similar to those obtained with CGH, correlation with gene expression data may identify novel oncogenes and tumour suppressor genes [I–19].

Aberrations have also been found to differ in HCC with different etiological backgrounds. Chromosomal aberrations were more frequent in HBV related HCCs than in HCV associated tumours [I–20]. Another study showed that HBV associated HCCs had significantly more frequent (40% on average) losses at 4q, 16q and 17p (including the p53 region) than in non-viral HCC samples, suggesting that these abnormalities were associated with HBV infection [I–20]. With regard to other chromosomes, a gain of 10q (7/41, 17%) was detected exclusively in cases with HCV infection, whereas amplification of 11q13 was more frequently seen in HBV positive HCCs. However, in other studies, no significant difference in chromosomal aberrations between HBV and HCV associated HCCs were found [I–21].

I–2. EPIGENETIC ALTERATIONS IN HEPATOCARCINOGENESIS

In addition to genetic alterations, epigenetic alterations play an important role in human carcinogenesis. ‘Epigenetic’ refers to changes in DNA methylation and histone modifications that stably modify gene transcription but do not involve changes of the DNA sequences. DNA methylation is the covalent addition of a methyl group ($-\text{CH}_3$) to the 5 position of cytosine and is the most well-characterized epigenetic event. The dominant epigenetic alteration in cancers is the aberrant hypermethylation of CpG islands in gene promoter regions. Hypermethylated promoters are almost always transcriptionally silent.

Aberrant CpG island methylation may result in inactivation of tumour suppressor genes. The tumour suppressor gene p16/INK4A, a cyclin dependent kinase inhibitor regulating the phosphorylation status of the retinoblastoma gene product, is frequently inactivated in HCC by promoter methylation [I–16 to I–22]. Loss of p16 function may limit the tumour suppressor function of the wild type retinoblastoma gene product and lead to unregulated cellular proliferation

[I-23]. Another tumour suppressor gene, deleted in liver cancer 1, a negative regulator of Rho family GTPases, has been reported to be frequently silenced in human HCCs via DNA hypermethylation [I-24]. Other well-characterized tumour suppressor genes that regulate various cellular pathways in human HCC include E-cadherin [I-25], RASSF1A [I-26], SFRP1 [I-27], GTSP1 [I-28], SOSC-1 [I-29] and PTEN [I-30].

REFERENCES TO ANNEX I

- [I-1] RAIDL, M., et al., Multiple chromosomal abnormalities in human liver (pre)neoplasia, *J. Hepatol.* **40** (2004) 660–668.
- [I-2] TORNILLO, L., et al., Chromosomal alterations in hepatocellular nodules by comparative genomic hybridization: High-grade dysplastic nodules represent early stages of hepatocellular carcinoma, *Lab. Invest.* **82** (2002) 547–553.
- [I-3] NAM, S.W., et al., Molecular changes from dysplastic nodule to hepatocellular carcinoma through gene expression profiling, *Hepatology* **42** (2005) 809–818.
- [I-4] LLOVET, J.M., et al., A molecular signature to discriminate dysplastic nodules from early hepatocellular carcinoma in HCV cirrhosis, *Gastroenterology* **131** (2006) 1758–1767.
- [I-5] WURMBACH, E., et al., Genome-wide molecular profiles of HCV-induced dysplasia and hepatocellular carcinoma, *Hepatology* **45** (2007) 938–947.
- [I-6] KUSANO, N., et al., Genetic aberrations detected by comparative genomic hybridization in hepatocellular carcinomas: Their relationship to clinicopathological features, *Hepatology* **29** (1999) 1858–1862.
- [I-7] MARCHIO, A., et al., Recurrent chromosomal abnormalities in hepatocellular carcinoma detected by comparative genomic hybridization, *Genes Chromosomes Cancer* **18** (1997) 59–65.
- [I-8] PIAO, Z., et al., Frequent chromosomal instability but no microsatellite instability in hepatocellular carcinomas, *Int. J. Oncol.* **17** (2000) 507–512.
- [I-9] JOU, Y.S., et al., Clustering of minimal deleted regions reveals distinct genetic pathways of human hepatocellular carcinoma, *Cancer Res.* **64** (2004) 3030–3036.
- [I-10] LAURENT-PUIG, P., et al., Genetic alterations associated with hepatocellular carcinomas define distinct pathways of hepatocarcinogenesis, *Gastroenterology* **120** (2001) 1763–1773.
- [I-11] CLETON-JANSEN, A.M., et al., Loss of heterozygosity in sporadic breast tumours at the BRCA2 locus on chromosome 13q12–q13, *Br. J. Cancer* **75** (1995) 1241–1244.
- [I-12] CHAN, K.L., et al., High-density allelotyping of chromosome 8p in hepatocellular carcinoma and clinicopathologic correlation, *Cancer* **94** (2002) 3179–3185.
- [I-13] FANG, W., et al., Mapping of a minimal deleted region in human hepatocellular carcinoma to 1p36.13-p36.23 and mutational analysis of the RIZ (PRDM2) gene localized to the region, *Genes Chromosomes Cancer* **28** (2000) 269–275.
- [I-14] WONG, C.M., et al., Clinicopathological significance of loss of heterozygosity on chromosome 13q in hepatocellular carcinoma, *Clin. Cancer Res.* **8** (2002) 2266–2272.

- [I-15] GUAN, X.Y., et al., Recurrent chromosome alterations in hepatocellular carcinoma detected by comparative genomic hybridization, *Genes Chromosomes Cancer* **29** (2000) 110–116.
- [I-16] PANG, A., et al., Clinicopathologic significance of genetic alterations in hepatocellular carcinoma, *Cancer Genet. Cytogenet.* **146** (2003) 8–15.
- [I-17] WILKENS, L., et al., Differentiation of liver cell adenomas from well-differentiated hepatocellular carcinomas by comparative genomic hybridization, *J. Pathol.* **193** (2001) 476–482.
- [I-18] WONG, N., et al., Assessment of genetic changes in hepatocellular carcinoma by comparative genomic hybridization analysis: Relationship to disease stage, tumor size, and cirrhosis, *Am. J. Pathol.* **154** (1999) 37–43.
- [I-19] PATIL, M.A., et al., Array-based comparative genomic hybridization reveals recurrent chromosomal aberrations and *Jab1* as a potential target for 8q gain in hepatocellular carcinoma, *Carcinogenesis* **26** (2005) 2050–2057.
- [I-20] ZONDERVAN, P.E., et al., Molecular cytogenetic evaluation of virus-associated and non-viral hepatocellular carcinoma: Analysis of 26 carcinomas and 12 concurrent dysplasias, *J. Pathol.* **192** (2000) 207–215.
- [I-21] SAKAKURA, C., et al., Chromosomal aberrations in human hepatocellular carcinomas associated with hepatitis C virus infection detected by comparative genomic hybridization, *Br. J. Cancer* **80** (1999) 2034–2039.
- [I-22] LIEW, C.T., et al., High frequency of p16INK4A gene alterations in hepatocellular carcinoma, *Oncogene* **18** (1999) 789–795.
- [I-23] SERRANO, M., HANNON, G.J., BEACH, D., A new regulatory motif in cell-cycle control causing specific inhibition of cyclin D/CDK4, *Nature* **366** (1993) 704–707.
- [I-24] WONG, C.M., et al., Genetic and epigenetic alterations of *DLC-1* gene in hepatocellular carcinoma, *Cancer Res.* **63** (2003) 7646–7651.
- [I-25] KANAI, Y., et al., The E-cadherin gene is silenced by CpG methylation in human hepatocellular carcinomas, *Int. J. Cancer* **71** (1997) 355–359.
- [I-26] SCHAGDARSURENGIN, U., et al., Frequent epigenetic inactivation of the *RASSF1A* gene in hepatocellular carcinoma, *Oncogene* **22** (2003) 1866–1871.
- [I-27] SHIH, Y.L., et al., Promoter methylation of the secreted frizzled-related protein 1 gene *SFRP1* is frequent in hepatocellular carcinoma, *Cancer* **107** (2006) 579–590.
- [I-28] ZHONG, S., et al., Silencing of *GSTP1* gene by CpG island DNA hypermethylation in HBV-associated hepatocellular carcinomas, *Clin. Cancer Res.* **8** (2002) 1087–1092.
- [I-29] YOSHIKAWA, H., et al., *SOCS-1*, a negative regulator of the JAK/STAT pathway, is silenced by methylation in human hepatocellular carcinoma and shows growth-suppression activity, *Nat. Genet.* **28** (2001) 29–35.
- [I-30] WANG, L., et al., Epigenetic and genetic alterations of *PTEN* in hepatocellular carcinoma, *Hepatol. Res.* **37** (2007) 389–396.

Annex II

TECHNICAL CONSIDERATIONS IN RADIOTHERAPY OF HEPATOCELLULAR CARCINOMA (HCC)

II-1. RADIATION TREATMENT PLANNING

II-1.1. Imaging at simulation

At the time of simulation, patient positioning and the imaging modality (computed tomography (CT), magnetic resonance imaging), resolution (e.g. CT thickness), and phase of contrast (e.g. arterial IV contrast for HCC) must be chosen. Breathing motion must be considered at this time, as breathing introduces artifacts in planning CT and possibly in tumour definition, normal tissue definition and resultant errors in tumour control probability and normal tissue complication probability.

One method to account for motion is to eliminate it, for example, with a breath hold scan. Diagnostic breath hold scans are often obtained in inhalation. However, exhalation breath hold scans are often used for radiation planning of HCC patients. An alternative to breath hold imaging is to obtain a 4-D imaging data set. From this, any position could be used for planning and image guidance [II-1]. Planning on the exhalation dataset with asymmetric planning target volume (PTV) margins is an option [II-2], as is planning using the mean tumour position.

II-1.2. Target volumes

The gross tumour volume (GTV) should consist of the arterial enhancing parenchymal liver tumour and any enhancing portal vein thrombosis. The clinical target volume (CTV) margin should include the GTV. The ideal CTV margin to account for microscopic disease is unknown. CTV margins from 5 to 10 mm are often used in conformal radiotherapy. With stereotactic body radiotherapy (SBRT), it is usual to equate the CTV to the GTV, as some dose is delivered to microscopic disease in the rim around the GTV, owing to dose fall-off outside the target volume.

The PTV margins must consider set-up uncertainty and internal organ motion. Individual institution set-up uncertainty data should be used if available. Individual patient internal organ motion, for example, breathing motion, should be used if this information is known. If unavailable, a PTV margin is used to ensure coverage of 90% of the population for 90% of the time.

II-1.3. Radiotherapy planning

CT based conformal planning software is generally used for dose calculations for a radical HCC radiotherapy plan. Inhomogeneities should be considered and computer optimization of beam angles, beam weights or segments within beam angles can help to optimize the shape and the dose distribution of critical normal tissues.

For SBRT, many beams of low weight are used to develop a highly conformal dose distribution. If required, non-coplanar beams or arcs are used to reduce the dose to normal tissues. When sufficient beams are summed, the PTV may be covered by a lower isodose, such as 60%, which often corresponds to the steepest part of the dose gradient. Resultant high doses/hotspots occur in the centre of the PTV, perhaps giving the highest dose to the central hypoxic volume (although the potential benefit of this is unproven).

II-2. MOTION MANAGEMENT

Organ motion due to physiological functions during a radiation fraction can be substantial. For example, the liver can move 3–5 cm in the caudal–cranial direction during free breathing [II-3], causing motion of the upper abdominal and lower thoracic cavity. As this motion can result in alterations in target and normal organ volume definitions, PTV margins and the entire dose distribution and interventions to reduce the impact of intratreatment organ motion are required.

Strategies to compensate for breathing motion include the use of abdominal pressure, voluntary shallow breathing, voluntary deep inspiration, voluntary breath holds at variable phases of the respiratory cycle, active breathing control, gated radiotherapy and real time tumour tracking. Voluntary breath holding may be beneficial for some patients, although there is potential for leaking air and patient error. Active breathing control refers to organ immobilization with breath holds that are controlled, triggered and monitored by a caregiver. In approximately 60% of patients with HCC, active breathing control was able to be used successfully. However, despite the use of breath holding to reduce the amplitude of breathing motion, the mean liver position may vary from day to day relative to the vertebral bodies, providing a rationale for daily image guidance.

Gated radiotherapy, in which the beam is triggered to be ‘on’ only during a predetermined phase of the respiratory cycle, usually refers to the use of an external surrogate for tumour position (as opposed to direct tumour imaging) to gate the radiation. Ideally, gating should be based on imaging of the tumour rather than external surrogates for the tumour. Gating can be used to reduce the volume

of normal tissue irradiated. Changes in baseline liver position can occur from day-to-day [II-1] and thus image guidance is important.

Tumour tracking is another approach to reduce the adverse effects of organ motion. Fluoroscopic X ray tubes in the treatment room allow visualization of radio-opaque markers or the diaphragm, both surrogates for movement of the HCC. The linear accelerator is triggered to irradiate only when the marker is located within the planned treatment region [II-4]. As an alternative to turning the radiation beam off when the tumour moves outside the treatment fields, multileaf collimators, the couch position or the entire accelerator may move with the tumour to ensure adequate tumour coverage at all times. An example of mobility of all components is the Cyberknife image guided radiosurgery system (Accuray, Sunnyvale, CA). The Cyberknife is a lightweight (150 kg) 6 MV linear accelerator mounted on a robotic arm, with 5–60 mm collimators and providing a dose rate of 300–400 MU/min.

There are advantages to gating, breath hold and tracking in the exhalation phase of the respiratory breathing cycle versus the inhalation phase. Exhalation tends to be more reproducible and is longer than inhalation, so that treatment during exhalation reduces the treatment time.

II-3. IMAGE GUIDED RADIOTHERAPY (IGRT)

II-3.1. Introduction to IGRT

Imaging immediately before or during treatment delivery is used to improve the precision and accuracy of radiotherapy. This frequent imaging is referred to as image guided radiotherapy, or IGRT. Since IGRT improves set-up accuracy and precision, it allows PTV margins to be reduced, reducing the volume of normal tissue that is required to be irradiated.

Traditionally, surrogates for the target (e.g. skin marks) have been used to guide the placement of radiation treatment beams. In most body tumours, the internal structures cannot be accurately localized with such surrogates. The use of bony anatomy with electronic portal imaging is another historical standard practice in radiotherapy. However, for many clinical situations, the position of the bones is not well correlated with the internal tumour position. Options for locating internal anatomy include the use of implanted radio-opaque fiducial markers as surrogates for the target, or localizing tissues adjacent to the tumour or the tumour itself.

IGRT can be performed with conventional linear accelerators using the megavoltage treatment beam. However, more specialized treatment units are now available with the potential to allow soft tissue image guidance. Examples

include the Cyberknife and modified linear accelerators such as Novalis (BrainLAB, Westchester, IL), Synergy (Elekta Oncology, Stockholm), Trilogy (Varian Medical Systems, Palo Alto, CA), Artiste (Siemens, Concord, CA) and Tomotherapy (Madison, WI).

II-3.2. Image guidance strategies

The two primary correction strategies that may be used to reduce setup error are an on-line approach and an off-line approach. The on-line approach refers to the use of daily imaging prior to every fraction with correction for off-sets when the position is greater than a predefined threshold prior to daily treatment. An off-line approach refers to the collection of imaging data with high frequency at the beginning of therapy (e.g. first 5 fractions), followed by an off-line analysis to determine the set-up errors. A correction is then made to counter the systematic error, with possible replanning to individualize the PTV margins based on the patient's random set-up error as sampled at the beginning of therapy.

On-line correction strategies reduce both systematic and random set-up errors, with a greater reduction in error compared with the off-line approach, but at the expense of increased time and cost. On-line correction strategies are most appropriate for hypofractionated radiotherapy or SBRT, as there are generally few fractions to collect set-up data and there is a strong rationale for reducing set-up error.

II-3.3. Two dimensional IGRT

Orthogonal MV portal films (replaced more recently by electronic portal imaging devices) have been used for image guidance for decades. Although mostly used to visualize bones to position the patient, if radio-opaque fiducial markers are inserted in or near the tumour, the fiducial markers may be used for guidance. Other alternatives for guidance include using surrogates that are in close proximity to the tumour, for example, the diaphragm as a surrogate for liver tumours.

Orthogonal kV radiographs and kV fluoroscopy have also been used for image guidance of tumours and/or fiducial markers, either immediately prior to, or throughout, each treatment fraction [II-5, II-6] or throughout radiation delivery [II-4]. The kV X ray tubes may be ceiling or wall mounted or attached to the linear accelerator. With both MV and kV orthogonal imaging, alignment tools registering the images to reference images obtained at the time of planning can improve the accuracy and efficiency of image matching to determine the off-sets in position.

Real time tumour tracking while the radiation beam is turned on is another IGRT approach. A highly integrated tracking system consisting of four ceiling mounted fluoroscopic X ray tubes and four floor mounted flat panel imagers in the treatment room allowing visualization of radio-opaque markers in the tumours was first described by Shirato et al. [II–4]. This system has a temporal resolution is 30 frames/s and a precision of 1.5 mm. The linear accelerator is triggered to irradiate only when the fiducial marker is located within a predefined volume.

As an alternative to turning the radiation beam off when the tumour moves outside the treatment region, multileaf collimators, the couch position or the entire accelerator on a robotic arm may move with the tumour to ensure adequate tumour coverage combined with dual orthogonal fluoroscopy tubes to track radio-opaque markers in or near the tumour at a preset frequency. When the beam is on, infrared external surrogates are continuously monitored, while the internal anatomy is monitored periodically with kV imaging. Another system (Novalis) also acquires kV orthogonal images and matches them to images obtained from the planning CT. The imaging axes are not coincident with the isocentre, and a translation of patient position is required between imaging and treatment.

II–3.4. Three dimensional IGRT

Technological advances allowing volumetric imaging permit image guidance immediately prior to treatment using either the tumour or a soft tissue organ in close proximity to the tumour for guidance, rather than the bony anatomy. Volumetric imaging systems have the advantage that adjacent normal organs can also be visualized for more accurate avoidance of critical structures.

Ultrasound (US) has also been used for image guidance of HCCs. Significant reductions in residual set-up error were observed using US guidance, with a mean 3-D residual set-up error vector of 4.6 mm (+/–3.4 mm) following image guidance [II–7]. The advantages of US are that it is widely available and relatively inexpensive; the disadvantages are that the accuracy of the system for image guidance requires specialized training and is user dependent.

The placement of a diagnostic CT scanner in the treatment room with a known geometric relationship to the linear accelerator is another volumetric IGRT strategy. Uematsu et al. have used this approach to treat HCCs. With these systems, the CT scanner is in close proximity to the linear accelerator, allowing the couch to be moved from the imaging position to the treatment position. The CT scanner gantry is often translated during acquisition to minimize couch motion. An advantage of in-room CT is that state of the art diagnostic quality CT can be used for optimal image quality and robustness. A disadvantage of this system is that the imaging and treatment isocentres are not coincident. Accuracy

of motion from the CT scanner gantry, the accelerator couch and the coincidence of the CT and linear accelerator isocentres need to be verified.

The concept of cone beam CT for image guided radiotherapy was introduced in 1997 [II–8]. Cone beam CT refers to combined kV X ray imaging and MV radiation delivery into one integrated gantry mounted system. Advancements in large area flat panel detector technology facilitated volumetric imaging to be acquired in a single rotation of the linear accelerator gantry. Planar kV image projections are obtained as the gantry rotates about the patient on the linear accelerator table, from 30 s to 4 min. Cone beam CT 3-D volume reconstruction images may then be obtained for image guidance. In addition to providing volumetric imaging for verification and guidance, these systems have the ability to be used for real time kV tracking; the latter application has not been used clinically.

CT imaging using MV beams has also been used for IGRT [II–9 to II–12]. The advantages of MV cone beam CT are that the treatment MV beam is used to obtain the image, requiring less modification to the linear accelerator, the electron density estimates for treatment planning are accurate and there is no high Z artifact that is associated with kV imaging.

MV tomotherapy combines tomographic scanning capabilities, from a conventional CT detector, with a linear accelerator mounted on a rotating gantry. In the tomotherapy treatment platform, the MV treatment beam is used to obtain images, with a lower energy (3.5 MV instead of 6 MV).

REFERENCES TO ANNEX II

- [II–1] SONKE, J.J., et al., Respiratory correlated cone beam CT, *Med. Phys.* **32** (2005) 1176–1186.
- [II–2] BALTER, J.M., et al., Improvement of CT-based treatment planning models of abdominal targets using static exhale imaging, *Int. J. Radiat. Oncol. Biol. Phys.* **41** (1998) 939–943.
- [II–3] BOOTH, J.T., ZAVGORODNI, S.F., Set-up error & organ motion uncertainty: A review, *Australas. Phys. Eng. Sci. Med.* **22** (1999) 29–47.
- [II–4] SHIRATO, H., et al., Four-dimensional treatment planning and fluoroscopic real-time tumor tracking radiotherapy for moving tumor, *Int. J. Radiat. Oncol. Biol. Phys.* **48** (2000) 435–442.
- [II–5] DAWSON, L.A., et al., Accuracy of daily image guidance for hypofractionated liver radiotherapy with active breathing control, *Int. J. Radiat. Oncol. Biol. Phys.* **62** (2005) 1247–1252.
- [II–6] BALTER, J.M., et al., Daily targeting of intrahepatic tumors for radiotherapy, *Int. J. Radiat. Oncol. Biol. Phys.* **52** (2002) 266–271.

- [II-7] FUSS, M., et al., Daily ultrasound-based image-guided targeting for radiotherapy of upper abdominal malignancies, *Int. J. Radiat. Oncol. Biol. Phys.* **59** (2004) 1245–1256.
- [II-8] JAFFRAY, D.A., et al., A radiographic and tomographic imaging system integrated into a medical linear accelerator for localization of bone and soft-tissue targets, *Int. J. Radiat. Oncol. Biol. Phys.* **45** (1999) 773–789.
- [II-9] SIMPSON, R.G., et al., A 4-MV CT scanner for radiation therapy: The prototype system, *Med. Phys.* **9** (1982) 574–579.
- [II-10] SWINDELL, W., et al., Computed tomography with a linear accelerator with radiotherapy applications, *Med. Phys.* **10** (1983) 416–420.
- [II-11] MACKIE, T.R., et al., Tomotherapy: a new concept for the delivery of dynamic conformal radiotherapy, *Med. Phys.* **20** (1993) 1709–1719.
- [II-12] MACKIE, T.R., et al., Image guidance for precise conformal radiotherapy, linear accelerator for localization of bone and soft-tissue targets, *Int. J. Radiat. Oncol. Biol. Phys.* **56** (2003) 89–105.

ABBREVIATIONS

3-D	Three dimensional
AASLD	American Association for the Study of Liver Disease
AFP	Alpha fetoprotein
BCLC	Barcelona Clinic Liver Cancer
CGH	Comparative genomic hybridization
CLIP	Cancer of the Liver Italian Program
CT	Computed tomography
CTV	Clinical target volume
DCP	Desgamma-carboxyprothrombin
DNA	Deoxyribonucleic acid
Gy	Gray
GyE	Gray equivalent
HCV	Hepatitis C virus
HBV	Hepatitis B virus
HCC	Hepatocellular carcinoma
HCC-CC	Hepatocellular-cholangiocarcinoma
IGRT	Image guided radiation therapy
JIS	Japan integrated staging
KLCSG	Korean Liver Cancer Study Group
MDTNL	Mean dose to normal liver
MELD	Model for end stage liver disease
MRI	Magnetic resonance imaging
NCCN	National Comprehensive Cancer Network
OLT	Orthotopic liver transplantation
PEI	Percutaneous ethanol injection
PLC	Primary liver cancer
PTV	Planning target volume
RCT	Randomized clinical trial
RILD	Radiation induced liver disease
RFA	Radiofrequency ablation
SBRT	Stereotactic body radiation therapy
TACE	Transarterial chemoembolization
TCP	Tumour control probability
UICC	Union internationale contre le cancer
US	Ultrasound

CONTRIBUTORS TO DRAFTING AND REVIEW

Alaa, I.	Ain Shams University, Egypt
Dawson, L.	Princess Margaret Hospital, Canada
Imai, R.	International Atomic Energy Agency
Krishnan, S.	M.D. Anderson Cancer Center, United States of America
Ng, I.	The University of Hong Kong, China
Salminen, E.	International Atomic Energy Agency
Seong, J.	Yonsei University, Republic of Korea
Stevens, G.	Auckland Hospital, New Zealand



IAEA

International Atomic Energy Agency

No. 22

Where to order IAEA publications

In the following countries IAEA publications may be purchased from the sources listed below, or from major local booksellers. Payment may be made in local currency or with UNESCO coupons.

AUSTRALIA

DA Information Services, 648 Whitehorse Road, MITCHAM 3132
Telephone: +61 3 9210 7777 • Fax: +61 3 9210 7788
Email: service@dadirect.com.au • Web site: <http://www.dadirect.com.au>

BELGIUM

Jean de Lannoy, avenue du Roi 202, B-1190 Brussels
Telephone: +32 2 538 43 08 • Fax: +32 2 538 08 41
Email: jean.de.lannoy@infoboard.be • Web site: <http://www.jean-de-lannoy.be>

CANADA

Bernan Associates, 4501 Forbes Blvd, Suite 200, Lanham, MD 20706-4346, USA
Telephone: 1-800-865-3457 • Fax: 1-800-865-3450
Email: customer@bernans.com • Web site: <http://www.bernans.com>

Renouf Publishing Company Ltd., 1-5369 Canotek Rd., Ottawa, Ontario, K1J 9J3
Telephone: +613 745 2665 • Fax: +613 745 7660
Email: order.dept@renoufbooks.com • Web site: <http://www.renoufbooks.com>

CHINA

IAEA Publications in Chinese: China Nuclear Energy Industry Corporation, Translation Section, P.O. Box 2103, Beijing

CZECH REPUBLIC

Suweco CZ, S.R.O., Klecakova 347, 180 21 Praha 9
Telephone: +420 26603 5364 • Fax: +420 28482 1646
Email: nakup@suweco.cz • Web site: <http://www.suweco.cz>

FINLAND

Akateeminen Kirjakauppa, PO BOX 128 (Keskuskatu 1), FIN-00101 Helsinki
Telephone: +358 9 121 41 • Fax: +358 9 121 4450
Email: akatilaus@akateeminen.com • Web site: <http://www.akateeminen.com>

FRANCE

Form-Edit, 5, rue Janssen, P.O. Box 25, F-75921 Paris Cedex 19
Telephone: +33 1 42 01 49 49 • Fax: +33 1 42 01 90 90
Email: formedit@formedit.fr • Web site: <http://www.formedit.fr>

Lavoisier SAS, 145 rue de Provigny, 94236 Cachan Cedex
Telephone: + 33 1 47 40 67 02 • Fax +33 1 47 40 67 02
Email: romuald.verrier@lavoisier.fr • Web site: <http://www.lavoisier.fr>

GERMANY

UNO-Verlag, Vertriebs- und Verlags GmbH, Am Hofgarten 10, D-53113 Bonn
Telephone: + 49 228 94 90 20 • Fax: +49 228 94 90 20 or +49 228 94 90 222
Email: bestellung@uno-verlag.de • Web site: <http://www.uno-verlag.de>

HUNGARY

Librotrade Ltd., Book Import, P.O. Box 126, H-1656 Budapest
Telephone: +36 1 257 7777 • Fax: +36 1 257 7472 • Email: books@librotrade.hu

INDIA

Allied Publishers Group, 1st Floor, Dubash House, 15, J. N. Heredia Marg, Ballard Estate, Mumbai 400 001,
Telephone: +91 22 22617926/27 • Fax: +91 22 22617928
Email: alliedpl@vsnl.com • Web site: <http://www.alliedpublishers.com>

Bookwell, 2/72, Nirankari Colony, Delhi 110009
Telephone: +91 11 23268786, +91 11 23257264 • Fax: +91 11 23281315
Email: bookwell@vsnl.net

ITALY

Libreria Scientifica Dott. Lucio di Biasio "AEIOU", Via Coronelli 6, I-20146 Milan
Telephone: +39 02 48 95 45 52 or 48 95 45 62 • Fax: +39 02 48 95 45 48
Email: info@libreriaaeiou.eu • Website: www.libreriaaeiou.eu

JAPAN

Maruzen Company, Ltd., 13-6 Nihonbashi, 3 chome, Chuo-ku, Tokyo 103-0027
Telephone: +81 3 3275 8582 • Fax: +81 3 3275 9072
Email: journal@maruzen.co.jp • Web site: <http://www.maruzen.co.jp>

REPUBLIC OF KOREA

KINS Inc., Information Business Dept. Samho Bldg. 2nd Floor, 275-1 Yang Jae-dong SeoCho-G, Seoul 137-130
Telephone: +02 589 1740 • Fax: +02 589 1746 • Web site: <http://www.kins.re.kr>

NETHERLANDS

De Lindeboom Internationale Publicaties B.V., M.A. de Ruyterstraat 20A, NL-7482 BZ Haaksbergen
Telephone: +31 (0) 53 5740004 • Fax: +31 (0) 53 5729296
Email: books@delindeboom.com • Web site: <http://www.delindeboom.com>

Martinus Nijhoff International, Koraalrood 50, P.O. Box 1853, 2700 CZ Zoetermeer
Telephone: +31 793 684 400 • Fax: +31 793 615 698
Email: info@nijhoff.nl • Web site: <http://www.nijhoff.nl>

Swets and Zeitlinger b.v., P.O. Box 830, 2160 SZ Lisse
Telephone: +31 252 435 111 • Fax: +31 252 415 888
Email: infoho@swets.nl • Web site: <http://www.swets.nl>

NEW ZEALAND

DA Information Services, 648 Whitehorse Road, MITCHAM 3132, Australia
Telephone: +61 3 9210 7777 • Fax: +61 3 9210 7788
Email: service@dadirect.com.au • Web site: <http://www.dadirect.com.au>

SLOVENIA

Cankarjeva Založba d.d., Kopitarjeva 2, SI-1512 Ljubljana
Telephone: +386 1 432 31 44 • Fax: +386 1 230 14 35
Email: import.books@cankarjeva-z.si • Web site: <http://www.cankarjeva-z.si/uvoz>

SPAIN

Diaz de Santos, S.A., c/ Juan Bravo, 3A, E-28006 Madrid
Telephone: +34 91 781 94 80 • Fax: +34 91 575 55 63
Email: compras@diazdesantos.es, carmela@diazdesantos.es, barcelona@diazdesantos.es, julio@diazdesantos.es
Web site: <http://www.diazdesantos.es>

UNITED KINGDOM

The Stationery Office Ltd, International Sales Agency, PO Box 29, Norwich, NR3 1 GN
Telephone (orders): +44 870 600 5552 • (enquiries): +44 207 873 8372 • Fax: +44 207 873 8203
Email (orders): book.orders@tso.co.uk • (enquiries): book.enquiries@tso.co.uk • Web site: <http://www.tso.co.uk>

On-line orders

DELTA Int. Book Wholesalers Ltd., 39 Alexandra Road, Addlestone, Surrey, KT15 2PQ
Email: info@profbooks.com • Web site: <http://www.profbooks.com>

Books on the Environment

Earthprint Ltd., P.O. Box 119, Stevenage SG1 4TP
Telephone: +44 1438748111 • Fax: +44 1438748844
Email: orders@earthprint.com • Web site: <http://www.earthprint.com>

UNITED NATIONS

Dept. I004, Room DC2-0853, First Avenue at 46th Street, New York, N.Y. 10017, USA
(UN) Telephone: +800 253-9646 or +212 963-8302 • Fax: +212 963-3489
Email: publications@un.org • Web site: <http://www.un.org>

UNITED STATES OF AMERICA

Bernan Associates, 4501 Forbes Blvd., Suite 200, Lanham, MD 20706-4346
Telephone: 1-800-865-3457 • Fax: 1-800-865-3450
Email: customercare@bernan.com • Web site: <http://www.bernan.com>

Renouf Publishing Company Ltd., 812 Proctor Ave., Ogdensburg, NY, 13669
Telephone: +888 551 7470 (toll-free) • Fax: +888 568 8546 (toll-free)
Email: order.dept@renoufbooks.com • Web site: <http://www.renoufbooks.com>

Orders and requests for information may also be addressed directly to:

Marketing and Sales Unit, International Atomic Energy Agency

Vienna International Centre, PO Box 100, 1400 Vienna, Austria
Telephone: +43 1 2600 22529 (or 22530) • Fax: +43 1 2600 29302
Email: sales.publications@iaea.org • Web site: <http://www.iaea.org/books>

Hepatocellular carcinoma, or primary liver cancer, is one of the most common causes of cancer and cancer death globally, and has an increasing incidence. It is currently the fifth most common cancer among men and eighth among women. In some Asian and African countries, its incidence is similar to that of lung cancer. It carries a very poor prognosis; the majority of patients die within a year, making it the third most common cause of cancer death. This review is intended for use in training courses and as a source of information on treatment decisions. It may also help guide the use of limited resources towards the most appropriate indications and help to differentiate approaches used for cure or palliation.

IAEA HUMAN HEALTH SERIES

INTERNATIONAL ATOMIC ENERGY AGENCY
VIENNA
ISBN 978-92-0-102710-8
ISSN 2075-3772